AJNR

CT evaluation of perineural orbital lesions: evaluation of the "tram-track" sign.

T T Johns, C M Citrin, J Black and J L Sherman

AJNR Am J Neuroradiol 1984, 5 (5) 587-590
http://www.ajnr.org/content/5/5/587

CT Evaluation of Perineural Orbital Lesions: Evaluation of the "Tram-Track" Sign

T. Todd Johns[1]
Charles M. Citrin[2]
Jeffrey Black[1,3]
John L. Sherman[1,3]

Cranial computed tomographic scans of 225 patients with orbital mass lesions were reviewed. In 11 patients, the optic nerve was seen as a linear defect through the orbital mass. These 11 cases comprised three optic nerve sheath meningiomas, three hemangiomas, two cases of pseudotumor, and one case each of Erdheim-Chester disease, optic neuritis, and metastatic disease. Optic nerve sheath meningiomas could be further differentiated from the other mass lesions by showing the entire length of the optic nerve through the lesion, smooth margins, a fusiform shape, and parallel enhancement of the periphery of the optic nerve even greater than that of the surrounding mass. These features may aid in differentiating optic nerve sheath meningiomas from other mass lesions in the orbit.

Several recent articles have discussed the computed tomographic (CT) evaluation of optic sheath meningiomas and other orbital lesions. Visualization of the optic nerve as a "negative defect" in relation to the surrounding mass lesion has been described as the "tram-track" sign for identifying optic sheath meningiomas [1]. We have investigated a number of patients who demonstrated this tram-track sign and found it to be a nonspecific finding. However, this finding in conjunction with an area of increased attenuation in the immediate perineural region is specific for optic nerve sheath meningioma. We also present the CT findings in several patients with orbital lesions in which the optic nerve was seen as a line of decreased density extending through the retrobulbar mass. Enhancement of the periphery of an optic nerve which is not enlarged may be a normal finding and probably represents normal dural enhancement.

Materials and Methods

We reviewed the cranial CT scans of 225 patients with retrobulbar masses. The masses were categorized as to their margins (smooth, poorly defined), perineural distribution (symmetric, asymmetric), shape (fusiform, cylindrical, round, or diffusely infiltrative), and degree of contrast enhancement. Particular attention was paid to the optic nerve to determine whether it could be identified as a structure of lower attenuation distinct from the surrounding retrobulbar lesion; 11 patients had this feature. The length of the lower-attenuation optic nerve (partial or total) and the type of enhancement of the mass surrounding it were also noted. Other characteristics evaluated were the degree of exophthalmos, flattening of the globe, scleral thickening, bony canal erosion, intracranial extension, and bony hyperostosis.

CT was performed on second-, third-, and fourth-generation scanners. Scans were obtained in both transaxial and coronal planes. In most cases, the slice thickness was 1.5–5.0 mm, and most scans were performed after intravenous administration of contrast material.

Results

There were three surgically proven optic nerve sheath meningiomas; three surgically proven hemangiomas; two orbital pseudotumors, which were not sur-

Received July 25, 1983; accepted after revision February 27, 1984.

The opinions or assertions contained herein are the private views of the authors and are not to be construed as official or as reflecting the views of the Department of the Army or the Department of Defense.

[1] Department of Radiology, Walter Reed Army Medical Center, Washington, DC 20307. Address reprint requests to T. T. Johns.

[2] The Neurology Center, Chevy Chase, MD 20815, and Department of Radiology, George Washington University Hospital, Washington, DC 20037.

[3] Department of Radiology and Nuclear Medicine, Uniformed Services University of the Health Sciences, Bethesda, MD 20814.

AJNR 5:587–590, September/October 1984
0195–6108/84/0505–0587

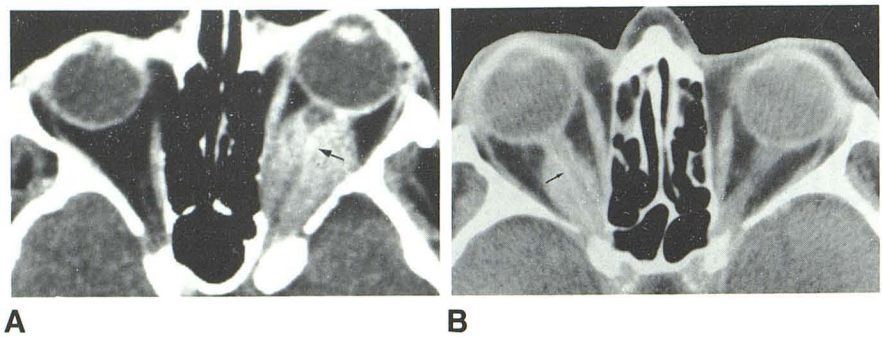

Fig. 1.—**A** and **B**, Two cases of optic nerve sheath meningioma. Optic nerve is seen as negative defect extending through fusiform mass. Perineural hyperdensity (*arrows*) in each case.

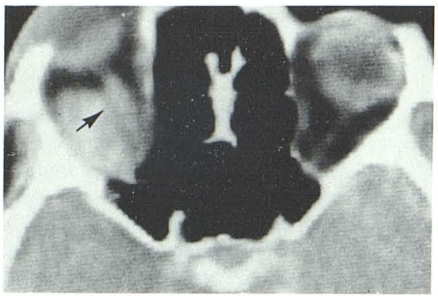

Fig. 2.—Retrobulbar cavernous hemangioma. Optic nerve (*arrow*) is seen as line of decreased density along its entire course. No perineural enhancement.

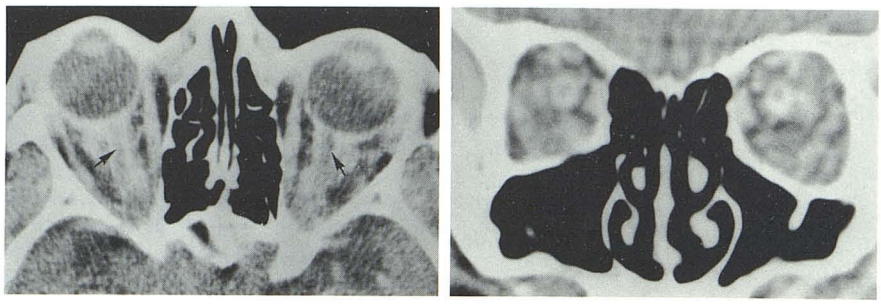

Fig. 3.—Bilateral orbital pseudotumor, axial (**A**) and coronal (**B**) views. Optic nerve (*arrows*) is seen as negative defect surrounded by inflammatory mass. Scleral thickening.

gically proven but were followed to resolution with CT after steroid therapy; and one case each of Erdheim-Chester disease (autopsy-proven), optic neuritis (proven by cerebrospinal fluid analysis), and metastatic prostate disease (surgically proven). All these lesions showed the optic nerve as a negative defect, either in part or along the entire length of the optic nerve, surrounded by the retrobulbar mass.

All the optic nerve sheath meningiomas had smooth margins and were fusiform. They also showed linear enhancement immediately adjacent to the optic nerve even greater than that of the surrounding mass. This is not to be confused with the small degree of optic nerve dural enhancement normally seen after infusion of contrast medium. The optic nerve was seen as a negative defect along its entire course in all the optic nerve sheath meningiomas (fig. 1). Scleral thickening was not seen in any of the meningiomas, nor was there bony canal erosion or bony hyperostosis. One optic nerve sheath meningioma caused flattening of the globe posteriorly, and papilledema was observed.

All three cavernous hemangiomas had smooth margins and a rounded shape. Two showed a partial linear negative defect related to the optic nerve, whereas the third showed a negative defect along the entire length of the optic nerve (fig. 2).

Both pseudotumors were seen as a diffusely infiltrative retrobulbar mass. One showed the optic nerve as a negative defect along its entire length. Both pseudotumors showed scleral thickening (fig. 3).

The case of Erdheim-Chester disease (fig. 4), the metastatic prostate lesion (fig. 5), and the case of optic neuritis all showed the intraorbital optic nerve along its entire course as a line of decreased density in relation to the surrounding mass. Intracranial extension was seen in the case of the metastatic lesion. None of the masses in our series showed bony canal erosion or bony hyperostosis.

Discussion

The medical literature is replete with studies of orbital mass lesions and diseases involving the optic nerve [2–13]. A recent study by Daniels et al. [14] showed a feature helpful for distinguishing an optic glioma from an optic nerve sheath meningioma. After contrast material is administered in a patient with an optic nerve sheath meningioma, the tumor sheath is seen as an increased density in comparison with the optic nerve. Optic gliomas, on the other hand, usually present with a uniform density of both sheath and tumor. Swenson et al. [15] reported four cases of peripheral enhancement of a thickened nerve sheath by optic nerve meningiomas. Peyster et al. [1] recently described the normal optic nerve running through an optic sheath meningioma as presenting a "tram-track" appearance: namely, that of a low-density nerve surrounded by a tumor of increased density on axial views.

We present three additional cases of optic nerve sheath meningioma showing the optic nerve as a negative defect through the retrobulbar mass. In addition, a new finding was observed in all three optic nerve sheath meningiomas: After infusion of contrast medium, parallel linear enhancement even greater than the enhancement of the remainder of the mass

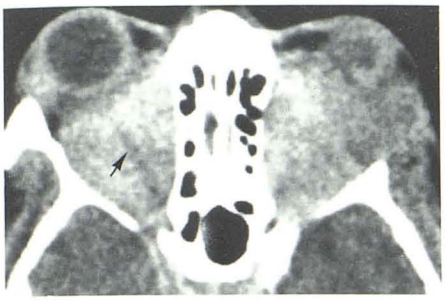

Fig. 4.—Erdheim-Chester disease. Gross exophthalmos with diffusely infiltrative retrobulbar mass. Optic nerve is seen in its entire course as line of decreased density (*arrow*).

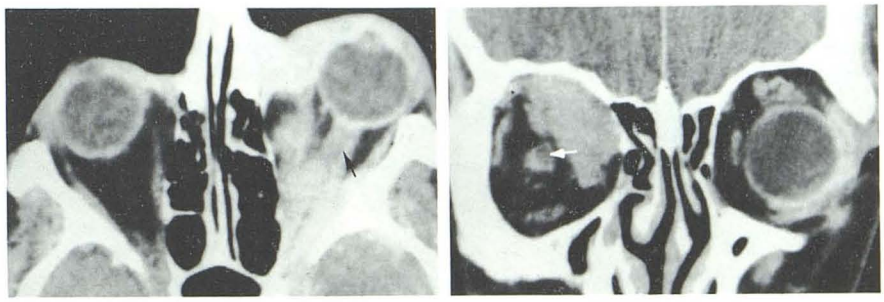

A B

Fig. 5.—Metastatic prostate disease to left orbit. Axial view (**A**) shows optic nerve (*arrow*) extending through mass. No perineural hyperdensity. Coronal view (**B**) shows optic nerve (*arrow*) as area of decreased density in comparison with surrounding lesion. (Case courtesy of Dr. Dieter Schellinger.)

was seen immediately adjacent to the optic nerve. Three distinct densities were observed: (1) the low-density optic nerve, (2) the denser meningiomatous tumor mass, and (3) the even more dense, parallel linear enhancing areas adjacent to the optic nerve.

We hypothesize that the additional enhancement immediately adjacent to the optic nerve in the three cases of optic nerve sheath meningioma is related to linear spread of the tumor along the subarachnoid space, once the tumor has extended from its original location in the subdural space [16]. Other masses in the retrobulbar region do not exhibit this type of perineural spread and therefore would not create such a striking contrast between the tumor mass and the optic nerve immediately adjacent to it.

Our three cases of optic nerve sheath meningioma all showed smooth margins and a fusiform shape, and the optic nerve was seen as a negative defect extending through the entire length of the tumor mass. We believe that these features seen in conjunction with enhancement immediately adjacent to the optic nerve and greater than that of the rest of the mass are diagnostic of an optic nerve sheath meningioma. Optic nerve meningiomas normally arise in the subdural space. Invasion of the subarachnoid space is the probable etiology of this finding.

In evaluating retrobulbar masses, we noted various other lesions in which the optic nerve was seen as a line of decreased density, either in part or in its entirety, extending through the retrobulbar mass.

Three cases of cavernous hemangioma were all characterized by a smooth-margined, rounded mass in the retrobulbar region. The finding of a rounded lesion is helpful for differentiating a hemangioma from an optic nerve sheath meningioma. Two of the masses showed homogeneous enhancement after administration of contrast medium, and the other hemangioma was seen as a mottled area of increased density. Contrast enhancement is to be expected, since hemangiomas are the result of proliferation of capillary tissue with gradual dilatation over an extended period [17]. They typically present, as did our three cases, as well defined retrobulbar lesions. The optic nerve was seen as a negative defect along a portion of its course in two cases and along its entire length in the other hemangioma. No enhancement immediately adjacent to the optic nerve was seen in any of our hemangiomas.

Two cases of orbital pseudotumor showed a diffuse retrobulbar mass, both of which enhanced with intravenous contrast administration. Orbital pseudotumor presents as a mass lesion within the orbit and may vary in size, shape, and location [18]. The mass lesion may surround the globe partly or completely, or may adhere to the globe. It may also obliterate the normal retrobulbar structures, as was demonstrated in our two cases. Both our cases of pseudotumor also showed scleral thickening. This phenomenon has also been described by Bernardino et al. [19]. The optic nerve was seen as a negative defect along its entire length in one pseudotumor and along part of its length in the other pseudotumor. Another distinguishing feature of pseudotumor is that of increased density of the retrobulbar fat due to edema and inflammatory reaction [20].

An unusual case of Erdheim-Chester disease (histiocytic lipidosis) involving the retrobulbar region was evaluated. Gross exophthalmos was demonstrated bilaterally with poorly defined margins and a diffusely infiltrative pattern. The optic nerve was visualized as a negative defect along its entire course through the mass. Enhancement of the mass was noted as well as flattening of the posterior part of the globe. Perineural enhancement was not observed.

A case of optic neuritis demonstated a smoothly thickened sheath surrounding the optic nerve. The optic nerve was seen as a negative defect along part of its course in both orbits.

One case of metastatic disease of the prostate to the orbit showed a smooth, cylindrical mass in the retrobulbar region, with the entire length of the optic nerve again seen as a line of decreased density through the mass lesion. Intracranial extension was demonstrated. Metastatic disease to the orbit is not uncommon, occurring in 3%–7% of patients with unilateral exophthalmos [20]. Moreover, these figures may be too low because most studies are based on pathology data alone. In a study by Hesselink et al. [21], the globe, retrobulbar soft tissue, and orbit accounted for most sites of metastasis to the orbit. Only one of 34 cases involved the optic nerve. Our case is unusual in that the optic nerve was involved, again appearing as a negative defect through the mass.

In our experience, CT is extremely valuable in evaluating retrobulbar lesions. We believe optic nerve sheath meningiomas have certain features on CT that are virtually diagnostic. These findings include a fusiform mass with smooth margins, demonstration of the optic nerve as a negative defect along its entire intraorbital course, and parallel linear enhancement

adjacent to the optic nerve and greater than that of the rest of the mass. Several other retrobulbar lesions show the optic nerve as a line of decreased density along either a part or the entire length of its intraorbital course. This finding in itself is not specific for any one lesion.

REFERENCES

1. Peyster RG, Hoover ED, Hershey BL, Haskin ME. High-resolution CT of lesions of the optic nerve. *AJNR* **1983**;4:169–174, *AJR* **1983**;140:869–874
2. Ellenberger C. Perioptic meningiomas. *Arch Neurol* **1976**; 33:671–674
3. Byrd S, Harwood-Nash DC, Fitz C, Barry J, Rogovitz D. Computed tomography of intraorbital optic nerve gliomas in children. *Radiology* **1978**;129:73–78
4. Henderson J, Campbell RJ. Primary intraorbital meningioma with intraocular extension. *Mayo Clin Proc* **1977**;52:504–508
5. Howard C, Osher R, Tonsak R. Computed tomographic features in optic neuritis. *Am J Ophthalmol* **1980**;89:699–702
6. Forbes G. Computed tomography of the orbit. *Radiol Clin North Am* **1982**;20:37–49
7. Hart W, Burde R, Klingele T, Perlmutter J. Bilateral optic nerve sheath meningiomas. *Arch Ophthalmol* **1980**;98:149–151
8. Forbes G, Earnest F, Waller R. Computed tomography of orbital tumors, including late-generation scanning techniques. *Radiology* **1982**;142:387–394
9. Harr D, Quencer R, Abrams G. Computed tomography and ultrasound in the evaluation of orbital infection and pseudotumor. *Radiology* **1982**;142:395–401
10. Alker G, Banna M, Rudin S, Oh Y. Computed tomography of the orbit. *CRC Crit Rev Diagn Imaging* **1981**;15:27–93
11. Lloyd G. CT scanning in the diagnosis of orbital disease. *Comput Tomogr* **1979**;3:227–239
12. Tranier-Guibert F, Piton J, Calabet A, Caille JM. Orbital syndromes—CT analysis of 100 cases. *Comput Tomogr* **1979**; 3:241–265
13. Forbes G, Sheedy P, Waller R. Orbital tumors evaluated by computed tomography. *Radiology* **1980**;136:101–111
14. Daniels DL, Williams AL, Syvertsen A, Gager WE, Harris GJ. CT recognition of optic nerve sheath meningioma: abnormal sheath visualization. *AJNR* **1982**;3:181–183
15. Swenson SA, Forbes GS, Younge BR, Campbell RJ. Radiologic evaluation of tumors of the optic nerve. *AJNR* **1982**;3:319–326
16. Alper M. Management of primary optic nerve meningiomas. *J Clin Neuro Ophthalmol* **1981**;1:101–117
17. Harris G, Jakobiec F. Cavernous hemangiomas of the orbit. *J Neurosurg* **1979**;51:219–228
18. Enzmann D, Donaldson S, Marshall W, Kriss J. Computed tomography in orbital pseudotumor. *Radiology* **1976**;120:597–601
19. Bernardino ME, Zimmerman RD, Citrin CM, Davis DO. Scleral thickening: a CT sign of orbital pseudotumor. *AJR* **1977**; 129:703–706
20. Milal SK, Trokel SL. Computerized tomography of the orbit using thin sections. *Semin Roentgenol* **1977**;12:137–147
21. Hesselink J, Davis K, Weber A, Davis J, Taveras J. Radiological evaluation of orbital metastases, with emphasis on computed tomography. *Radiology* **1980**;137:363–366