

Are your **MRI contrast agents** cost-effective?

Learn more about generic **Gadolinium-Based Contrast Agents**.



FRESENIUS
KABI

caring for life

AJNR

Sinus pericranii with dural venous lakes.

G J Beers, A P Carter, J I Ordia and M Shapiro

AJNR Am J Neuroradiol 1984, 5 (5) 629-631

<http://www.ajnr.org/content/5/5/629.citation>

This information is current as
of April 20, 2024.

Sinus Pericranii with Dural Venous Lakes

G. Jerome Beers,¹ Anthony P. Carter,¹ Joe Idahosa Ordia,² and Mark Shapiro³

Cavernous hemangiomas involving the dura are relatively uncommon lesions. We report a case of a cavernous hemangioma with features of sinus pericranii with venous lakes that involved the dura as well as calvarium. Associated with it were radiologic bone changes atypical for hemangioma. In presenting our case, we correlate the computed tomographic (CT) appearance with surgical and conventional radiographic findings.

Case Report

A 15½-year-old girl was admitted to Boston City Hospital for evaluation of a fluctuant left frontal scalp mass. First noted about 2 years before, apparently it had not changed. Of more recent onset were sporadic headaches, which tended to follow exercise and were aggravated by bending forward. Medical history was remarkable only for a linear occipital fracture 13 years before and for surgery for a clubfoot.

On examination in the recumbent position there was a slightly tender, nonpulsatile, fluctuant mass 4 cm in diameter and about 0.5 cm in height in the left frontal region just anterior to the coronal suture and extending just to the midline. In the upright position the mass reduced itself spontaneously, and the calvarium felt irregular. There was no bruit.

Skull films showed a poorly defined area of sclerotic bone to the left of the midline immediately anterior to the coronal suture with slightly prominent vascular channels nearby. A soft-tissue tangential radiograph showed a soft-tissue density overlying the bony abnormality. CT showed poorly defined focal expansion of the involved part of the left frontal bone with irregular areas of increased and decreased density with poor definition of the inner and outer tables. There was one sharply defined zone of diminished density about 2 mm wide at least partly marginated by sclerotic bone, which appeared to extend from the inner surface of the calvarium to the outer surface (fig. 1A). Immediately overlying the bony abnormality was a well defined, enhancing soft-tissue mass (fig. 1B); directly underlying it was lobulated soft-tissue density (fig. 1C).

Selective external carotid angiography demonstrated filling of vascular lakes at the site of the osseous abnormality (fig. 1D). These lakes were largely fed by branches of the external carotid artery. There was also some filling of these lakes from the internal carotid artery (fig. 1E), presumably from the artery of the falx. These venous structures were slow to drain, still containing contrast material about 15 sec after injection.

At surgery large cavernous veins corresponding to the extracranial mass on CT were encountered between the pericranium and the outer table of the skull. The outer table of the skull was irregular. There was a 3 × 5 mm hole through the calvarium, which was thought to correlate with the zone of the diminished density seen traversing the calvarium in figure 1A. A vein traversed this hole. Underlying the calvarium within the dura a large venous lake was resected after a connection between it and the superior sagittal sinus was resected. The sinus itself appeared normal at surgery. The bone flap was removed because the bone appeared abnormal, grossly as well as radiographically. An acrylic cranioplasty was performed. The patient recovered promptly after surgery and remained symptom-free.

Tissue both from the dura and from between the pericranium and the outer table had the histologic appearance of cavernous hemangioma. Both tissues consisted primarily of thin-walled vascular channels separated by dense fibrous tissue. A few vessels, having smooth muscle and well defined elastic laminae in their walls, had the appearance of arteries. There were hemosiderin-filled macrophages in many areas. The tissue from just beneath the pericranium contained some organized clots with proliferation of connective tissue. Histologically the bone flap appeared normal.

Discussion

Cavernous hemangiomas, vascular tumors composed of dilated capillaries [1], are relatively uncommon in the head [2]. Voigt and Yasargil [3], in reviewing their own case and previous reports, found 164 cases involving the brain. Hemangiomas of the calvarium, although well known, have been termed "rare" [4, 5] and have not been extensively described in the CT literature. Cavernous hemangiomas involving the dura seem rather less common. Kawai et al. [6] and McCormick and Boulter [7] each described two cases of dural or other intracranial extracerebral cavernous hemangiomas, and Kawai et al. cited several other probable cases from the Japanese and German literature. Pasztor et al. [8] reported a case involving the face and the base of the skull. Encapsulated by the dura, the lesion filled the middle fossa. Kessler et al. [5] had a case of cavernous hemangioma that had destroyed the petrous part of the temporal bone and had ruptured, giving rise to an epidural hematoma.

Sinus pericranii refers to a pooling of blood in the scalp communicating through the calvarium with the superior sag-

Received February 25, 1983; accepted after revision November 10, 1983

¹ Department of Radiology, Boston University Medical Center, and Boston City Hospital, 818 Harrison Ave., Boston, MA 02118. Address reprint requests to G. J. Beers.

² Department of Neurosurgery, Boston University Medical Center, Boston City Hospital, Boston, MA 02118.

³ Department of Pediatric Neurology, Boston University Medical Center, Boston City Hospital, Boston, MA 02118.

AJNR 5:629-631, September/October 1984 0195-6108/84/0505-0629 \$00.00 © American Roentgen Ray Society

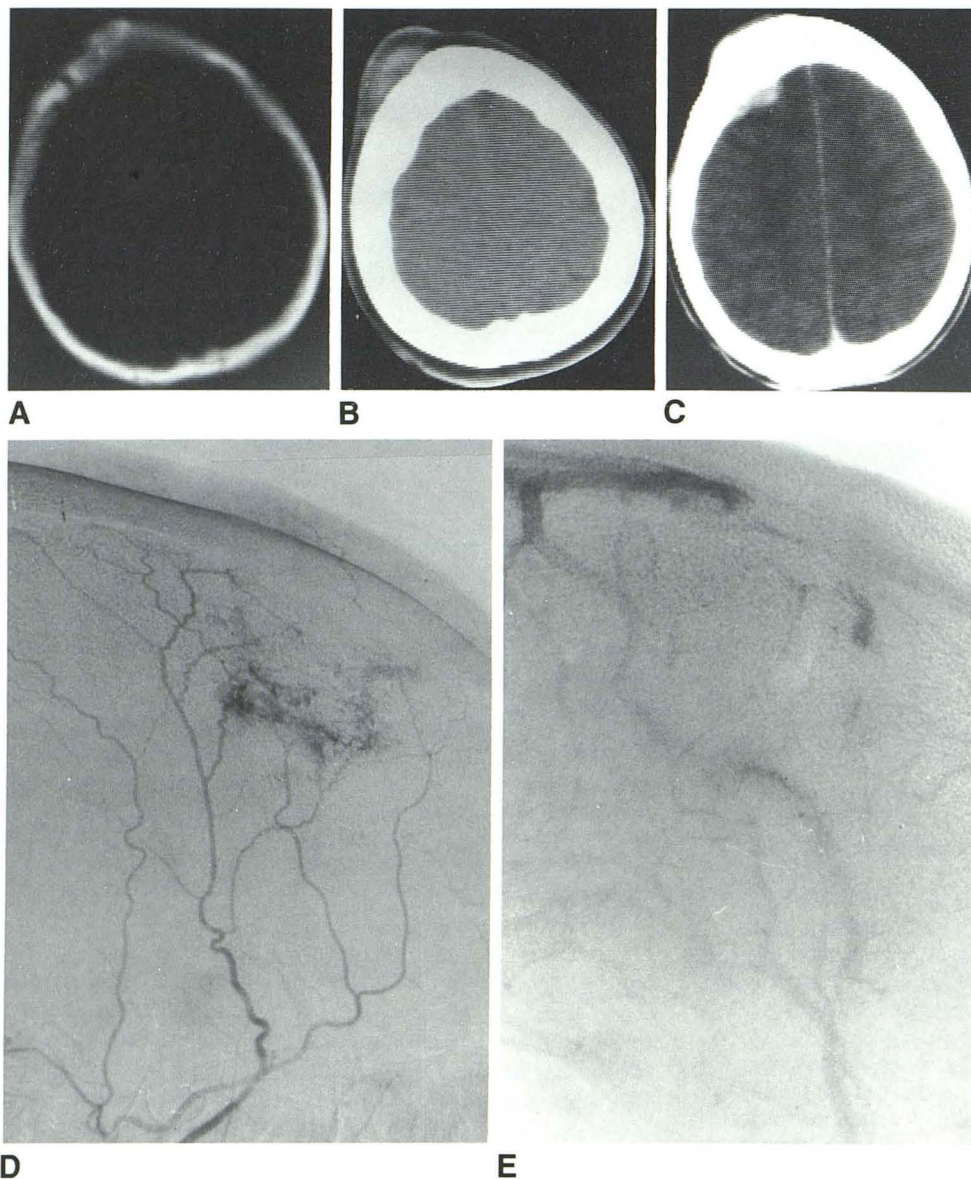


Fig. 1.—A, CT at bone window setting demonstrates irregular sclerosis of left frontal bone. Poor definition of inner and outer tables. Tubular zone of diminished density consistent with channel in bone traverses perpendicularly across calvarium. B, CT with soft-tissue window setting shows well defined enhancing mass outside calvarium. C, CT shows enhancing lobulated soft-tissue density underneath calvarium. D, Lateral radiograph after injection of external carotid artery shows filling of left frontal region vascular mass by meningeal and temporal branches of external carotid artery. E, Lateral film from venous phase after injection of left internal carotid artery shows filling of small part of venous lake that filled during external carotid angiogram.

ittal sinus or a lateral sinus. The sinus pericranii is a bluish, fluctuant lesion that enlarges when the patient's head is dependent [9–16]. A sinus pericranii may or may not opacify on carotid angiography and, therefore, may need to be directly injected with contrast material [10, 12, 14]. Cases have been reported in which hemangiomas elsewhere on the head have coexisted with a sinus pericranii [11, 14]. Although some authors have thought that at least some cases are traumatic in origin [9, 10, 14], Poppel et al. [11] consider sinus pericranii to be a subtype of cavernous hemangioma that involves the pericranium.

Taveras and Wood [17] described an arteriovenous angioma of the scalp that differed from typical sinus pericranii only in that there was a small, radiographically apparent arterial component to the lesion [17]. Our case, while histologically having the main features of cavernous hemangioma,

did vary from the typical [1] lesion in that a few arterial structures were visible histologically. Probably one should not consider sinuses pericranii, hemangiomas, and arteriovenous angiomas to be distinct lesions but rather entities that can overlap. Our case, for example, histologically a cavernous hemangioma, had a presentation like that of sinus pericranii, but had dural lakes, which are not typical of sinus pericranii.

On skull films sinuses pericranii typically are associated with areas of rarefaction or perforation [14, 16]. In one case there was an area of apparent complete absence of bone surrounded by a margin of diploic thickening [16]. In some cases no osseous changes are apparent [10, 14]. Our case demonstrates a poorly defined region of calvarial thickening with loss of definition of inner and outer tables on CT and poorly defined sclerosis on plain films. This appearance would be consistent with fibrous dysplasia or even a malignant bone

tumor. Of interest is that the involved bone was histologically normal, even though it appeared abnormal radiologically. Presumably the reason for this apparent discrepancy is that the lesion directly involved mainly the dura and the space between the pericranium and the outer table. The bone between was thus involved little if at all, except that it transmitted some communicating vessels. Presumably its radiographically abnormal appearance was secondary to its intimate relation with abnormal vessels, which may have transmitted abnormal pressure. It has been suggested that skull changes in sinus pericranii might be caused by vascular pressure [14, 16]; alternatively one might speculate that both the vascular and osseous abnormalities might be responses to some relatively minor insult during fetal life.

REFERENCES

1. Stout AP, Lattes P. Tumors of the soft tissues. In: *Atlas of tumor pathology*, 2d series, fasc 1. Washington, DC: Armed Forces Institute of Pathology, 1967:67
2. Newton TH, Troost BT. Arteriovenous malformations and fistulae. In: Newton TH, Potts DG, eds. *Radiology of the skull and brain*, vol 2, book 4. St. Louis: Mosby, 1974:2490-2565
3. Voigt K, Yasargil MG. Cerebral cavernous hemangiomas or cavernomas. *Neurochirurgia* (Stuttg) 1976;19:59-68
4. Wyke BD. Primary hemangioma of the skull: a rare cranial tumor. *Radiology* 1949;61:302-316
5. Kessler LA, Lubic LG, Koskoff YD. Epidural hemorrhage secondary to cavernous hemangioma of the petrous portion of the temporal bone. *J Neurosurg* 1957;14:329-331
6. Kawai K, Fukui M, Tanaka A, Kuramoto S, Kitamura K. Extracerebral cavernous hemangioma of the middle fossa. *Surg Neurol* 1978;9:19-25
7. McCormick WF, Boulter TR. Vascular malformations ("angiomas") of the dura mater: report of two cases. *J Neurosurg* 1966;25:309-311
8. Pasztor E, Szabo G, Slowik F, Zoltan J. Cavernous hemangioma of the base of the skull: report of a case treated surgically. *J Neurosurg* 1964;21:582-585
9. Cohn I. Sinus pericranii (Strohmeyer). *Surg Gynecol Obstet* 1926;42:614-624
10. Arrues MA, Dickmann GH, Pataro VF. Sinus pericranii (five cases). *Angiology* 1956;7:186-193
11. Poppel MH, Roach JF, Hamlin H. Cavernous hemangioma of the frontal bone with report of a case of sinus pericranii. *Radiology* 1948;59:505-510
12. Doran Y, Peyser MD. Sinus pericranii—angiographic demonstration. *Neurochirurgia* (Stuttg) 1971;14:108-110
13. Nakayama T, Matsukado Y. Sinus pericranii with aneurysmal malformation of the internal cerebral vein. *Surg Neurol* 1975;3:133-137
14. Ohta T, Waga S, Handa H, Nishimura S, Mitani T. Sinus pericranii. *J Neurosurg* 1975;42:704-712
15. Pendergrass EP, Schaeffer JP, Hodes PJ. *The head and neck in roentgen diagnosis*, 2d ed. Springfield, IL: Thomas, 1956:376-379
16. Hahn EV. Sinus pericranii (reducible blood tumor of the cranium): its origin and its relation to hemangioma and abnormal arteriovenous communication: report of a case. *Arch Surg* 1928;16:31-43
17. Taveras JT, Wood EH. *Diagnostic neuroradiology*, 2d ed. Baltimore: Williams & Wilkins, 1976:30-32, 119-120