

Are your **MRI contrast agents** cost-effective?

Learn more about generic **Gadolinium-Based Contrast Agents**.



FRESENIUS
KABI

caring for life

AJNR

Fenestration of the supraclinoid internal carotid artery with rupture of associated aneurysm.

D H Yock, Jr

AJNR Am J Neuroradiol 1984, 5 (5) 634-636

<http://www.ajnr.org/content/5/5/634.citation>

This information is current as
of April 20, 2024.

Fenestration of the Supraclinoid Internal Carotid Artery with Rupture of Associated Aneurysm

Douglas H. Yock, Jr.¹

Fenestration of cerebral arteries is a rare anomaly sometimes accompanied by a small proximal aneurysm. Our patient was seen with subarachnoid hemorrhage from a fenestration-aneurysm of the supraclinoid internal carotid artery (ICA).

Case Report

A 41-year-old woman was seen at an outside hospital with acute onset of an "exploding" headache accompanied by nausea, vomiting, photophobia, and neck stiffness. There was no history of trauma or illness. Examination showed an afebrile, acutely uncomfortable pa-

tient with slight left facial weakness, and intermittent left extensor plantar response were noted. Nausea, neck rigidity, and headache diminished, with residual dull pain behind the right eye.

A cerebral angiogram 2 days after admission (figs. 1A and 1B) was interpreted as normal, with mention of superimposed vessels projecting over the distal right ICA. Another angiogram on hospital day 16 was thought to show an unusual right posterior communicating artery-origin aneurysm. The two angiograms were reviewed at our institution, and the suggestion of a small aneurysm associated with fenestration of the right supraclinoid ICA was made. A third angiogram with oblique positioning appeared to confirm this morphology (figs. 1C and 1D).

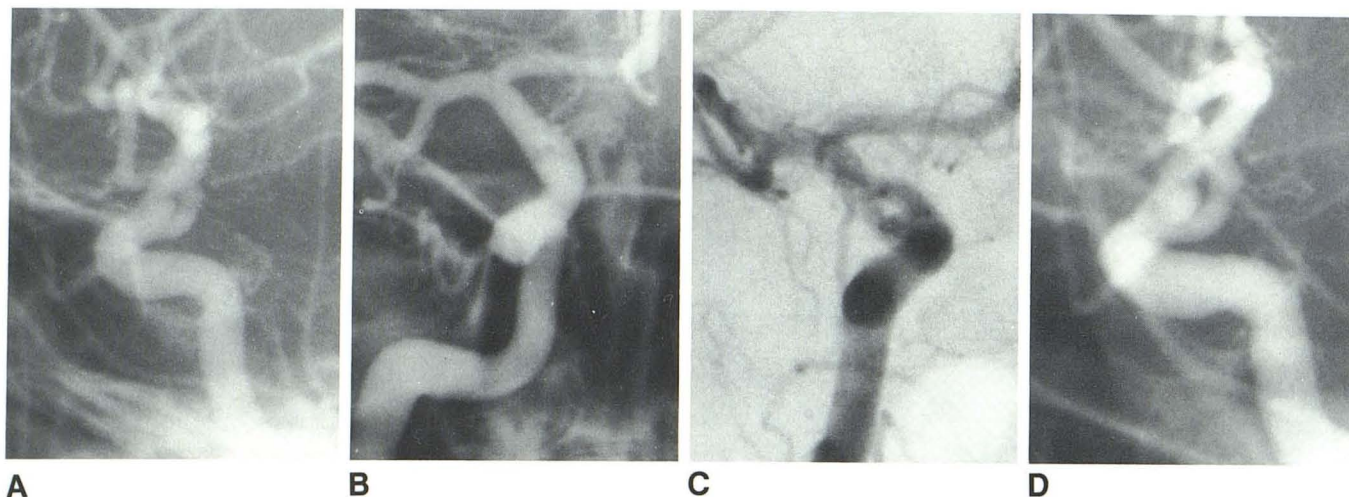


Fig. 1.—A and B, Initial angiograms at outside hospital. A, Lateral projection. Supraclinoid ICA fenestration-aneurysm complex is partly obscured by overlying middle cerebral artery. B, Anteroposterior projection. Fenestration-aneurysm complex is superimposed on itself as double density. C and D, Angiograms

at Metropolitan Medical Center. C, Anteroposterior oblique view documents fenestration of supraclinoid ICA, with small aneurysm almost hidden in proximal fork. D, Lateral oblique film shows aneurysm arising proximally and lying between limbs of fenestration.

tient, fully alert and oriented. Motor and sensory examinations, cranial nerve function, and fundoscopic examination were normal. A computed tomographic (CT) scan was interpreted as normal, and a diagnosis of viral meningitis was entertained. Lumbar puncture yielded bright red spinal fluid, and the diagnosis was changed to subarachnoid hemorrhage.

Over the next 2 weeks the patient remained stable with no impairment of consciousness. Occasional left face and hand numbness,

A craniotomy was performed on hospital day 19. A small, very thin-walled aneurysm was found within a short fenestration of the right supraclinoid ICA. The aneurysm arose with a broad base from the larger of the two channels at the proximal end of the fenestration. It was not possible to selectively clip the aneurysm neck, and the dome was wrapped with gauze and muscle. The patient made an excellent recovery and was discharged 2 weeks after surgery. She was still asymptomatic after 1 year of follow-up.

Received March 14, 1983; accepted after revision July 25, 1983.

¹ Department of Radiology, Metropolitan Medical Center, 900 S. Eighth St., Minneapolis, MN 55404.

TABLE 1: Summary of Prior Reports of Fenestration-Aneurysms

Fenestrated Artery [refs.]	No. of Cases		
	Total	With Aneurysm at Site	With Aneurysm Rupture
Vertebral [3, 11, 15, 16]	57*	0†	0
Basilar [5-7, 11, 17-20]	11‡	7	5
Anterior cerebral [4, 8-11, 21]	38	2	1
Middle cerebral [4, 9-14]	13	0	0
Internal carotid [1, 2]§	2	0	0

* Predominantly Japanese literature.

† Twelve were associated with aneurysms elsewhere.

‡ By angiography; autopsy incidence ranges from 1% to 5%.

§ Cervical segment.




Fig. 2.—Characteristic morphology of intracranial fenestration-aneurysm complex (see text).

Discussion

We believe this to be the first reported case of fenestration of the intracranial ICA. Two cases of cervical ICA fenestration have been recorded [1, 2].

Cerebral artery fenestration at other sites is infrequent but well recognized. Miyazaki et al. [3] summarized 57 cases of vertebral artery fenestration, with most located extracranially. Basilar artery fenestration occurs with an autopsy incidence of 1%–5% and most often involves the proximal segment of the artery [4–7]. Fenestration of the anterior cerebral artery is found in about 1% of autopsies, almost always affecting the A1 segment [8]. Similarly, middle cerebral artery fenestrations have been seen exclusively in the M1 segment, with 13 reported cases [4, 9–14].

The association of aneurysms with fenestration is uncommon (table 1). Vertebral artery fenestration has coexisted with intracranial aneurysm in about 20% of case reports, but all of the aneurysms have been remote from the fenestration [3]. Seven of 11 reported cases of angiographically demonstrated basilar artery fenestration have had aneurysms at the fenestration site [5–7, 11, 17–20]. An aneurysm was found within an anterior cerebral artery fenestration in two of 38 recorded autopsy and angiographic cases [4, 8–11, 21]. No instance of true middle cerebral artery fenestration has been reported with an aneurysm at the fenestration, but simple duplication of the middle cerebral artery was associated with adjacent aneurysm in four patients [22–24].

Subarachnoid hemorrhage from ruptured fenestration aneurysms is rare. This is the seventh such case, with five previous instances of ruptured basilar artery fenestration aneurysms [5, 7, 17–19] and a recent report of a ruptured anterior cerebral artery fenestration aneurysm [21].

The morphology of intracranial fenestration aneurysms has been strikingly similar regardless of site. In all cases a small aneurysm has arisen at the proximal end of a short fenestrated segment. The aneurysm typically originates on the inner aspect of the bifurcation and points distally, cradled between the limbs of the artery (fig. 2).

Angiographers familiar with fenestration aneurysms will recognize their characteristic morphology in suspicious areas of vascular overlap. Although the proximal basilar artery is the most important site for these lesions, they may occur elsewhere, as illustrated in our case.

REFERENCES

1. Tanaka M, Matsumoto S. Fenestration of the internal carotid artery. *Neurol Med Chir (Tokyo)* 1982;4:291–294
2. Killien F, Wyler A, Cromwell L. Duplication of the internal carotid artery. *Neuroradiology* 1980;19:101–102
3. Miyazaki S, Kamata K, Yamaura A. Multiple aneurysms of the vertebrobasilar system associated with fenestration of the vertebral artery. *Surg Neurol* 1981;15:192–195
4. Wollschlaeger G, Wollschlaeger P, Lucas F, Lopez V. Experience and result with postmortem cerebral angiography performed as routine procedure of the autopsy. *AJR* 1967;101:68–87
5. Hoffman WF, Wilson CB. Fenestrated basilar artery with an associated saccular aneurysm. *J Neurosurg* 1979;50:262–264
6. Takahashi M, Tamakawa Y, Kishikawa T, Kowada M. Fenestration of the basilar artery. *Radiology* 1973;109:79–82
7. Nakasu Y, Nakasu S, Kidooka M, Handa J. Aneurysm at the fenestration of the basilar artery. *Nippon Geka Hokan* 1982;51:344–348
8. Ito J, Washiyama K, Kim C, Ibuchi Y. Fenestration of the anterior cerebral artery. *Neuroradiology* 1981;21:277–280
9. Crompton MR. The pathology of ruptured middle cerebral artery aneurysms. *Lancet* 1962;2:421–425
10. McCormick WF. Vascular disorders of nervous tissue: anomalies, malformations, and aneurysms. In: Bourne GH, ed. *The structure and function of nervous tissue*. New York: Academic Press,

- 1969:537-596
11. Teal JS, Rumbaugh CL, Bergeron RT, Segall HD. Angiographic demonstration of fenestrations of the intradural intracranial arteries. *Radiology* **1973**;106:123-126
 12. Ito J, Maeda H, Inoue K, Onishi Y. Fenestration of the middle cerebral artery. *Neuroradiology* **1977**;13:37-39
 13. Lazar M, Bland J, North R, Bringewald P. Middle cerebral artery fenestration. *Neurosurgery* **1980**;6:297-300
 14. Kwak R, Kuwahara K, Niizuma H, Suzuki J. Anomalies of the middle cerebral artery with intracranial saccular aneurysms—duplication and fenestration. *No Shinkei Geka* **1979**;7:691-696
 15. Kowada M, Takahashi M, Gito Y, Kishikawa T. Fenestration of the vertebral artery. *Neuroradiology* **1973**;6:110-112
 16. Shigemori M, Shirahama M, Tokutomi T, Nakashima O. Bilateral fenestration of the vertebral artery in a case with cerebral aneurysm. *Kurume Med J* **1981**;28:79-82
 17. Becker D, Hamilton R. Saccular aneurysm associated with fenestrated basilar artery: case report. *Neurosurgery* **1979**;5:695-697
 18. Hemmati M, Kim K. A ruptured aneurysm at the basilar artery fenestration. *Radiology* **1979**;130:174
 19. Matricali B, Van Dulken H. Aneurysm of fenestrated basilar artery. *Surg Neurol* **1981**;15:189-191
 20. Taveras JM, Wood EH. *Diagnostic neuroradiology*, 2d ed. Baltimore: Williams & Wilkins, **1976**:795
 21. Yamada T, Inagawa T, Takeda T. Ruptured aneurysm at the anterior cerebral artery fenestration. *J Neurosurg* **1982**;57:826-829
 22. Stabler J. Two cases of accessory middle cerebral artery, including one with an aneurysm at its origin. *Br J Radiol* **1970**;43:314-318
 23. In S, In K, Kusano N, Mizuki H, Miyasi J, Kuramoto S. A case of duplication of the middle cerebral artery with ruptured aneurysm on its origin during pregnancy. *No Shinkei Geka* **1981**;9:337-341
 24. Teal JS, Rumbaugh CL, Bergeron RT, Segall HD. Anomalies of the middle cerebral artery: accessory artery, duplication, and early bifurcation. *AJR* **1973**;118:567-575