

Are your **MRI contrast agents** cost-effective?

Learn more about generic **Gadolinium-Based Contrast Agents**.



FRESENIUS
KABI

caring for life

AJNR

**Sinus pericranii and venous angioma in the
blue-rubber bleb nevus syndrome.**

R G Sherry, M L Walker and M V Olds

AJNR Am J Neuroradiol 1984, 5 (6) 832-834

<http://www.ajnr.org/content/5/6/832.citation>

This information is current as
of April 17, 2024.

Sinus Pericranii and Venous Angioma in the Blue-Rubber Bleb Nevus Syndrome

Richard G. Sherry,¹ Marion L. Walker,² and Meredith V. Olds²

The pathologic changes of blue-rubber bleb nevus syndrome have been known for over 100 years, but it was not until 1958 that a detailed description of the syndrome was published. Bean [1] described a disorder characterized by bluish nevi scattered throughout the skin and angiomas of the gastrointestinal tract that could be a source of serious bleeding. Larger skin lesions typically have the consistency of rubber nipples, have a bluish cast, are easily compressible, and refill promptly when compression is released.

The syndrome is well known among dermatologists and gastroenterologists but generally not known among neuroradiologists. We draw attention to this syndrome because, although rare, it seems to be associated with significant central nervous system (CNS) abnormalities. We recently evaluated a patient with this syndrome who had frontal sinus pericranii and a giant venous angioma that drained extracranially through a large varix.

Case Report

A 6-month-old boy was referred for radiologic evaluation of a gradually enlarging, fluctuant mass on the forehead to the right of the midline. The child was noted at birth to have multiple cutaneous hemangiomas in addition to the lesion on his forehead. The mass expanded noticeably when the child cried or when his head was placed in a dependent position. The mass could be reduced with gentle pressure. Palpation and plain radiography revealed a 1-cm skull defect beneath the mass.

On physical examination, there were scattered, bluish, rubbery, nipplelike nevi on the trunk (fig. 1) and extremities. These nevi blanched with pressure and were thought to be diagnostic of blue-rubber bleb nevus syndrome. There was no abdominal organomegaly and no evidence of intestinal bleeding. The neurologic examination was normal for age. The blood cell and platelet counts were normal. No cranial bruit was heard. There was no family history of skin lesions.

Contrast-enhanced computed tomography (CT) revealed a vascular malformation in the right frontal lobe with a large varix emptying into the anterior aspect of the superior sagittal sinus (fig. 2A). The frontal bone defect and communication of the vascular forehead mass and the underlying sagittal sinus were clearly demonstrated by CT (fig. 2B). Cerebral angiography was performed to evaluate the intra-

cranial vascular malformation. The left carotid angiogram was unremarkable. The right internal carotid angiogram (figs. 2C and 2D) showed a large venous angioma in the right frontal lobe and a varix communicating with the superior sagittal sinus anteriorly. Subtraction films late in the venous phase showed very faint opacification of the forehead mass. The arterial phase was normal.

The patient underwent a right frontal craniectomy and resection of the forehead mass. The mass was separated from the scalp and pericranium, then reduced in size by bipolar coagulation. After its connection with the subcranial dura was exposed, the extradural

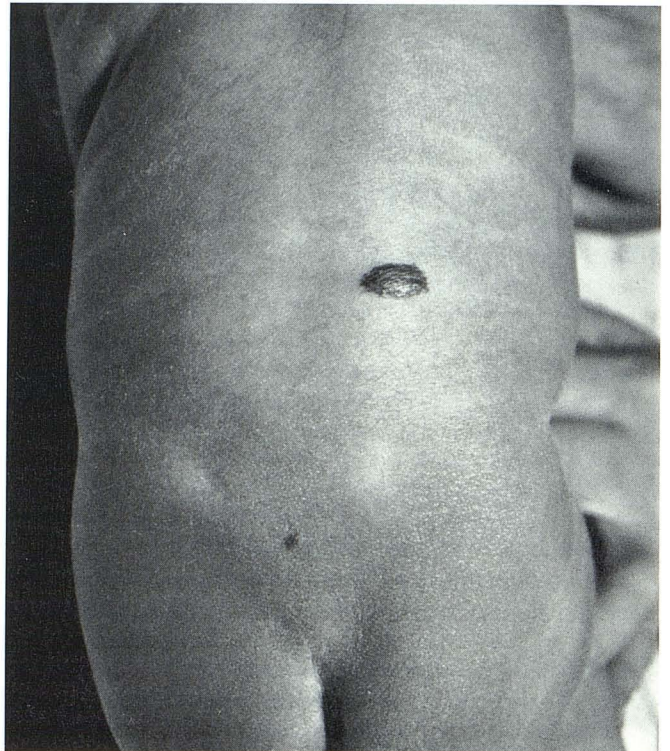


Fig. 1.—Characteristic raised, rubbery, blue, nipplelike nevus of blue-rubber bleb nevus syndrome on patient's back. Smaller lesion on sacrum; others were scattered on right shoulder, chest, abdomen, and extremities.

Received May 5, 1983; accepted after revision July 8, 1983.

¹ Department of Radiology, University of Utah School of Medicine, Salt Lake City, UT 84132. Present address: Department of Radiology, State University of New York, Upstate Medical Center, Syracuse, NY 13210. Address reprint requests to R. G. Sherry.

² Department of Neurosurgery, University of Utah School of Medicine, Salt Lake City, UT 84132.

AJNR 5:832-834, November/December 1984 0195-6108/84/0506-0832 \$00.00 © American Roentgen Ray Society

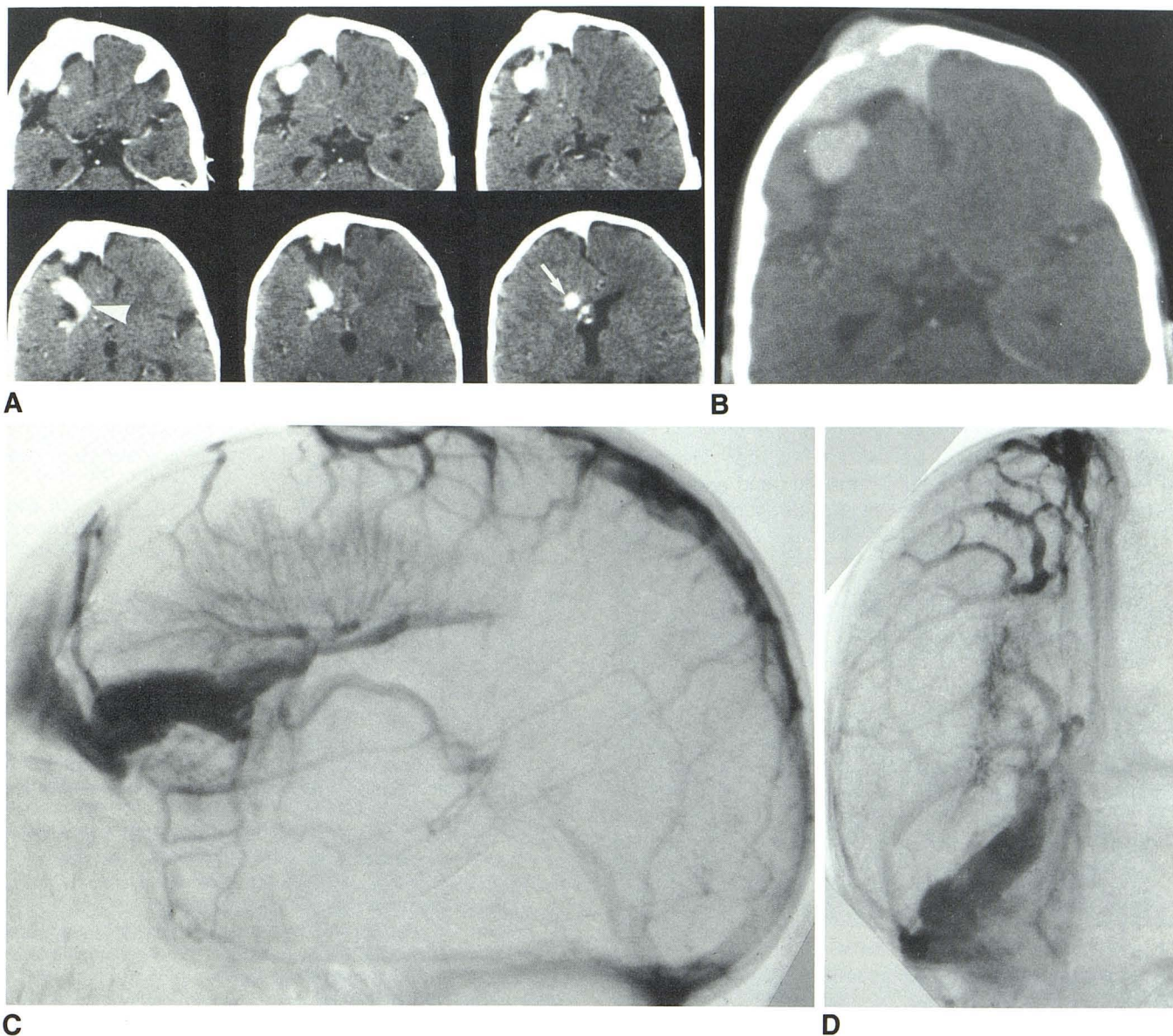


Fig. 2.—A, Selected contrast-enhanced scans. Transcerebral vein (arrow) drains into varix (arrowhead). Unusual deep fissure in inferior right frontal lobe; distortion of medial surface of right frontal lobe with displacement of cingulate gyrus and anterior cerebral arteries. B, Contrast-enhanced scan at bone window settings. Defect in right frontal bone; communication of intra- and

extracranial parts of sinus. Lateral (C) and anteroposterior (D) views, venous phase of right carotid angiogram. Giant frontal-lobe venous angioma. Subependymal veins are enlarged; internal cerebral vein is dilated and tortuous. Predominant drainage is through large transcerebral vein into varix communicating with frontal pericranial sinus.

mass was totally excised. A bone graft was taken from the temporal bone and placed in the frontal craniectomy site. Microscopic examination showed both arterial and venous channels within the vascular mass.

An excellent cosmetic result was obtained, and regrowth of the bone in the temporal craniectomy site has occurred. There has been no recurrence of the extracranial mass and no neurologic impairment.

Discussion

Bean's original report of the blue-rubber bleb nevus syndrome described the unique appearance of the bluish, rubbery subcutaneous nevi and emphasized that a spectrum of vas-

cular lesions may be distributed widely throughout the body [1]. Of particular interest is an account of a seizure and an abnormal electroencephalographic focus in the right temporal lobe of this patient, suggesting a CNS lesion.

Other patients with disseminated hemangiomatosis resembling this syndrome have been reported, all having CNS lesions [2-4]. More recently, Waybright et al. [5] described a patient with blue-rubber bleb nevus syndrome and thrombosis of a vein of Galen aneurysm. This patient also had numerous vascular lesions involving the skin, right atrium, pericardium, parietal pleura, and surface of the brain. These malformations varied histologically but included capillary telangiectasias, cav-

ernous and venous angiomas, and arteriovenous malformations. A detailed histologic analysis of this patient's lesions [6] emphasized the variety of malformations present in the syndrome and suggested there may be an overlap between it and Rendu-Osler-Weber syndrome.

Our patient's chief abnormality was a tumescent, compressible mass on the forehead. A diagnosis of blue-rubber bleb nevus syndrome was established at birth by physical examination. The angiographic appearance of the intracranial lesion was characteristic of venous angioma [7-12]. A unique feature of this case was the predominant flow through a short transcerebral vein into a large varix draining anteriorly. The varix was on the surface of the brain, lying in a deep fissure in the orbital surface of the frontal lobe. The fissure may have been an atrophic feature or abnormally developed orbital sulcus (fig. 1B).

The unusual association of venous angioma and cerebral varix has been described by Meyer et al. [13]. Their case differs slightly from ours in that the angioma was somewhat atypical: Relatively few medullary veins were present, and they were not oriented in the usual radiating or "spoke-wheel" configuration. Also the saccular part of the varix appeared to lie in the brain parenchyma, whereas in our case, the most dilated part of the varix was superficial.

We could find only one other patient described in the literature with angiographic features resembling our case. That patient had a soft mass in the left frontal region, clinically thought to be a sinus pericranii [14]. No skin lesions were described. Carotid angiography revealed a giant left-cerebral-hemisphere venous malformation. Faint opacification of the scalp mass confirmed the clinical diagnosis of sinus pericranii. The subcutaneous part of that patient's pericranial sinus was eradicated, and he did well until 6 years later when he had severe persistent headache, seizures, loss of consciousness, and a postictal right hemiplegia. Gradual recovery occurred, and follow-up carotid angiography showed disappearance of the aneurysmal venous malformation and regression of the dilated deep cerebral veins. The clinical course and angiographic findings were believed to indicate spontaneous thrombosis of the malformation.

This clinical course is particularly intriguing in light of the patient described by Waybright et al. [5] with blue-rubber bleb nevus syndrome who had severe headache and left-arm seizures. CT, angiography, and subsequent postmortem examination confirmed thrombosis of an aneurysmally dilated vein of Galen. Thrombosis of vascular lesions seems to be an important facet of the syndrome [5, 6, 15] and may be a complication of large intracerebral venous malformations in general.

Coincident occurrence of intracerebral venous angiomas

and external venous angiomas has been described [16], but the multiplicity of vascular lesions known to occur in this syndrome suggests a causal relation in our patient. Indeed, many published reports of proven or presumed blue-rubber bleb nevus syndrome indicate CNS vascular lesions are routinely encountered [1-6]. Although the condition is rare, the neuroradiologist should be aware of the associated intracranial vascular malformations that can occur in this syndrome.

REFERENCES

1. Bean WB. *Vascular spiders and related lesions of the skin*. Springfield, IL: Thomas, 1958:178-185
2. Jaffe RH. Multiple hemangiomas of the skin and of the internal organs. *Arch Pathol* 1929;7:44-54
3. Burke EC, Winkelmann RK, Strickland MK. Disseminated hemangiomatosis. *Am J Dis Child* 1964;108:418-424
4. Wood MW, White RJ, Kernohan JW. Cavernous hemangiomatosis involving the brain, spinal cord, heart, skin and kidney. *Proc Mayo Clin* 1957;32:249-254
5. Waybright EA, Selhorst JB, Rosenblum WI, Suter CG. Blue rubber bleb nevus syndrome with CNS involvement and thrombosis of a vein of Galen malformation. *Ann Neurol* 1978;3:464-467
6. Rosenblum WI, Nakoneczna I, Konerding HS, Nocklin D, Ghatak NR. Multiple vascular malformation in the "blue rubber bleb naevus" syndrome: a case with aneurysm of vein of Galen and vascular lesions suggesting a link to the Weber-Osler-Rendu syndrome. *Histopathology* 1978;2:301-311
7. Saito Y, Kobayashi N. Cerebral venous angiomas: clinical evaluation and possible etiology. *Radiology* 1981;139:87-94
8. Solomon EH, Bonstelle CT, Modic MT, Kaufman B. Angiographic and computed tomographic correlation in cerebral venous angiomas. *CT* 1980;4:217-220
9. Wendling LR, Moore JS, Kieffer SA, Goldberg HI, Latchaw RE. Intracerebral venous angioma. *Radiology* 1976;119:141-147
10. Scotti LN, Goldman RL, Rao GR, Heinz ER. Cerebral venous angioma. *Neuroradiology* 1975;9:125-128
11. Fierstein SB, Pribram HW, Hieshima G. Angiography and computed tomography in the evaluation of cerebral venous malformations. *Neuroradiology* 1979;17:137-148
12. Sarwar M, McCormick WF. Intracerebral venous angioma. *Arch Neurol* 1978;35:323-325
13. Meyer JD, Baghai P, Latchaw RE. Cerebral varix and probable venous angioma: an unusual isolated anomaly. *AJNR* 1983;4:85-87
14. Nakayama T, Maksudado Y. Sinus pericranii with aneurysmal malformation of the internal cerebral vein. *Surg Neurol* 1975;3:133-137
15. Fretzin DF, Potter B. Blue rubber bleb nevus. *Arch Intern Med* 1965;116:924-929
16. Branch CE, Kunath AM, Buscemi JH. Sublingual venous angioma: marker of intracranial lesion? *Arch Neurol* 1981;38:259-260