

Are your **MRI contrast agents** cost-effective?

Learn more about generic **Gadolinium-Based Contrast Agents**.



FRESENIUS
KABI

caring for life

AJNR

Otosclerosis: comparison of complex-motion tomography and computed tomography.

K Chintapalli, J M Unger, K Shaffer and S J Millen

AJNR Am J Neuroradiol 1985, 6 (1) 85-89

<http://www.ajnr.org/content/6/1/85>

This information is current as
of April 20, 2024.

Otosclerosis: Comparison of Complex-Motion Tomography and Computed Tomography

Kedar Chintapalli^{1,2}
June M. Unger^{1,2}
Katherine Shaffer^{1,2}
Steven J. Millen³

A prospective computed tomographic and complex-motion tomographic evaluation was performed in 18 suspected or proven cases of otosclerosis. Although there was good agreement between both methods, there was no greater diagnostic accuracy with computed tomography. However, computed tomography demonstrated the changes better than complex-motion tomography.

Otosclerosis is a primary disease of the labyrinthine capsule. It usually occurs in the second decade of life and is manifested by slowly progressive hearing loss. Although the diagnosis has traditionally been established by history, clinical examination, and audiometry, it is not always conclusive. Since the 1960s complex-motion tomography has been available as an ancillary diagnostic measure, but not until the late 1970s was computed tomography (CT) sufficiently refined to determine subtle changes within the temporal bone. Because the superior contrast resolution of CT has been shown to compensate for the better spatial resolution of complex-motion tomography [1-5], we elected to use both methods in a group of patients with otologic evidence of otosclerosis to evaluate the potential advantages of one technique over the other.

Pathology

The initial site of the otosclerotic process [6] is the fissula ante fenestram, a plate of cartilage in the labyrinthine capsule immediately anterior to the oval (vestibular) window. As the disease advances there is involvement of the annular ligament of the stapedial footplate with eventual fibrous fixation of the footplate within the oval window. Subsequent changes progress to involve the round (cochlear) window and basal turn. In late stages, there may be involvement of the remaining otic capsular structures and petrosa.

Fixation of the stapes in the oval window and/or obliteration of the round window produces conductive hearing loss. Sensorineural hearing loss is a result of more advanced involvement of the otic capsule.

On histopathologic sections (fig. 1) there is initially destruction of endochondral bone with the formation of spaces by resorption. This is seen as spongiotic change on radiographs and implies active disease. Remodeling with new, well mineralized bone produces the sclerotic changes associated with mature disease.

Subjects and Methods

Eighteen patients with clinical and audiometric findings consistent with otosclerosis, or prior surgery for otosclerosis, were evaluated. Complex-motion tomography (hypocycloidal) was done on a Philips Polytome unit in coronal and 20° semiaxial (Guillen) projections. Two mm sections through the temporal bone were supplanted by 1 mm sections through the oval and round window areas (fig. 2) CT was done on a GE 8800 CT/T scanner. A scout image

Received March 19, 1984; accepted after revision July 23, 1984.

¹ Department of Radiology/114, Veterans Administration Medical Center, Wood, WI 53193. Address reprint requests to K. Chintapalli.

² Department of Radiology, Medical College of Wisconsin, Milwaukee, WI 53226.

³ Department of Otolaryngology, Veterans Administration Medical Center, Wood, WI 53193, and Medical College of Wisconsin, Milwaukee, WI 53226.

AJNR 6:85-89, January/February 1985
0195-6108/85/0601-0085 \$00.00
© American Roentgen Ray Society

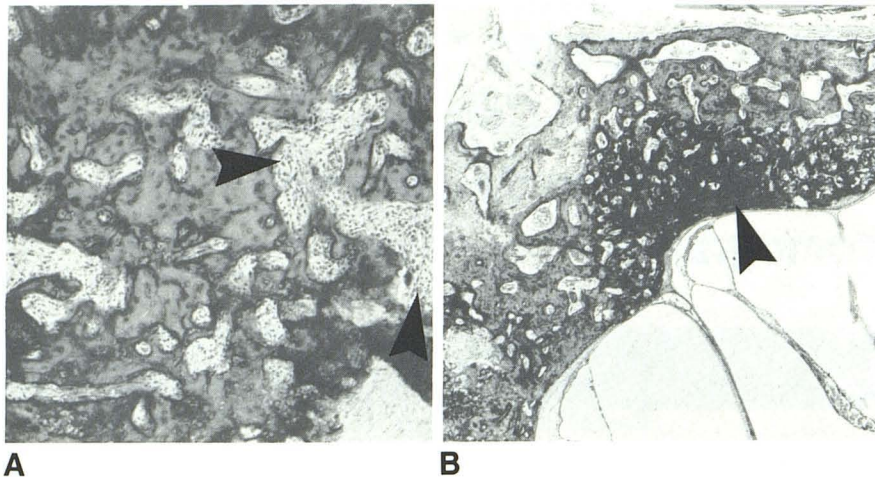


Fig. 1.—**A**, Focus of spongiotic change with areas of resorption (*arrowheads*). **B**, Sclerotic bone (*arrowhead*) in lateral wall of otic capsule at level of oval window. (Reprinted from [6].)

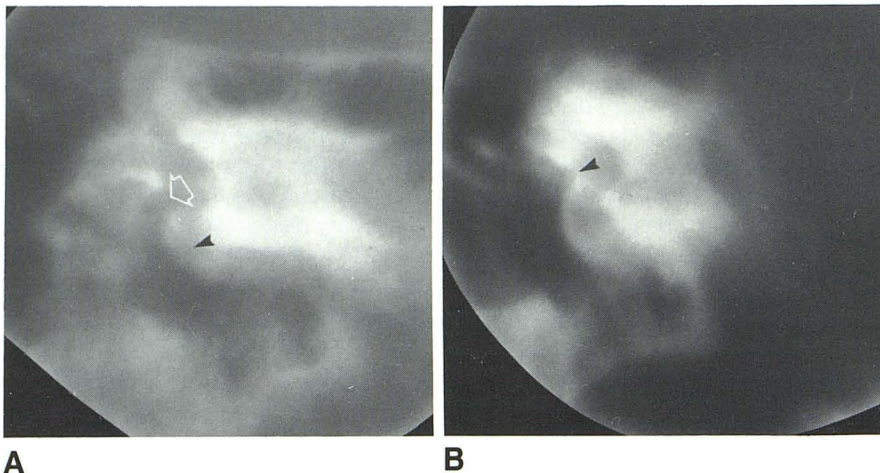


Fig. 2.—**A**, Coronal tomogram. Normal oval window (*arrow*) and round window (*arrowhead*). **B**, Semiaxial tomogram. Normal footplate of stapes (*arrowhead*).

was obtained for coronal CT scans in the supine position with the patient's neck hyperextended. Gantry angulation was used only when the patient was unable to extend his neck fully. The region of the internal auditory canals was localized by three 5 mm scans. Overlapping 1.5 mm sections at 1 mm increments were target-reconstructed with a bone algorithm at a magnification of 3.2 and pixel size of 0.25 mm. Images were viewed on an extended scale at a window level of 400 and window width of 4000 H (fig. 3). The complex-motion tomograms and CT scans were interpreted independently and concurrently by three radiologists, two of whom subspecialize in otolaryngologic radiology. We looked for narrowing of the oval window by sclerotic bone or a thickened stapedial footplate, foci of demineralization adjacent to the oval or round windows, and spongiotic or sclerotic changes in the otic capsule, particularly in the basal turn of the cochlea. Measurements of the vestibular and cochlear windows and thickness of the stapedial footplate were considered imprecise and accordingly omitted.

Results

Among the 18 patients examined, there were 17 ears for which surgery had been performed for otosclerosis and 19 ears without surgery. The radiographic findings of the oval

window, round window, and otic capsule were reviewed together. In both groups of patients there was essentially agreement between the complex-motion tomograms and CT scans. The hearing loss in operated patients in table 1 denotes the presurgical status. The radiographic results are tabulated in table 2. The complex-motion tomograms of one temporal bone in each group were considered suboptimal for technical reasons.

Discussion

Complex-motion tomography has been used to establish the diagnosis of otosclerosis [7–11] when clinical findings are equivocal and to evaluate the extent of disease when there is known involvement. In the preoperative patient with bilateral otosclerosis, it has been used as an ancillary means of selection of the side for surgery; postoperatively, the location of a prosthesis or progression of the disease process may be determined. We used CT for the same purposes, examples of which are provided in figures 4–8.

Diagnostic pitfalls in the radiographic diagnosis of otosclerosis include those that are equipment-related and those that

Fig. 3.—A, Axial CT scan. Normal stapedial footplate covering normal oval window opening (*arrow*). B, Axial CT scan. Normal round window (*arrowhead*). C, Coronal CT scan. Normal oval window (*arrow*) in patient with normal hearing. D, Coronal CT scan. Normal round window (*arrow*).

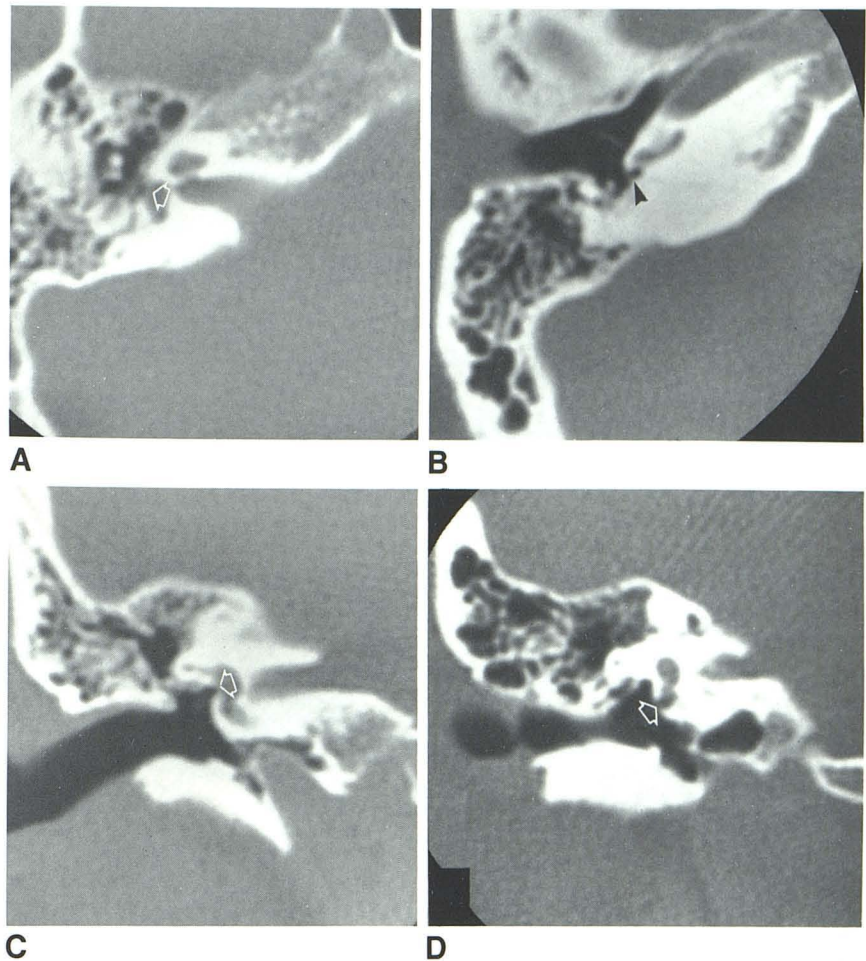


TABLE 1: Types of Hearing Loss in Patients with and without Previous Surgery

Type of Hearing Loss	No. of Ears	
	Nonoperated	Operated*
Conductive	6	4
Mixed	7	10
Sensorineural only	1	3
Normal hearing	5	0
Total	19	17

* Hearing loss is based on the presurgical status of the 12 patients who had had surgery.

TABLE 2: Correlation of CT and Complex-Motion Tomography in the Assessment of Otosclerosis

Finding	Nonoperated		Operated	
	CT	Tomography	CT	Tomography
Positive	11	11	13	12
Negative	8	7	4	4
Total	19	18*	17	16*

* Tomography was suboptimal in one case.

occur because of the anatomic peculiarities of the structures under investigation, particularly the labyrinthine windows. With complex-motion tomography, artifacts may be generated by phantom imaging of adjacent structures; there may also be unsharpness due to imperfect blurring. The principles of thin-section imaging are totally different with CT, and theoretically both of the above problems should be eliminated. We sought to correct for the anticipated partial-volume averaging on CT scans by using overlapping thin sections and found this to be effective. While the 20° semiaxial plane has been

generally accepted as the most satisfactory for viewing the oval window with complex-motion tomography, there has been disagreement regarding the optimal plane for CT imaging [12, 13]. Because of the oblique orientation of the oval window, which lies in the plane of the medial wall of the middle ear, one would expect to demonstrate this structure best in the axial or 20° semiaxial (Guillen) projection. In practice, however, we agree with those who have found the coronal images equally reliable, and occasionally preferable [13]. Although the round window size (1–2 × 3 mm) is similar to that of the oval window (2.9 × 1.4 mm) [14], we have found the

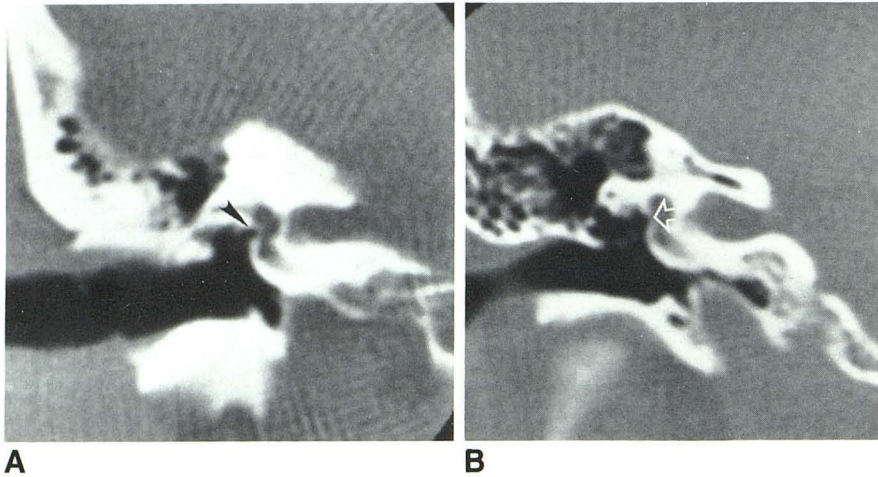


Fig. 4.—**A**, Coronal CT scan. Thickened footplate (*arrowhead*) across normal-sized oval window. **B**, Coronal CT scan. Narrow right oval window (*arrow*) in patient who had left stapedectomy for otosclerosis 2 years before. At that time, hearing was normal in right ear suggesting otosclerotic involvement in interim.

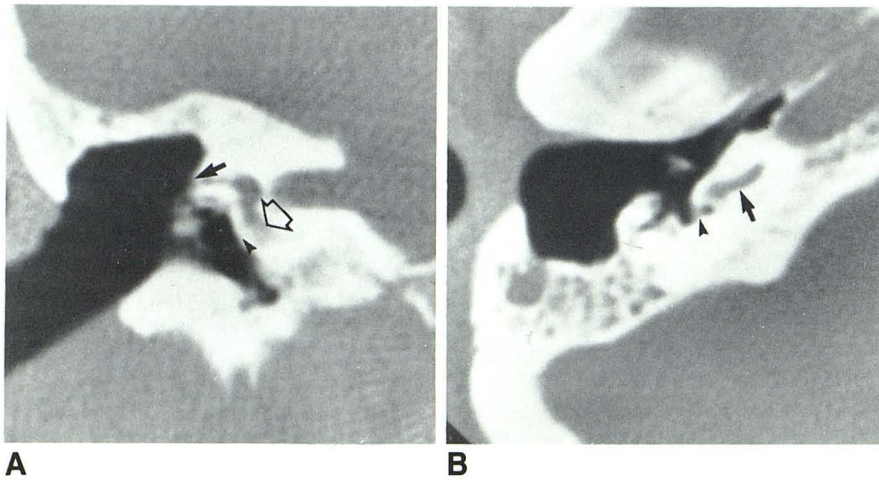


Fig. 5.—**A**, Coronal CT scan. Obliterated round window (*arrowhead*), fenestration defect (*closed arrow*), and suspect sclerotic change in basal turn (*open arrow*). **B**, Axial CT scan, same patient. Obliterated round window (*arrowhead*). Basal turn of cochlea is normal (*arrow*) in this view.

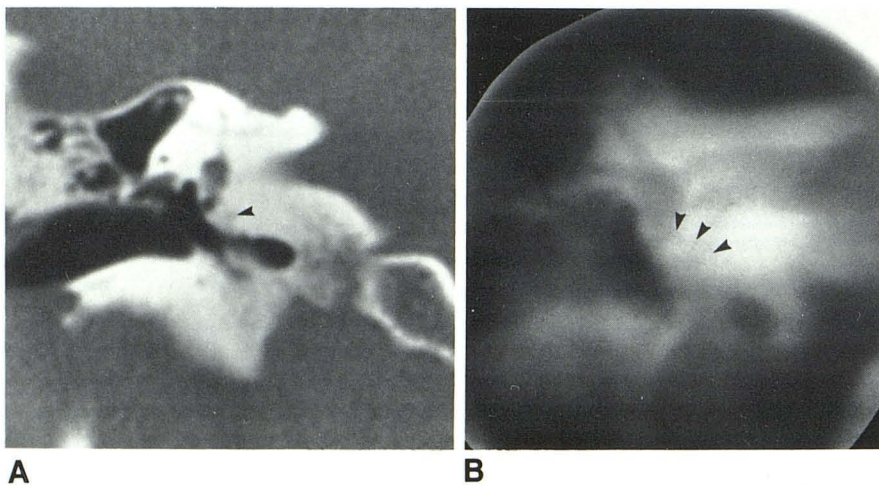


Fig. 6.—**A**, Area of spongiosis (*arrowhead*) in patient with sensorineural hearing loss. **B**, Coronal tomogram, same patient. Spongiotic change (*arrowheads*).

round window more difficult to evaluate because of anatomic variations in the window and surrounding bone.

We found it surprising that spongiotic and questionable sclerotic otic capsule changes were demonstrated in only two

patients despite the relatively high incidence of sensorineural involvement. We anticipated a greater sensitivity with CT than with tomography because of the superior contrast resolution but concluded that, if present, the changes were sufficiently

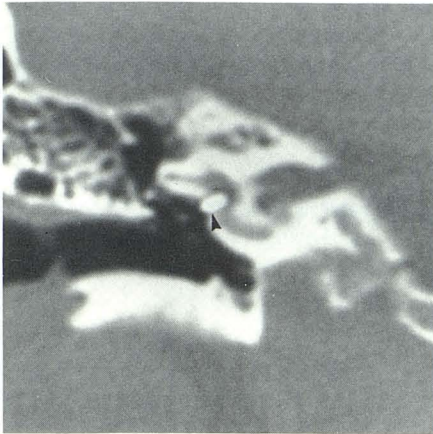
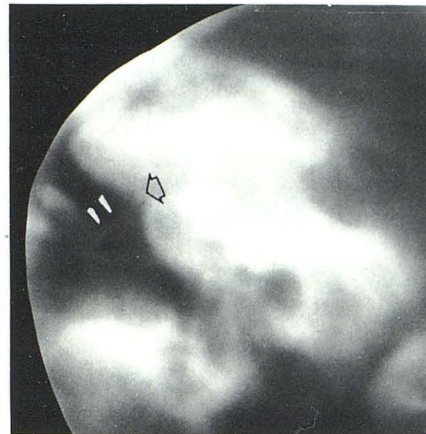
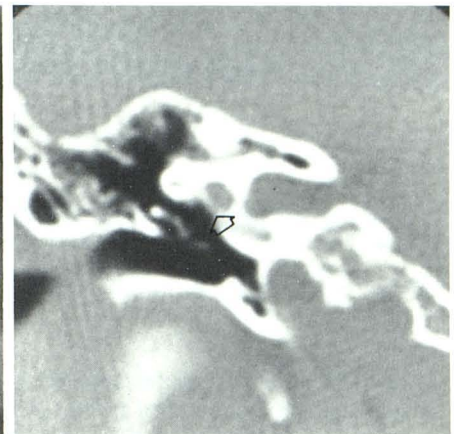
Fig. 7.—McGee piston prosthesis in patent oval window (arrowhead). Hearing in right ear improved after surgery.



A



B

Fig. 8.—A, Wire loop prosthesis placed after stapedectomy. Long limb of prosthesis (arrowheads) in good position. However, because of reclosure of oval window (arrow), there was no improvement in hearing. B, Coronal CT scan, same patient. Reclosure of oval window (arrow). Long limb of prosthesis is again noted.

subtle to avoid detection.

In conclusion, despite the generally higher level of confidence in interpretation, our results with CT showed no greater accuracy than those obtained with complex-motion tomography. We suggest that choice of investigation be determined by availability of equipment and cost of examination. Since radiation damage to the lens of the eye is negligible with proper use of either technique [15], this need not be a determining factor.

ACKNOWLEDGMENTS

We thank Kathy Koch for secretarial assistance and Judy Czerwinski, Lynn Lisinski, Larry Gromowski, and Judy Sivyer for technical assistance.

REFERENCES

1. Shaffer K. Computed tomography of the temporal bone. *Radiographics* **1981**;1:62-72
2. Littleton JT, Shaffer KA, Callahan WP, Durizch ML. Temporal bone: comparison of pluridirectional tomography and high resolution computed tomography. *AJR* **1981**;137:835-845
3. Shaffer KA, Houghton VM, Wilson CR. High resolution computed tomography of the temporal bone. *Radiology* **1980**;134:409-414
4. Mafee M, Kumar A, Yannias DA, Valvassori GE, Applebaum EL. Computed tomography of the middle ear in the evaluation of cholesteatomas and other soft tissue masses: comparison with pluridirectional tomography. *Radiology* **1983**;148:465-472
5. Swartz JD, Goodman RS, Russell KB, Marlowe FI, Wolfson RJ. High resolution computed tomography of the middle ear and mastoid. *Radiology* **1983**;148:455-459
6. Schuknecht HF. Disorders of growth, metabolism and aging. In: *Pathology of the ear*. Cambridge, MA: Harvard, **1974**
7. Compere WE Jr. Radiologic findings in otosclerosis. *Arch Otolaryngol* **1960**;71:150-155
8. Valvassori GE. Otosclerosis. *Otolaryngol Clin North Am* **1973**;6:379-389
9. Valvassori GE. The interpretation of the radiographic findings in cochlear otosclerosis. *Ann Otol Rhinol Laryngol* **1966**;75:572-578
10. Rovsing H. Otosclerosis: fenestral and cochlear. *Radiol Clin North Am* **1974**;12:505-515
11. Valvassori GE, Potter GD, Hanafee WN, Carter BL, Buckingham RA. Otosclerosis and bony dystrophies. In: *Radiology of the ear, nose and throat*. Philadelphia: Saunders, **1982**
12. Zonneveld FW, Van Waes P, Damsma H, et al. Direct multiplanar computed tomography of the petrous bone. *Radiographics* **1983**;3:400-449
13. Viraspongse C, Rothman SLG, Kier EL, Sarwar M. Computed tomographic anatomy of the temporal bone. *AJNR* **1982**;3:379-389, *AJR* **1983**;139:739-749
14. Anson BJ, Donaldson JA. *The surgical anatomy of the temporal bone and ear*. Philadelphia: Saunders, **1967**
15. Chakeres DW, Spiegel PK. A systematic technique for comprehensive evaluation of the temporal bone by computed tomography. *Radiology* **1983**;146:97-106