

Are your MRI contrast agents cost-effective?

Learn more about generic Gadolinium-Based Contrast Agents.



**FRESENIUS
KABI**

caring for life

AJNR

MR Imaging of the Spine after Radiation Therapy: Easily Recognizable Effects

Ruth G. Ramsey and Charles E. Zacharias

AJNR Am J Neuroradiol 1985, 6 (2) 247-251

<http://www.ajnr.org/content/6/2/247>

This information is current as
of April 20, 2024.

MR Imaging of the Spine after Radiation Therapy: Easily Recognizable Effects

Ruth G. Ramsey¹
Charles E. Zacharias¹

Magnetic resonance (MR) imaging of the spine after radiation treatment in four patients demonstrated well defined areas of increased signal intensity in the vertebral bodies on short or T1-weighted sequences. Radiation doses of 4000–5790 rad (40–57.9 Gy) were administered to the mediastinum, rectum, and spine. The interval between radiation treatment and MR imaging was 2 months to 10 years. The abnormally increased areas of signal intensity seen on MR images were best demonstrated in the midsagittal plane and were easily differentiated from involvement by tumor. The alteration in signal intensity probably was secondary to replacement of marrow by fatty tissue and corresponded closely with radiation therapy portals.

Magnetic resonance (MR) imaging of the spine is an excellent method for evaluation of the vertebral column for bony metastases [1–3]. While studying patients with possible bone metastases, it became apparent that there was a typical pattern that is demonstrated in patients who have received previous radiation therapy treatment to the vertebral column. The MR appearance after radiation is that of increased signal intensity of the bone marrow of the vertebral bodies on the T1-weighted 30 msec echo-time (TE) and 530 msec repetition-time (TR) spin-echo (SE) sequences (SE 530/30). On the longer SE sequences, such as SE 2090/90, this change is less apparent. Typically the area of altered signal intensity demonstrates very well defined margins corresponding to the radiation port.

Subjects and Methods

Four patients studied with MR scans demonstrated evidence of alteration in the signal intensity of the vertebral bodies secondary to radiation treatment. The time interval from radiation treatment to MR examination varied from 2 months to 10 years.

Patients with metastatic disease may develop signs and symptoms of vertebral column metastases, and while radiographs of the spine may be normal or abnormal, sometimes radiation treatment to the vertebral column is begun on an empiric basis in symptomatic patients. We began a study of the efficacy of the use of MR in the evaluation of bone metastases to the vertebral column (to be reported separately). During the course of study, it became apparent that patients who had previously received radiation treatment to the vertebral column demonstrated areas of increased signal intensity in the bone marrow of those vertebral bodies included in the treatment port. These areas of increased signal intensity were best demonstrated on SE 530/30 sequences. Four examples are illustrated.

All these patients were examined using the 0.5 T (5 kG) superconductive magnet (Teslacon, Technicare Corp., Solon, OH) with a bore size of 100 cm. The scan slices illustrated are 1 cm in thickness, and were obtained using a 128 × 256 matrix size. All examinations were obtained using two signal averages per slice.

This article appears in the March/April 1985 issue of *AJNR* and the June 1985 issue of *AJR*.

Received September 14, 1984; accepted after revision November 23, 1985.

¹ Department of Diagnostic Radiology, Rush-Presbyterian-St. Luke's Medical Center, 1753 W. Congress Parkway, Chicago, IL 60612. Address reprint requests to R. G. Ramsey.

AJNR 6:247–251, March/April 1985
0195–6108/85/0602–0247
© American Roentgen Ray Society

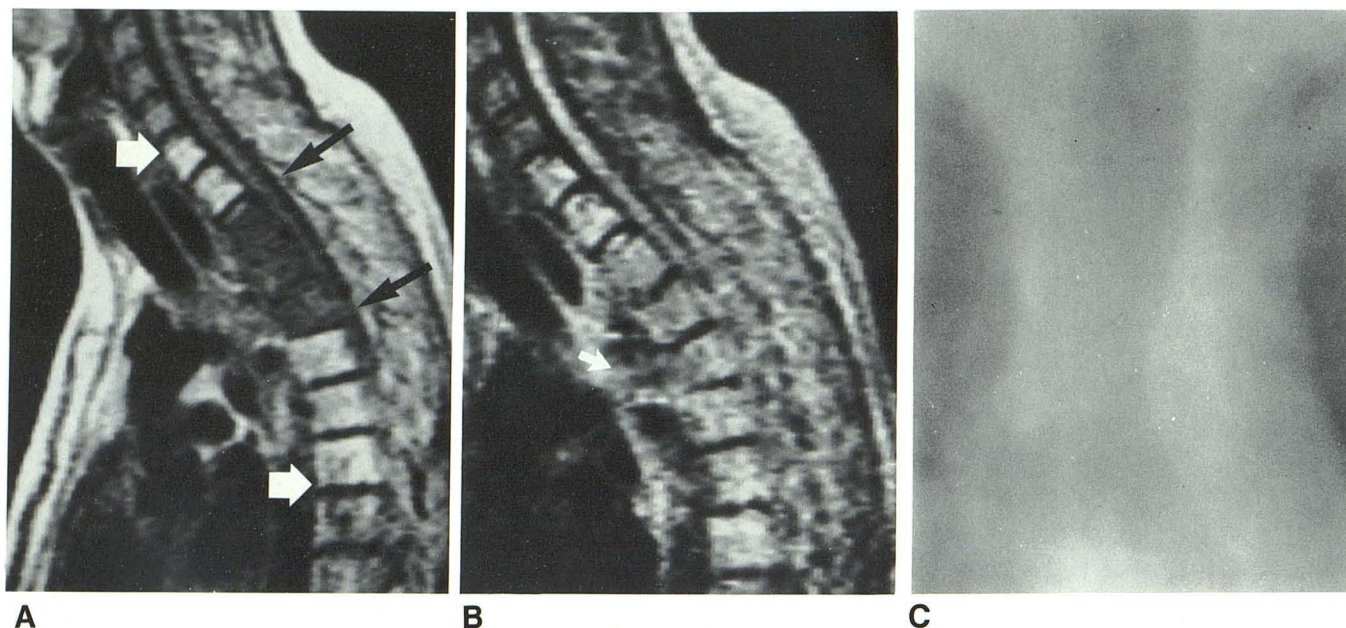


Fig. 1.—Case 1. **A**, SE 530/30 image using two signal averages per slice. Area of increased signal intensity involves C7, T1, and T5–T7 (white arrows). T2–T4 vertebral bodies demonstrate low signal intensity secondary to tumor involvement (black arrows). **B**, SE 2090/90 or T2-weighted image shows pathologic fracture of anterior part of T3 and T4 better. Also, large anterior paraspinal soft-tissue mass is at T3 level (arrow). Esophagus was invaded by

tumor at this level and was well demonstrated on axial section (not shown). Because of slight scoliosis secondary to pathologic fractures of T3 and T4, spinal cord is not demonstrated in its entirety on this 1-cm-thick midsagittal section. **C**, Treatment-port film corresponds to abnormal area of high signal intensity.

Case Reports

Case 1

A 32-year-old man had previous surgery for removal of an undifferentiated tumor (germ cell carcinoma) of the mediastinum. After surgery the patient was treated with 4000 rad (40 Gy) over 20 days to regional lymph nodes and 5000 rad (50 Gy) to the tumor bed. The vertebral column was also included in the treatment port because the tumor could not be totally removed from the paraspinal area at surgery.

The patient did well for about 2 months and then developed severe upper-thoracic-spine pain. MR imaging was performed for evaluation of the presence or absence of bony metastases. The SE 530/30 sequence demonstrated low signal intensity involving T2–T4, secondary to replacement of the fatty bone marrow by tumor tissue. There were pathologic fractures at T3 and T4. In addition, there was well defined increased signal intensity in the vertebral bodies of C7, T1, and T5–T7 (fig. 1A). The area was well demarcated. The SE 2090/90 image demonstrated the pathologic fractures of T3 and T4 to better advantage (fig. 1B). The abnormally increased signal area corresponded precisely to the radiation treatment port (fig. 1C).

Case 2

A 54-year-old man had recurrent carcinoma of the rectum. He was originally treated with near-total surgical removal of carcinoma of the rectum about 5 years before this examination. After his initial surgery, he received 5790 rad (57.9 Gy) to the tumor bed.

He did well until 2 weeks before the examination when he developed increasing pelvic pain; repeat surgery revealed recurrent tumor in the bed of the previous surgical resection. MR demonstrated that the entire sacrum, with the exception of the upper one-fourth of S1,

had abnormally increased signal intensity on the SE 530/30 sequence (fig. 2). The port film was not available, but by history the port corresponded to the abnormal signal area.

Case 3

A 40-year-old man initially had surgery 2 years before this admission for removal of a grade II astrocytoma involving the spinal cord at the level of the conus medullaris. Immediately after the partial surgical removal of the tumor, he received 5000 rad (50 Gy) of radiation treatment to the lower thoracic spinal cord over a 5 week period. The patient did well until about 2 months before this study when progressive right leg weakness and numbness developed.

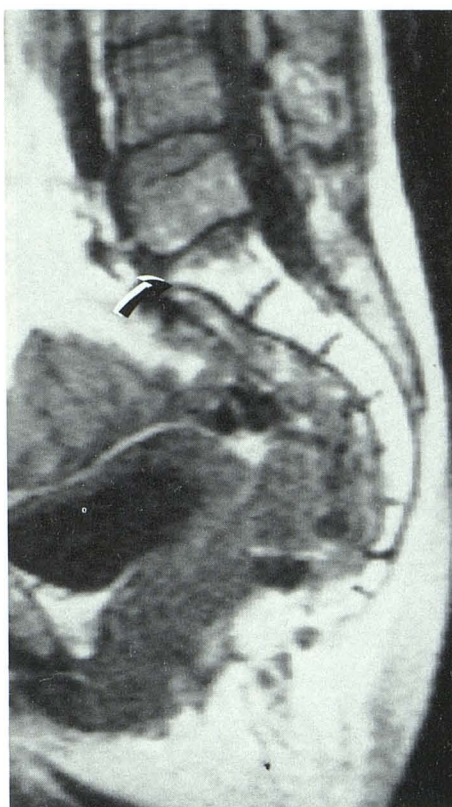
MR demonstrated a very well defined area of increased signal intensity involving T10–L1 on the SE 530/30 sequences (fig. 3A). The well demarcated involvement of the upper one-half of the vertebral body of L1 corresponded exactly to a midsagittal computed tomographic myelogram reconstruction image demonstrating the laminectomy sites (not shown). The port film was unavailable, but by history the laminectomy sites corresponded to the treatment port.

Case 4

A 21-year-old man was treated for testicular carcinoma and received an unknown amount of radiation to the abdominal paraaortic lymph nodes 10 years before this examination. He was disease-free and did well until 2 months before admission when he developed weakness of the legs.

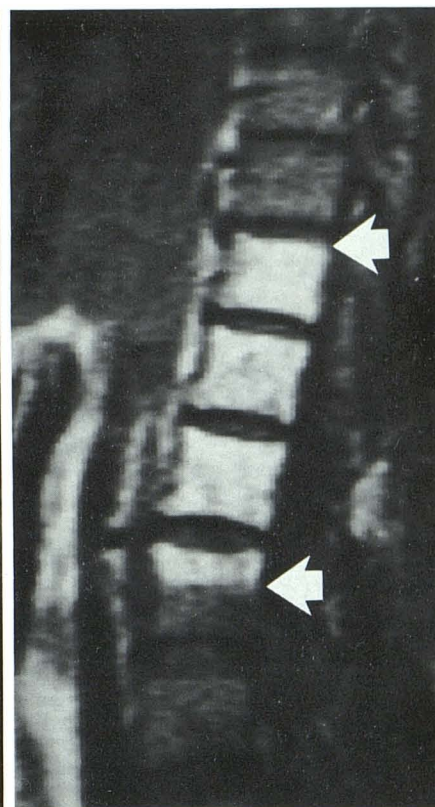
MR of the spine demonstrated the increased signal intensity within the treatment port and also demonstrated the typical deformities of the vertebral bodies seen after radiation treatment. No recurrent tumor was identified on this examination (fig. 4).

Fig. 2.—Case 2. Midsagittal SE 530/30 image. Increased intensity in lower three-fourths of S1 and involving rest of sacrum and coccyx (arrow). This abnormal area corresponds to radiation treatment port.



2

Fig. 3.—Case 3. Midsagittal SE 530/30 image. Increased signal intensity of T10–T12 vertebral bodies and upper one-half of L1 vertebral body. This corresponds to radiation treatment port (arrows). No evidence of recurrent tumor.



3

Discussion

It is well known that radiation treatment depresses the red and white blood cell counts because of depression of the blood-producing bone marrow of the vertebral bodies. After radiation treatment, it appears that there is probably permanent damage to the marrow-containing space within the vertebral body. This has been shown with radionuclide and pathologic studies [5–11]. The MR scan confirms that there is replacement of at least part of the normal bone marrow, with an increase in the high-signal-intensity material, probably adipose tissue, normally demonstrated on the SE 530/30 sequences.

Radionuclide Bone Scanning after Radiation

The response of bone marrow to radiation therapy after treatment of lymphoma and other neoplastic conditions has been described [5, 6]. Local irradiation in the range of 300–4500 rad (3–45 Gy) produces rapid bone-marrow suppression of the irradiated marrow that persists for 1–2 years. Decreases in peripheral blood counts seen routinely after radiation treatment are an unreliable indicator of the extent of bone-marrow activity. Therefore, radionuclide imaging of the marrow space has been used to assess marrow activity. Technetium-99m sulfur colloid is used for imaging of the

reticuloendothelial component of marrow, and ^{52}Fe is used for imaging of the erythropoietic component of the medullary space [5]. These radionuclide studies allow semiquantitative geographic mapping of bone marrow and demonstrate marrow suppression at some sites, expansion at other sites, regeneration of irradiated marrow, and extramedullary hematopoiesis.

Histopathology after Spine Radiation

The histopathologic effect of therapeutic irradiation on bone marrow has been studied both experimentally and in patients receiving radiation therapy. The local bone-marrow effects have been studied in the rat after 2000–10,000 rad (20–100 Gy) with histologic examination from 24 hr to 1 year after irradiation [7]. In another study, 18 patients with breast carcinoma who received postoperative irradiation of the internal mammary lymph nodes on the side of the mastectomy underwent serial bone-marrow biopsies. Sternal bone-marrow aspirates were obtained before therapy, after exposure of 2000 rad (20 Gy), at the end of therapy, and subsequently every 3 months up to 18 months posttreatment. In addition, seven patients who had received intensive local irradiation at least 2 months before death underwent marrow aspiration from five anatomic sites at autopsy [8]. These and other studies [9–11] describe an initial progressive reduction of cellular marrow and its replacement by increased marrow fat.

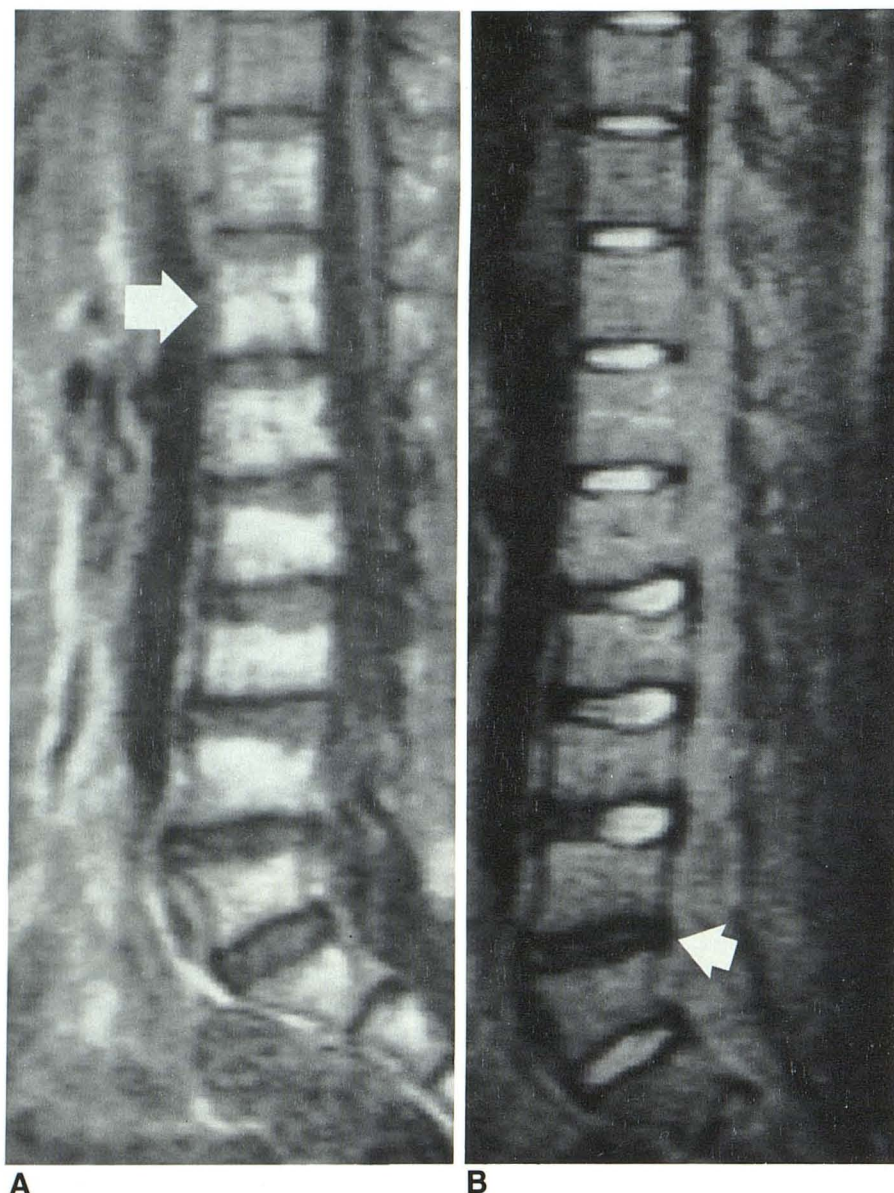


Fig. 4.—Case 4. **A**, Midsagittal SE 530/30 image. Area of increased signal intensity extends from T12 (arrow) through sacrum. Dorsal one-third of T11 also demonstrates abnormal area of increased signal intensity. By history, this corresponds to treatment port. Cerebrospinal fluid has low signal intensity with this spin-echo sequence. **B**, SE 2090/90 image shows postradiation deformity of vertebral bodies better. In addition, relatively low signal from L4–L5 disk (arrow) indicates degenerated disk at this level [4]. Cerebrospinal fluid has high signal intensity with this SE sequence.

MR Imaging

The increase in marrow signal intensity on the T1-weighted, short SE pulse sequences, such as the SE 530/30 images illustrated in our four cases, may be secondary to an absolute increase in the number of adipose cells in the irradiated marrow. The increased signal may also be secondary to a relative increase in signal intensity because of a decrease in the hematopoietic element of the radiated marrow as compared with the lower-signal-intensity nonirradiated marrow.

One might hypothesize that there is a varying response depending on the treatment. However, at this time the lower limit of treatment dose to produce this appearance of increased signal intensity on MR images is unknown. From our present case studies, it appears that this alteration in the normal marrow is apparent as early as 2 months (case 1),

and while the duration of this change is unknown, at least one patient (case 4) demonstrated altered signal intensity 10 years after radiation treatment. This alteration in signal intensity is probably permanent.

Summary

After radiation treatment to the vertebral column, areas of increased signal intensity are readily identified on SE 530/30 sequences and correspond to the treatment port. This increase in signal intensity is presumed to be secondary to replacement of the normal bone marrow by either an absolute or relative increase in the amount of fatty tissue. Previous MR studies have demonstrated that tumor replacement of the marrow results in a relatively low, rather than high, signal

intensity with T1-weighted images as compared with the normal vertebrae [1-3].

In those vertebrae with postradiation alteration of signal intensity, the vertebral bodies are otherwise intact, with well defined cortical margins and without an associated paraspinal soft-tissue mass. It is important to be aware that these well defined abnormal areas of increased signal intensity are secondary to the radiation treatment of the vertebral column rather than to some other pathologic condition.

ACKNOWLEDGMENT

We thank Carol Lee Hanny for help in manuscript preparation.

REFERENCES

1. Han JS, Kaufman B, El Yousef SJ, et al. NMR imaging of the spine. *AJNR* **1983**;4:1151-1159, *AJR* **1983**;141:1137-1145
2. Modic MT, Weinstein MA, Pavlicek W, et al. Nuclear magnetic resonance of the spine. *Radiology* **1983**;148:757-762
3. Norman D, Mills CM, Brant-Zawadzki MB, Yeates A, Crooks LE, Kaufman L. Magnetic resonance imaging of the spinal cord and canal: potentials and limitations. *AJNR* **1984**;5:9-14, *AJR* **1983**;141:1153-1156
4. Chafetz NI, Genant HK, Moon KL, Helms CA, Morris JM. Recognition of lumbar disk herniation with NMR. *AJNR* **1984**;5:23-26, *AJR* **1983**;141:1153-1156
5. Fordham EW, Ali A. Radionuclide imaging of bone marrow. *Semin Hematol* **1981**;18:222-239
6. Bell EG, McAfee JG, Constable WC. Local radiation damage to bone marrow demonstrated by radioisotopic imaging. *Radiology* **1969**;92:1083-1088
7. Knospe WH, Blom J, Crosby WH. Regeneration of locally irradiated bone marrow. I. Dose dependent, long-term changes in the rat with particular emphasis upon vascular and stromal reaction. *Blood* **1966**;28:398-415
8. Sykes MP, Chu FCH, Wilkerson WG. Local bone marrow changes secondary to therapeutic irradiation. *Radiology* **1960**;75:919-924
9. Hill DR, Benak SB, Phillips TL, Price DC. Bone marrow regeneration following fractionated radiation therapy. *Int J Radiat Oncol Biol Phys* **1980**;6:1149-1155
10. Rubin P, Landman S, Mayer E, Keller B, Ciccio S. Bone marrow regeneration and extension after extended field irradiation in Hodgkin's disease. *Cancer* **1973**;32:699-716
11. Sacks EL, Goris ML, Glatstein E, Gilbert E, Kaplan HS. Bone marrow regeneration following large field radiation. Influence of volume, age, dose and time. *Cancer* **1978**;42:1057-1065