AJNR

Uncovertebral and facet joint dislocations in cervical articular pillar fractures: CT evaluation.

Z Yetkin, A G Osborn, D S Giles and V M Haughton

AJNR Am J Neuroradiol 1985, 6 (4) 633-637
http://www.ajnr.org/content/6/4/633

Uncovertebral and Facet Joint Dislocations in Cervical Articular Pillar Fractures:

CT Evaluation

Zerrin Yetkin[1,2]
Anne G. Osborn[3]
David S. Giles[4]
Victor M. Haughton[1]

Computed tomographic (CT) scans and plain radiographs of 21 patients with surgically treated fractures or dislocations of the cervical spine were reviewed. CT effectively demonstrated the locked or perched facets and half of the 13 articular pillar fractures. The fracture lines through the articular pillar were difficult to detect in some cases or to distinguish from a facet joint in others. However, distraction of an adjacent uncovertebral or facet joint was demonstrated by CT in each case of articular pillar fracture or locked or perched facet. Therefore, CT demonstration of a distracted facet or uncovertebral joint is an indirect sign of an unstable fracture or of a dislocation that may be more readily recognized on plain radiographs or pluridirectional tomograms.

Not all fractures of the cervical spine are effectively demonstrated by plain radiographs. Therefore, either pluridirectional tomography or, more recently, computed tomography (CT) [1–3] has been used to supplement the plain radiographs in the evaluation of cervical trauma. Cervical articular pillar fractures, especially those in the horizontal plane, are not effectively demonstrated by routine axial CT images. Therefore, in some cases of cervical spinal trauma, additional studies may be needed to document fractures after CT and plain radiography have been performed. We reviewed our recent experience with CT in cervical articular pillar (lateral mass) fractures and dislocations to characterize the cases in which CT imperfectly demonstrates the fracture lines and to identify signs that might indicate the presence of fractures and suggest additional studies.

Materials and Methods

Discharge diagnoses of neurosurgical patients were reviewed to identify persons treated surgically for cervical spinal fractures and dislocations. The diagnoses were based on the surgical, radiographic, and CT findings. Twenty-one patients investigated by CT with fractures or dislocations of the articular pillars were included in the study. The 21 cases comprised 13 cases of articular pillar fractures with or without facet joint subluxations and eight cases of facet joint dislocations without articular pillar fracture.

CT scans were performed on General Electric CT/T 8800 or CT/T 9800 or Siemens Somatom DR2S scanners. Images were obtained with 1.5-, 3-, or 5-mm-thick cuts using 120 kVp and 320–1150 mAs. If the purpose of the scan was to examine the soft tissues, relatively high-milliamperage techniques were used, often with intrathecal metrizamide. If only osseous detail was required, low milliamperage was used and thin slices were obtained.

All cases had either reformatted images in parasagittal, coronal, or oblique planes or lateral and frontal pluridirectional tomography. Each CT study was reviewed to identify potentially misdiagnosed or overlooked fractures or subluxations.

Results

Of the 13 cases of fractured lateral masses, axial CT images effectively demonstrated the fracture lines, fractured bone segments, or misalignment in seven (figs.

Received July 25, 1984; accepted after revision December 2, 1984.

[1] Department of Radiology, Medical College of Wisconsin, Froedtert Memorial Lutheran Hospital, 9200 W. Wisconsin Ave., Milwaukee, WI 53226. Address reprint requests to V. M. Haughton.

[2] Present address: 556 Sok., No. 2-9, Bornova, 12 Mir, Turkey.

[3] Department of Radiology, University of Utah Medical Center, Salt Lake City, UT 84132.

[4] Department of Radiology, St. Alphonsus Hospital, Boise, ID 83706.

AJNR 6:633–637, July/August 1985
0195–6108/85/0604–0633

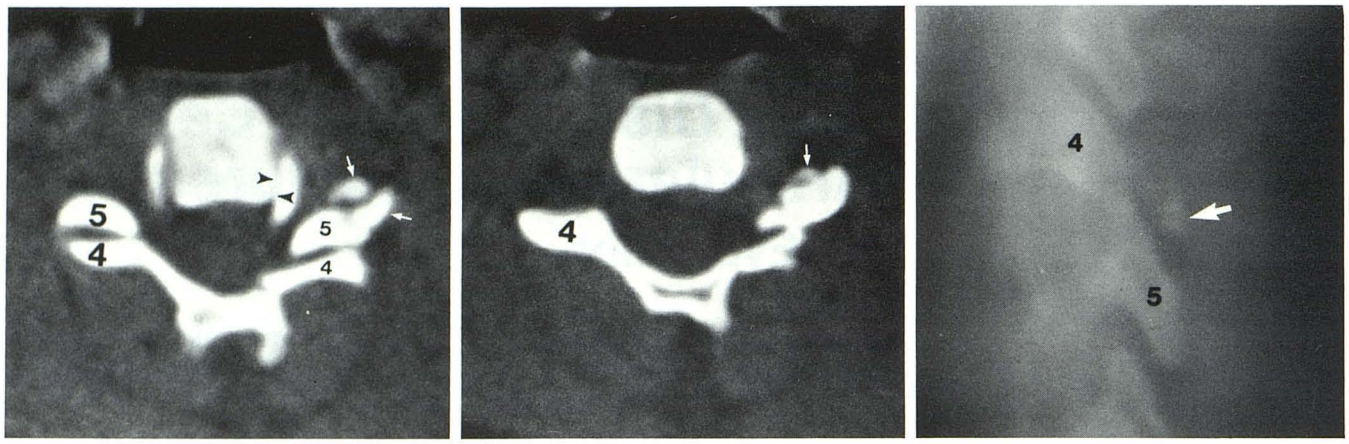

Fig. 1.—Comminuted fracture of left C4 articular pillar. CT scan (**A**) shows fracture fragments (*arrows*) of C4 pillar anterior to superior articular process (5) and abnormal alignment of left uncovertebral joints (*arrowheads*). A higher cut (**B**) demonstrates fragments (*arrow*) of C4 pillar above superior facet. A laminar fracture is also present. Parasagittal pluridirectional tomogram (**C**) shows fracture fragment (*arrow*) separated from fourth articular pillar (4).

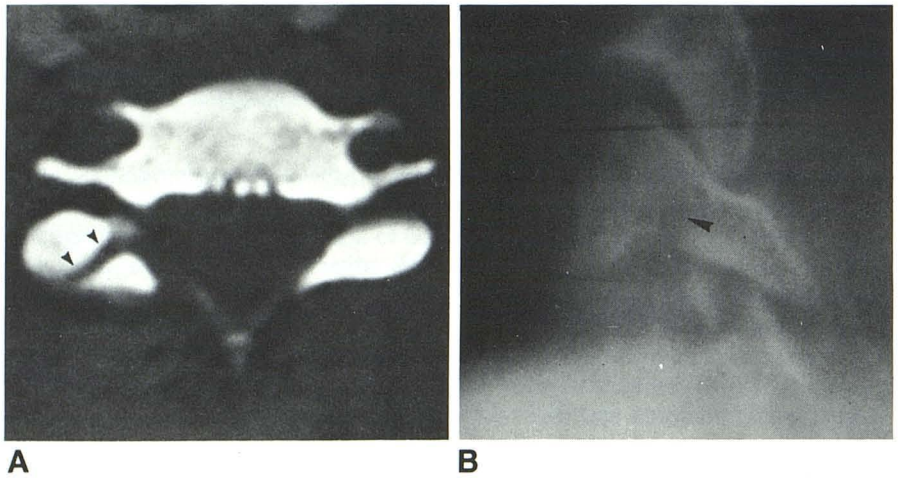

Fig. 2.—Articular pillar fracture. CT scan (**A**) shows fracture line (*arrowheads*), which should not be misinterpreted as a joint. Pluridirectional tomogram (**B**) confirms fracture (*arrowhead*).

1 and 2). The axial CT findings for the other six cases were less specific. In five cases, CT showed fracture lines in lateral masses that superficially resembled a normal or distracted facet joint space (figs. 3–5). In two other cases, comminuted fracture fragments simulated locked facets (fig. 6). In one of these cases the lateral mass was fractured in such a way that the inferior articular facet was located anterior to the superior articular facet. In the other case, one axial image showed a half-moon-shaped fracture fragment posterior to the inferior articular facet, suggesting a locked facet. On contiguous images the irregular contour of this fragment distinguished it from the superior articular facet.

All 13 cases of articular pillar fractures had CT evidence of uncovertebral or facet joint subluxation. Four had associated perched facets, two had locked facets, and five had distracted facets, often bilaterally and usually at multiple levels. Some cases had a combination of distracted, dislocated, and/or locked facets. Ten of 13 cases also showed CT evidence of uncovertebral joint subluxation at the level of the fracture, indicating rotation of the transverse axis of one vertebral body with respect to the adjacent one (fig. 7).

The eight cases of facet joint dislocations without articular pillar fracture comprised three with locked facets, three with perched facets, and two with distracted facets. Axial CT findings in the three cases of locked facets were diagnostic. The articular processes, recognized by their half-moon shape, were in reverse relation. In all cases the superior articular facets posterior to the inferior facet created a flat posterior contour. Two of the three cases had associated facet joint abnormalities, including perched or distracted facet joints, for a total of five abnormal joints. Uncovertebral distraction was present in all cases, although it was obscured in one by a compression fracture and in another by severe spondylolisthesis.

Perching of facets without fracture was observed unilaterally in one case and bilaterally in another. These two cases

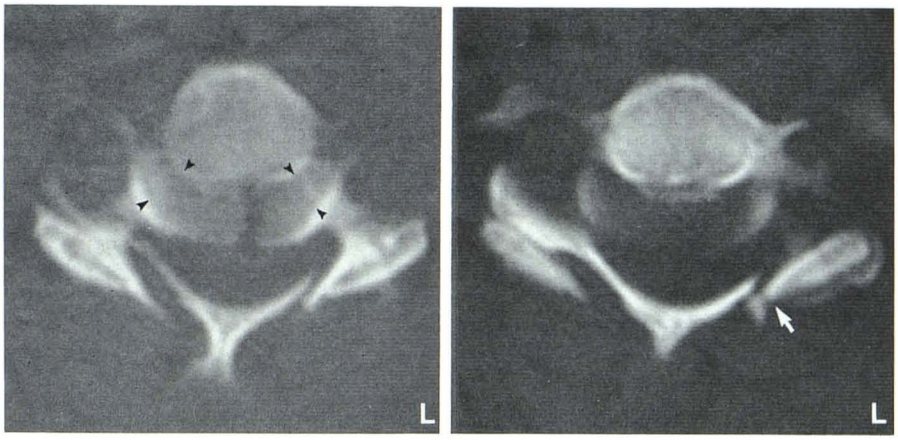

Fig. 3.—CT images in case with locked facet on right and articular pillar fracture on left. Fracture and dislocation are not readily identified, although fracture line is shown (*arrow*). Severe bilateral subluxation of C5–C6 uncovertebral joints (*arrowheads*) indicates that both articular pillars have been traumatized.

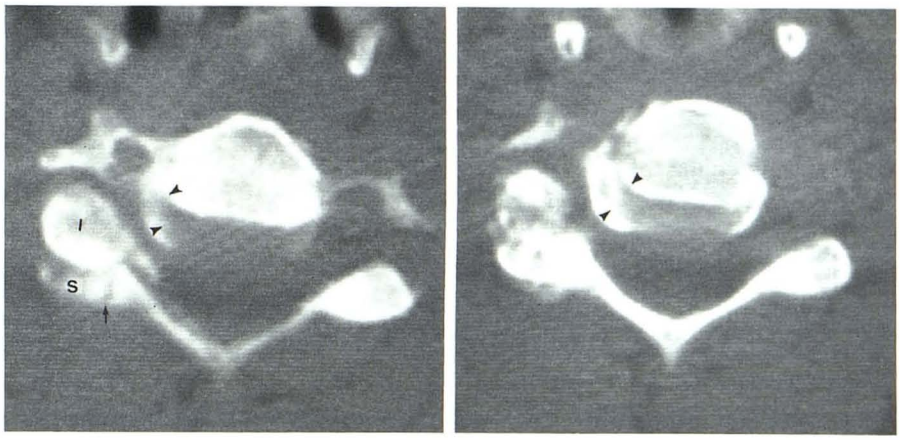

Fig. 4.—Contiguous CT sections in case with locked facet and fractured articular pillar on right. Fracture lines in articular pillar (*arrow*), abnormally aligned superior (S) and inferior (I) articular facets, and distracted uncovertebral joint (*arrowheads*).

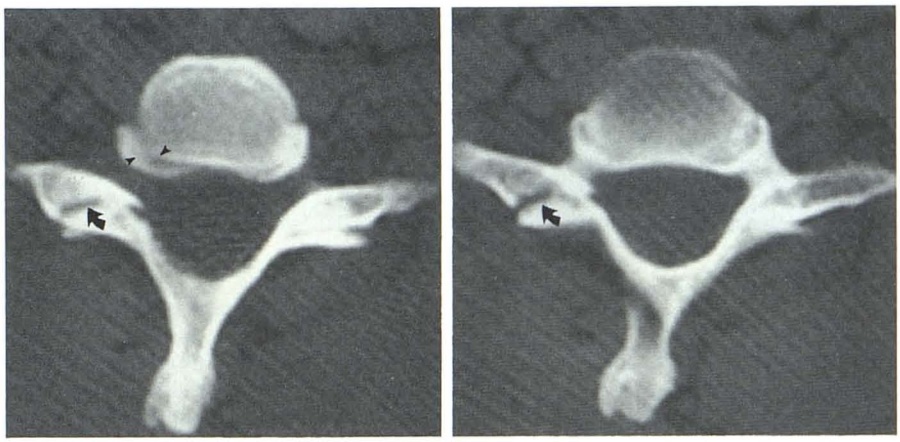

Fig. 5.—Consecutive CT sections through articular pillar fracture. Fracture line (*arrow*) could be misinterpreted as a joint, especially if lower-resolution images were obtained. Slight uncovertebral joint subluxation (*arrowheads*).

and those associated with facet fractures and lock had a characteristic CT appearance (fig. 8). On axial CT images, the half-moon-shaped superior articular facets with a flat posterior surface were seen on a higher slice than the inferior articular facets (the bare or "naked" facet sign). In all cases the lateral mass on the side of the perched facet appeared thinner than the contralateral mass, and uncovertebral joint distraction was evident at an adjacent level.

In two cases, distraction of the facets was seen without associated lateral mass fracture or dislocation (fig. 9). One case had comminuted fractures of the vertebral body and laminae above the bilateral distracted facets; the other case

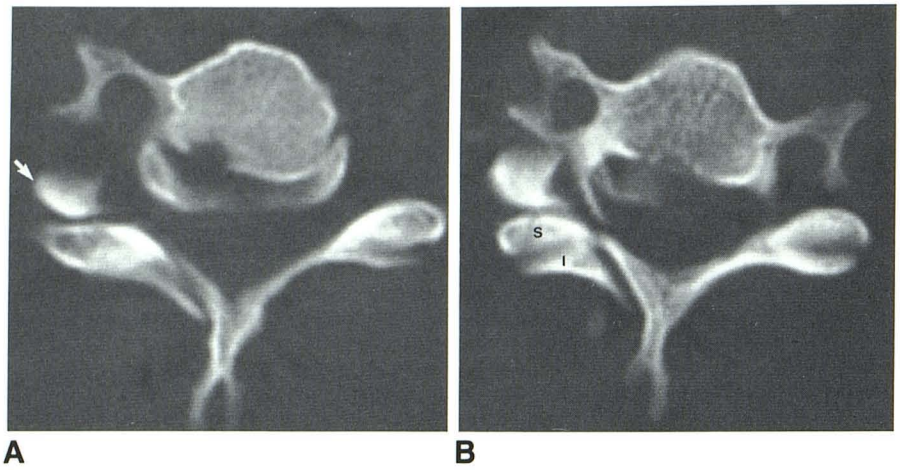

Fig. 6.—Comminuted right articular pillar fracture. CT scans. Fracture fragment (**A**, *arrow*) in front of facet joint suggests locked facet. Fragments and articular processes (S, I) are shown better in slightly higher cut (**B**).

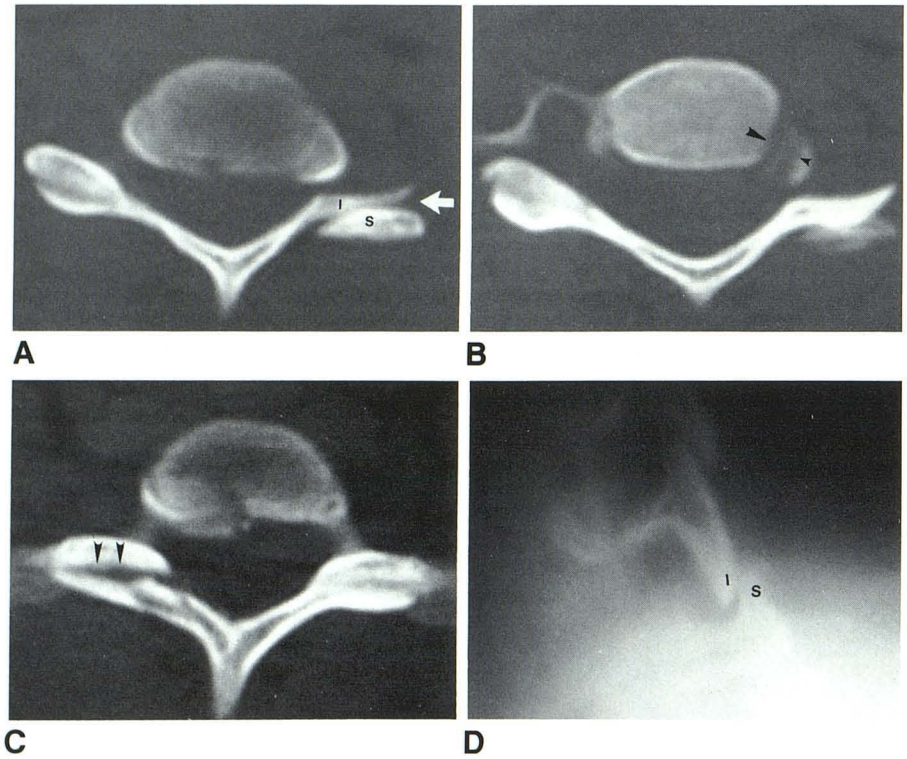

Fig. 7.—Locked facet (**A**, *arrow*). CT scans show abnormal relation of superior and inferior articular processes (**A**, S and I, respectively) and subluxed uncovertebral joint (**B**, *arrowheads*). Section through next lower disk level shows mildly distracted facet joint (**C**, *arrowheads*). Pluridirectional tomogram (**D**) confirmed locking of inferior articular process in front of superior articular process.

had fractured pedicles. In these two cases and in those associated with fractured or subluxed articular pillars, CT showed a larger space between the fracture fragments than is normally present between the articular facets.

Discussion

The optimal radiographic protocol for investigating cervical trauma has been studied by others [1–5] and was not the objective of this investigation. Therefore, the sensitivity of plain films, CT, reformatted CT images, pluridirectional tomography, or thick versus thin cuts was not calculated. Our purpose was to determine which cervical fractures or dislocations are likely to be missed on axial CT images. The inaccurate localization and detection of some fractures by CT has been mentioned but not sufficiently emphasized [4, 6, 7]. Therefore, the CT studies in a series of fractures that had been verified either radiographically or surgically were reviewed to identify cases in which CT did not definitely demonstrate the fractures. In these cases ancillary signs of unstable fractures were sought.

Review of these 21 cases suggests that recognition of facet joint spaces or uncovertebral joint misalignment will help

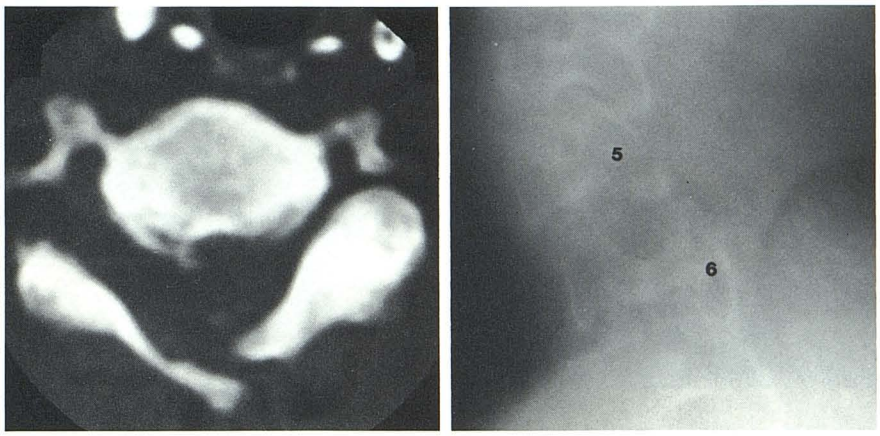

A B

Fig. 8.—Perched right facet joint. In axial CT image (**A**), narrow dimension and flat anterior surface of right articular pillar are signs of subluxation. Tomogram (**B**) shows abnormal relation of inferior articular process of C5 and superior articular process of C6.

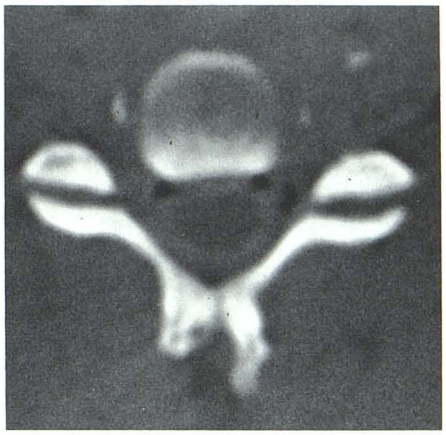

Fig. 9.—CT scan in case of bilateral distracted C5–C6 facet joints without articular pillar fracture. Pluridirectional tomogram (not shown) confirmed distraction and demonstrated no fracture.

to identify cervical pillar fractures or subluxations and suggest further radiographic evaluation. The presence of distracted facets strongly suggests a fracture or locked facet at an adjacent level. Uncovertebral joint subluxation, reflecting rotation of the vertebral body, usually indicates fracture or dislocation at the same level. The possibility that an articular pillar fracture may simulate a widened facet joint should also be recognized. The cases with bilateral facet joint fractures or dislocations had bilateral uncovertebral joint abnormalities even though they lacked a rotatory subluxation. Further evaluation is needed if axial CT scans show uncovertebral or facet joint abnormalities but no fracture line. Oblique reformatted images may aid in distinguishing fractures from joints.

Perched facets were not easily identified on axial CT images. Asymmetry of the articular pillars and distraction of the uncovertebral joints were indications of perched facet joints. Perched facets [8] were often indicative of associated fractures or dislocation, usually contralaterally, at the same level. Any asymmetry of the lateral masses on a CT scan suggests that plain radiographs, reformatted images, or tomograms should be inspected to exclude a perched facet or articular pillar fracture.

Locked facets usually had a characteristic CT appearance on axial CT scans or plain films ("back-to-back half moons" sign) [9]. Definitive diagnosis could be made without pluridirectional tomography or reformatted images.

In patients with cervical spinal trauma, the uncovertebral and facet joints should be studied carefully in CT images to detect potentially unstable fractures and dislocations.

REFERENCES

1. Keene JS, Goletz TH, Lilleas F, Alter AJ, Sackett JF. Diagnosis of vertebral fractures. A comparison of conventional radiography, conventional tomography and computed axial tomography. *J Bone Joint Surg [Am]* **1982**;64:586–594
2. Handel SF, Lee YY. Computed tomography of spinal fractures. *Radiol Clin North Am* **1981**;19:69–89
3. Post MJD, Green BA,, Quencer RM, Stokes NA, Callahan RA, Eismont FJ. The value of computed tomography in spinal trauma. *Spine* **1982**;7:417–431
4. Brant-Zawadzki M, Miller EM, Federle MP. CT in the evaluation of spine trauma. *AJR* **1981**;136:369–375
5. Naidich TP, Pudlowski RM, Moran CJ, Gilula LA, Murphy W, Naidich JB. Computed tomography of spinal fractures. *Adv Neurol* **1979**;22:207–253
6. Cacayorin ED, Kieffer SA. Applications and limitations of computed tomography of the spine. *Radiol Clin North Am* **1982**;20:185–206
7. Faerber EN, Wolpert SM, Scott RM, Belkin SC, Carter BL. Computed tomography of spinal fractures. *J Comput Assist Tomogr* **1979**;3:657–661
8. O'Callaghan JP, Ullrich CG, Yuan HA, Kieffer SA. CT of facet distraction in flexion injuries of the thoracolumbar spine: the "naked" facet *AJNR* **1980**;1:97–102, *AJR* **1980**;134:563–568
9. Woodring JH, Goldstein SJ. Fractures of the articular processes of the cervical spine. *AJNR* **1982**;3:239–242, *AJR* **1982**; 139:341–344