

Are your **MRI contrast agents** cost-effective?

Learn more about generic **Gadolinium-Based Contrast Agents**.



FRESENIUS
KABI

caring for life

AJNR

**CT-surgical correlation in pituitary adenomas:
evaluation in 113 patients.**

P C Davis, J C Hoffman, Jr, G T Tindall and I F Braun

AJNR Am J Neuroradiol 1985, 6 (5) 711-716

<http://www.ajnr.org/content/6/5/711>

This information is current as
of April 17, 2024.

CT-Surgical Correlation in Pituitary Adenomas: Evaluation in 113 Patients

Patricia C. Davis¹
 James C. Hoffman, Jr.¹
 George T. Tindall²
 Ira F. Braun¹

A retrospective study was undertaken in 113 patients with surgically proven pituitary adenomas to correlate the frequency, type, and location of computed tomographic (CT) abnormalities with surgical findings. There were 63 prolactin-secreting, 19 growth-hormone-secreting, 12 adrenocorticotropic-hormone-secreting, two thyroid-stimulating-hormone-secreting, and 17 nonfunctioning adenomas. The 51 functioning and nonfunctioning macroadenomas had similar CT appearances. Only 34 secretory adenomas presented as discrete, focal, hypodense lesions; the rest were isodense with the adjacent pituitary gland. Secretory adenomas were clinically apparent earlier, and accordingly the abnormalities seen on CT were less developed. The location of the normal pituitary gland could not be determined by attenuation characteristics; only by infundibulum displacement or opposite to a discrete, focal, hypodense lesion could the gland location be predicted reliably. Adenomas with hemorrhage, infarction, and cyst formation were indistinguishable from those without these findings. CT was helpful in identifying the mass effect of macroadenomas; however, in microadenomas of all types CT abnormalities were uncommon. Thus, the diagnostic evaluation of the patient suspected of harboring a pituitary adenoma, particularly a microadenoma, must remain a joint effort based on clinical, radiographic, and endocrinologic data.

Computed tomography (CT) is currently the accepted radiographic technique for evaluation of the patient with a suspected pituitary adenoma and has replaced pluridirectional tomography, pneumoencephalography, and most angiographic studies in the neurodiagnostic examination of these patients. CT is useful in localizing the lesion and in evaluating suprasellar or parasellar extent [1-7]. Many reports describe the enhancement characteristics of adenomas as a whole [1-15]; however, few large series have been reported of surgically proven adenomas with high-resolution CT correlation [1, 2, 8, 9]. In an effort to distinguish between adenoma types and to localize the normal pituitary gland, we evaluated retrospectively the CT findings in 113 patients with verified pituitary adenomas who underwent transsphenoidal surgery.

Materials and Methods

We retrospectively studied all patients who underwent transsphenoidal surgery for pituitary adenoma and who had had direct coronal CT scans at our institution. Patients with axial images only, nondiagnostic scans, and those with prior surgery were excluded. Patients were offered surgery based on CT, endocrinologic, and clinical findings. No group was systematically excluded from surgery, although some patients elected medical rather than surgical therapy. Data from 39 prolactin (PRL)-secreting microadenomas reported elsewhere [16] are included. One patient who had a nonfunctioning adenoma and who was treated for 6 weeks preoperatively with Bromocriptine (7.5 mg daily dose) and one who had received previous radiation therapy (10 years before) were included in this series.

CT scans were obtained in either a prone or supine (usually prone) direct coronal position with a 9.6 sec scan time, 120 kVp, and at least 400 mA (G.E. CT/T 8800). Sequential 1.5 mm collimation images were obtained in all except the very largest tumors; in these 5 mm

Received October 12, 1984; accepted after revision January 22, 1985.

¹Department of Radiology, Section of Neuro-radiology, Emory University School of Medicine, 1365 Clifton Rd., N.E., Atlanta, GA 30322. Address reprint requests to P. C. Davis.

²Department of Neurosurgery, Emory University School of Medicine, Atlanta, GA 30322.

AJNR 6:711-716, September/October 1985
 0195-6108/85/0605-0711

© American Roentgen Ray Society

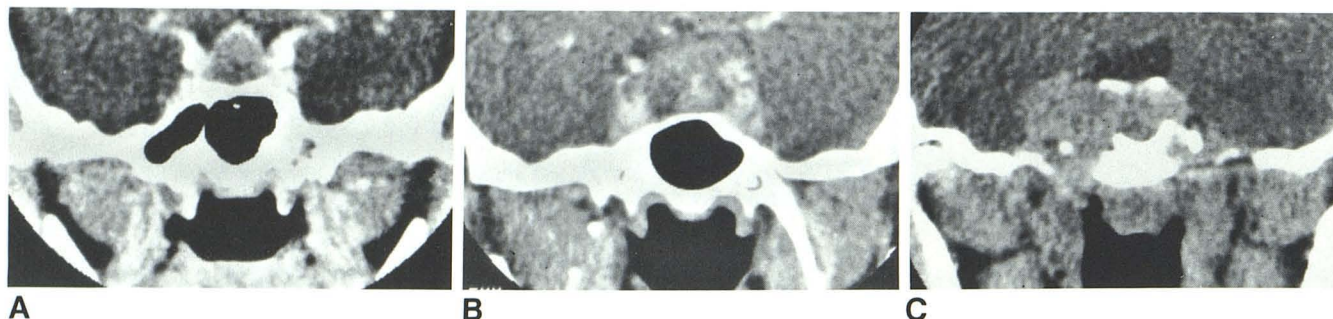


Fig. 1.—Macroadenomas were classified by enhancement pattern relative to adjacent cavernous sinus. A, Uniformly hypodense GH macroadenoma. B, Mixed-density nonfunctioning macroadenoma. C, Isodense PRL macroadenoma with enlargement and bowing outward of adjacent cavernous sinus.

TABLE 1: CT Abnormalities in Patients with Pituitary Adenomas

CT Abnormality	Type of Adenoma					Total
	PRL	GH	ACTH	TSH	Nonfunctioning	
Microadenomas:						
Total no.	45	8	9	0	0	62
Focal lesions	23	4	2	0	0	29
Infundibulum displacement	7	2	2	0	0	11
Focal convexity of diaphragma sellae	12	3	3	0	0	18
Sellar floor erosion	23	2	2	0	0	27
Supraclinoid mass	0	1	1	0	0	2
Gland height >10 mm	1	1	0	0	0	2
Macroadenomas:						
Total no.	18	11	2	3	17	51
Focal lesions	4	1	0	0	0	5
Infundibulum displacement	7	1	0	2	0	10
Infundibulum not imaged	7	3	3	0	17	30
Focal convexity of diaphragma sellae	2	1	0	0	0	3
Sellar floor erosion	13	5	2	1	16	37
Supraclinoid mass	12	9	3	2	16	42
Invasion of cavernous sinus	3	3	1	0	4	11
Invasion of sphenoid sinus	4	2	0	0	4	10

Note.—Adenomas are prolactin (PRL)-secreting, growth-hormone (GRL)-secreting, adrenocorticotrophic-hormone (ACTH)-secreting, and thyroid-stimulating-hormone (TSH)-secreting.

collimation was used. Studies were completed immediately after a 100 ml intravenous bolus of contrast material (28.2 g) was administered, followed by drip infusion during the study (42.3 g).

CT studies were initially interpreted blindly without knowledge of laboratory, surgical, or pathologic findings. The gland height was measured as the maximum height of intrasellar contents [17]. The diaphragma sellae was described as generally convex, focally convex, flat, or concave. For correlative purposes, generally convex, flat, and concave were considered normal [17, 18]. Cavernous sinus invasion was suspected when its margins were significantly bowed or displaced laterally [19]. Sellar floor erosion was conservatively described due to the recognized variations in sellar floor thickness and sphenoid sinus aeration in normal patients [20–23]. A focal lesion was a discrete, identifiable mass different in attenuation characteristics from the surrounding pituitary gland and of measurable size. In the absence of a discrete focal lesion, the enhancement patterns of the macroadenomas were classified relative to the cavernous sinus as uniformly iso- or hypodense or of mixed density (fig. 1). The infundibulum position was described as right, left, midline, or indeterminate. CT scans with mass extending above the level of the anterior or posterior clinoids were said to have supraclinoid extension of tumor. Sphenoid invasion was described when the sellar floor was grossly destroyed

and tumor extended into the sphenoid sinus. After the blinded correlation was completed, an attempt was made to identify the normal pituitary gland apart from the adenoma on the basis of the surgical description of the gland location.

All the transsphenoidal surgical procedures were performed by the same neurosurgeon (G. T. T). Particular note was made of the size and exact location of the adenoma in the sella. Those larger than 10 mm were categorized as macroadenomas; those less than or equal to 10 mm as microadenomas.

Histologic examination was performed on all specimens. An excessive proliferation of one benign cell type with disruption of the normal acinar pattern of the pituitary gland was identified as an adenoma [24–26].

Results

PRL-Secreting Adenomas

Sixty-three patients with proven PRL adenomas were studied. Forty-five microadenomas occurred in 44 women and one man aged 18–60 years; there were 18 macroadenomas in six men and 12 women aged 18–68 years (mean, 39 years).

Symptoms in women included amenorrhea, galactorrhea, headaches, visual changes, absence of menarche, infertility, hair loss, decreased libido, weight gain, and diabetes insipidus (one case). In men, symptoms were hypogonadism, decreased libido, galactorrhea, visual changes, headaches, weakness, and a history of multiple endocrine adenomatosis I syndrome (one case).

All patients had histologic diagnosis of adenoma; of these, two adenomas had foci of infarction, two had cyst formation, five had foci of subacute or old hemorrhage, and five contained calcospherites. One was histologically invasive without frank malignancy or abnormal mitoses. The mean PRL level in microadenoma patients was 235 ng/ml (range, 25–700 ng/ml), and in macroadenomas, 1251 ng/ml (range, 41–8650 ng/ml). Normal PRL levels in our laboratory are <20 ng/ml.

CT findings are shown in table 1. In PRL microadenomas, the most commonly encountered CT abnormalities were focal lesions (51%) and sellar floor erosion (51%). Focal lesions correlated well with the microadenoma site; however, sellar floor erosion had only a fair correlation (69%) with surgical localization of the adenoma. Only one PRL microadenoma resulted in a gland height of >10 mm. Conversely, in PRL macroadenomas, discrete focal lesions were relatively uncommon (22%). Displacement and nondemonstration of the infundibulum were encountered often, as were sellar floor erosion and supraclinoid extension of the mass. Enhancement characteristics in the macroadenomas were variable with uniformly isodense (33%), uniformly hypodense (50%), and mixed-density lesions (22%) encountered relative to the adjacent cavernous sinus.

Growth Hormone (GH)-Secreting Adenomas

Nineteen patients had GH-secreting adenomas. There were six males and 13 females aged 9–68 years (mean, 40 years). All had symptoms, which included enlarged hands and feet, coarse facies, protuberant jaw, diplopia, headaches, carpal tunnel syndrome, infertility, hypertension, diabetes mellitus, and arthritis. Mean GH levels (normal, <5.0 ng/ml) were 12.6 ng/ml in microadenomas (range, 4.4–20.9 ng/ml) and 56.3 ng/ml in macroadenomas (range, 5.5–135 ng/ml). Four patients also had mildly elevated PRL levels (30–112 ng/ml). All patients had a histologic diagnosis of adenoma; one adenoma had calcospherites, one was histologically invasive, and one contained foci of hemorrhage.

In the microadenomas, focal lesions were encountered by CT in only half the patients. Only one microadenoma resulted in a gland height >10 mm. Other CT abnormalities were uncommon (table 1).

In the macroadenomas, a convex diaphragma sellae and supraclinoid extent of mass were encountered often. Enhancement patterns were variable: four isodense, five hypodense, and two mixed-density adenomas were identified.

Adrenocorticotrophic-Hormone (ACTH)-Secreting Adenomas

The 12 patients with ACTH-secreting adenomas comprised three men and nine women aged 26–67 years (mean, 41 years). Symptoms included weight gain, hirsutism, diabetes

mellitus, hypertension, edema, decreased libido, amenorrhea, round facies, acne, nausea and vomiting, and weakness. Seven patients had elevated ACTH values (normal, 0–130 pg/ml); in the microadenoma group the mean ACTH was 145 pg/ml (range, 82–230 pg/ml) and in the macroadenoma group the mean was 268 pg/ml (range, 216–320 pg/ml). Patients with normal ACTH values and those without measured ACTH values had abnormalities of other endocrinologic tests including a.m. or p.m. cortisol, urine 17-hydroxycorticosteroids, and urine 17-ketosteroids. These patients also had dexamethasone suppression and metyrapone testings with results considered consistent with Cushing disease (i.e., pituitary source).

Histologic diagnosis confirmed adenoma in all cases. No foci of hemorrhage, infarction, invasion, or calcospherites were identified.

By CT, focal lesions were uncommon in the ACTH microadenomas, as were all CT abnormalities (table 1). No ACTH-secreting microadenomas resulted in a gland height >10 mm. Macroadenomas were indistinguishable by enhancement patterns (two hypodense, one mixed density) or other CT abnormalities from other secretory or nonsecretory lesions.

Thyroid-Stimulating-Hormone (TSH)-Secreting Adenomas

Only two TSH-secreting macroadenomas were identified (one man, aged 21; one woman, aged 35). No TSH-secreting microadenomas were encountered. Symptoms were those of hyperthyroidism. TSH levels were 20 and 169 μ IU/ml (normal, 0–8 μ IU/ml). Histologically, both had proven adenomas with no identifiable calcospherites, infarction, invasion, or hemorrhage. By CT (table 1), both patients had an increased gland height and a generally convex diaphragma sellae. No focal lesions or cavernous-sinus/sphenoid-sinus invasion were identified. Both patients had displaced infundibula; however, only one harbored a nonmidline adenoma. Both patients had uniform hypodensity of intrasellar contents on CT.

Nonfunctioning Adenomas

The 17 patients with nonfunctioning adenomas comprised four men and 13 women 21–71 years (mean, 49.4 years). Symptoms included decreased vision, visual field defects, headaches, panhypopituitarism, impotence, hypothyroidism, malaise, fatigue, and hydrocephalus (one patient). Laboratory results were variable including decreased or mildly increased levels of PRL [27, 28], follicle-stimulating hormone, luteinizing hormone, GH, and TSH.

Histologically all had proven adenomas; of these two adenomas contained foci of hemorrhage and one contained a cyst. No histologically invasive or calcified lesions were encountered.

No microadenomas were encountered by CT in this group. Seventeen macroadenomas were identified. The greatest average gland height occurred in this group (mean, 26 mm; range 15–40 mm). Other CT abnormalities reflected the size of these lesions at presentation, that is, abnormalities of the diaphragma sellae, sellar floor erosion, supraclinoid mass, and obliteration of the pituitary infundibulum (table 1). En-

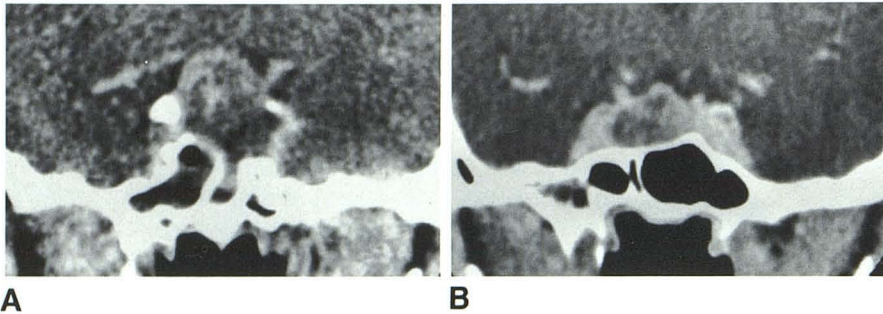


Fig. 2.—Macroadenomas with (A) and without (B) foci of old hemorrhage and infarct were radiographically similar.

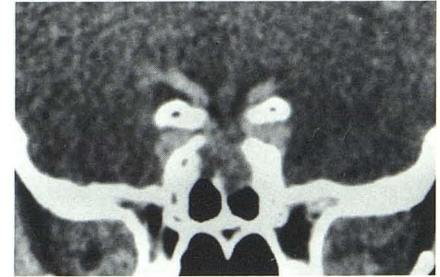


Fig. 3.—Sphenoid sinus extent of macroadenoma did not necessarily correlate with adenoma size, as in this PRL macroadenoma with complete absence of sellar floor despite concave diaphragma sellae and no suprasellar extension.

enhancement patterns included four uniformly hypodense, seven uniformly isodense, and six mixed-density adenomas.

A retrospective attempt was made to identify the normal pituitary gland in micro- and macroadenomas based on the surgical description of gland site. The normal gland could only be identified in the presence of infundibulum displacement and/or identification of a discrete focal lesion. No identifiable difference in attenuation characteristics was useful in distinguishing the normal pituitary gland from adenoma in the uniformly isodense, uniformly hypodense, or mixed categories of enhancement. Likewise, the enhancement pattern failed to correlate with presence of old hemorrhage, cyst, or infarction. Thus, nonhemorrhagic and noninfarcted adenomas appeared both hypo- and isodense as did adenomas with infarction, cyst formation, or old hemorrhage (fig. 2). Two calcified PRL-secreting microadenomas were encountered; no other lesions were calcified by CT. No lesions enhanced more than the adjacent cavernous sinus.

Adenoma extension/invasion into the cavernous sinus was encountered in 11 macroadenomas and into the sphenoid sinus in 10 (fig. 3). No documented metastases from adenomas were identified.

When all micro- and macroadenomas were evaluated as a whole, discrete, hypodense, focal lesions were encountered in only 34 patients (30%). Adenoma enhancement characteristics were variable in all categories with 50 isodense lesions (44%), 49 hypodense lesions (43%), and 13 mixed-density lesions (11%). Sellar floor erosion was present in 63 patients (56%), and 43 patients had supraclinoid extension of mass (38%).

The mean gland height for PRL-secreting adenomas was 10.9 mm, for GH-secreting adenomas 13.6 mm, for ACTH-secreting adenomas 10.3 mm, for TSH-secreting adenomas 14.5 mm, and for nonfunctioning adenomas 26.0 mm.

Discussion

The principal findings of our study indicate the similarity in CT appearance of secretory and nonsecretory adenomas. In

general, the principal findings in macroadenomas reflect mass effect and displacement of adjacent structures, while in microadenomas CT abnormalities are relatively uncommon and nonspecific.

A discrete, focal, hypodense lesion was identified only in the secretory adenoma group; however, it was an uncommon finding (35%). Discrete focal lesions were more common in microadenomas (47%) than in macroadenomas (10%), but correlated well with the surgical site of the adenoma (91%). Hemminghytt [9] found that hypodensity and enlargement of the pituitary gland were the most useful criteria for identification of microadenomas. In our series, however, only 51% of PRL-, 50% of GH-, and 18% of ACTH-secreting microadenomas were associated with focal hypodense lesions. Thus, 33 proven microadenomas (53%) were isodense to the surrounding pituitary gland. No discrete, hypodense lesion was identified in 90% of macroadenomas; instead, the enhancement characteristics of macroadenomas were variable with uniformly isodense, uniformly hypodense, and mixed-density lesions encountered in all categories. These findings differ from prior reports, particularly with earlier-generation scanners or axial images only [10-14].

Using our scanning technique, the normal intrasellar contents are approximately isodense or very slightly hypodense compared with the adjacent enhancing parts of the cavernous sinus. Presumably the attenuation characteristics of the gland reflect both a high level of intravascular and tissue iodine, since images are obtained immediately after a bolus of contrast material is administered, with an intravenous drip infusion during scanning. With this in mind, no lesions were identified that enhanced more than the density expected for the normal intrasellar contents. Two calcified PRL microadenomas were identified by CT and histology; no other calcified lesions were encountered.

The infundibulum was eccentric in position in only 18% of micro- and macroadenomas. When displaced, however, its position correlated in 79% with the position of the pituitary gland, thus reflecting displacement by the contralateral pituitary adenoma. In anatomic studies, however, the infundibulum may be normally slightly eccentric in position due to eccentric

positioning of the posterior lobe of the pituitary [29]. The infundibulum was visible in virtually all microadenomas, however, it was not identifiable in 59% of macroadenomas. Invasion of the infundibulum by adenoma was not described at surgery; thus, the inability to image the infundibulum presumably represents inability to identify the enhancing infundibulum separate from the adjacent supraclinoid adenomatous tissue.

The diaphragma sellae may normally be flat, concave, or generally convex [17, 18]; thus, we considered only focal convexity of the diaphragma sellae as potentially useful in localizing an adenoma [16]. Focal convexity of the diaphragma sellae was more often identified in microadenomas (29%) than in macroadenomas (6%). The focal convexity correlated with the site of the adenoma at surgery in 80%, thus suggesting its value in localizing an adenoma preoperatively.

Many authors have described pitfalls in using sellar floor erosion for localization of adenoma [20–23]. In our series, 42% of microadenomas and 72% of macroadenomas had radiographic evidence of sellar floor erosion. Overall surgical correlation with the adenoma site was 78%. As expected, the accuracy of sellar floor erosion in predicting the site of a microadenoma was somewhat less than that of the macroadenomas, with a 73% correlation when the microadenomas are considered separately.

Extension of tumor into the sphenoid sinus was identified by CT in both secretory and nonsecretory macroadenomas. The distinction between frank invasion of the sphenoid sinus and enlargement and/or expansion of the sella into the sphenoid sinus was unsuccessful. In view of the fact that the normal sellar floor may be only a few microns thick [20–23], it is thus not surprising that we were unable to determine when frank erosion through the dura was present.

Involvement of the cavernous sinus was difficult to correlate with surgical findings; frequently, a specific description of adenoma in the cavernous sinus was not given. This area is difficult to demonstrate surgically, especially in large tumors that expand the sella laterally. In cases in which the adenoma was adherent to or immediately adjacent to the internal carotid arteries at surgery, we were able to identify bowing or enlargement of the cavernous sinuses [19], suggesting extension of adenoma into this area.

As expected, supraclinoid extension of tumor was uncommon in microadenomas and common in macroadenomas, basically reflecting the size of the lesion. Only two microadenomas (3%) resulted in a height of intrasellar contents greater than 10 mm. Several macroadenomas were encountered, however, that extended into the sphenoid sinus and/or cavernous sinus with no suprasellar extension. Histologically invasive adenomas were encountered only in the macroadenoma group. These lesions were radiographically indistinguishable from others that were radiographically aggressive but histologically noninvasive.

In the absence of a discrete focal lesion or infundibulum displacement, the pituitary gland could not be reliably differentiated from the adjacent adenoma, even retrospectively with knowledge of the location of the pituitary gland at surgery. Histologically, an adenoma is a proliferation of a benign cell type that normally exists in the pituitary gland [24–26];

thus, it is logical that an adenoma might have attenuation characteristics similar to the normal pituitary. It seems likely that with high-resolution CT the presence of infarction, cyst formation, and old hemorrhage would be recognizable; however, in our series, adenomas with and without histologically identifiable areas of infarction, cyst, or old hemorrhage were radiographically similar.

In summary, secretory and nonsecretory pituitary adenomas are similar in appearance radiographically. Discrete focal hypodense lesions suggest a secretory adenoma and usually a microadenoma; however, secretory adenomas of all sizes are often isodense with the adjacent pituitary gland. Secretory adenomas tend to present earlier clinically and, thus, result in few CT abnormalities. The location of the normal pituitary gland could not be determined by attenuation characteristics; only in the presence of infundibulum displacement contralateral to an adenoma or a discrete focal hypodense lesion could the gland location be predicted reliably. Adenomas harboring hemorrhage, infarction, and cyst formation are indistinguishable from those without these findings. CT is helpful in identifying the mass effect of macroadenomas; however, in microadenomas of all types CT abnormalities are infrequent. Thus, the diagnostic evaluation of the patient suspected of harboring a pituitary adenoma, and particularly a microadenoma, must remain a joint effort based on clinical, radiographic, and endocrinologic data.

ACKNOWLEDGMENTS

We thank Francine Hallowell for secretarial assistance; photographer Joe Jackson; and Daphne Eitel, Emory University Hospital, for clinical assistance in data accumulation.

REFERENCES

1. Wolpert SM, Post KD, Biller BJ, Molitch ME. The value of computed tomography in evaluating patients with prolactinomas. *Radiology* **1979**;131:117–119
2. Syvertsen A, Haughton VM, Williams AL, Cusick JF. The computed tomographic appearance of the normal pituitary gland and pituitary microadenomas. *Radiology* **1979**;133:385–391
3. Newton DR, Witz S, Norman D, Newton TH. Economic impact of CT scanning on the evaluation of pituitary adenomas. *AJNR* **1983**;4:57–60, *AJR* **1983**;140:573–576
4. Kricheff II. Opinion. The radiologic diagnosis of pituitary adenoma. An overview. *Radiology* **1979**;131:263–265
5. Teasdale E, Macpherson P, Teasdale G. The reliability of radiology in detecting prolactin-secreting pituitary microadenomas. *Br J Radiol* **1983**;54:566–571
6. Tindall GT, Hoffman JC Jr. Evaluation of the abnormal sella turcica. *Arch Intern Med* **1980**;140:1078–1083
7. Chambers EF, Turski PA, LaMasters DL, Newton TH. Regions of low density in the contrast enhanced pituitary gland: normal and pathologic processes. *Radiology* **1982**;144:109–113
8. Gardeur D, Naidich TP, Metzger J. CT analysis of intrasellar pituitary adenomas with emphasis on patterns of contrast enhancement. *Neuroradiology* **1981**;20:241–247
9. Hemminghytt S, Kalkhoff RK, Daniels DL, Williams AL, Grogan JP, Haughton VM. Computed tomographic study of hormone-secreting microadenomas. *Radiology* **1983**;146:65–69
10. Belloni G, Baciocco A, Borelli P, Sagui G, DiRocco C, Maira G. The value of Ct for the diagnosis of pituitary microadenomas in

- children. *Neuroradiology* **1978**;15:179-181
11. Bonafe A, Sobel D, Salandini AM, et al. Diagnostic value of CT scanning in pituitary microadenomas (abstr). *Neuroradiology* **1981**;20:263
 12. Citrin CM, Davis DO. Computerized tomography in the evaluation of pituitary adenomas. *Invest Radiol* **1977**;12:27-35
 13. Godin D, Stevenaert A, Thibault A. Reliability of the CT scan for the diagnosis of microadenoma in a normal sized sella turcica (abstr). *Neuroradiology* **1981**;20:261
 14. Gyldensted C, Karle A. Computed tomography of intra- and juxta-sella lesions. A radiological study of 108 cases. *Neuroradiology* **1977**;14:5-13
 15. Wolpert SM. The radiology of pituitary adenomas. *Semin Roentgenol* **1984**;19:53-69
 16. Davis PC, Hoffman JC, Tindall GT, Braun IF. Prolactin-secreting pituitary microadenomas: inaccuracy of high-resolution CT imaging. *AJNR* **1984**;5:721-726, *AJR* **1985**;144:151-156
 17. Swartz JD, Russell KB, Basile BA, O'Donnell PC, Popky GL. High-resolution computed tomographic appearance of the intrasellar contents in women of child-bearing age. *Radiology* **1983**;147:114-117
 18. Wolpert SM, Molitch ME, Goldman JA, Wood JB. Size, shape, and appearance of the normal female pituitary gland. *AJNR* **1984**;5:263-267, *AJR* **1984**;143:377-381
 19. Kline LB, Acker JD, Post MJD, Vitek JJ. The cavernous sinus: a computed tomographic study. *AJNR* **1981**;2:299-305
 20. Bruenton JN, Drouillard JP, Sabatier JC, Elie GP, Tavernier JF. Normal variants of the sella turcica. *Radiology* **1979**;131:99-104
 21. Sage MR, Blumbergs PC, Fowler GW. The diaphragma sellae: its relationship to normal sellar variations in frontal radiographic projections. *Radiology* **1982**;145:699-701
 22. Dubois PJ, Orr DP, Hoy RJ, Herbert DL, Heinz ER. Normal sellar variations in frontal tomograms. *Radiology* **1979**;131:105-110
 23. Renn WH, Rhoton AL. Microsurgical anatomy of the sellar region. *J Neurosurg* **1975**;43:288-298
 24. Landolt AM. Pituitary adenomas. Clinico-morphologic correlations. *J Histochem Cytochem* **1979**;27:1395-1397
 25. Landolt AM. Progress in pituitary adenoma biology. Results of research and clinical application. In: Krayenbuhl H, ed. *Advances and technical standards in neurosurgery*, vol 5. Wien: Springer-Verlag, **1978**:4-49
 26. McComb DJ, Ryan N, Horvath E, Kovacs K. Subclinical adenomas of the human pituitary. New light on old problems. *Arch Pathol Lab Med* **1983**;107:488-491
 27. Balagura S, Frantz AG, Housepian EM, Carmel PW. The specificity of serum prolactin as a diagnostic indicator of pituitary adenoma. *J Neurosurg* **1979**;51:42-46
 28. Editorial. Hyperprolactinaemia: pituitary tumour or not? *Lancet* **1980**;1:517-519
 29. Roppolo HMN, Latchaw RE, Meyer JD, Curtin HD. Normal pituitary gland: 1. Macroscopic anatomy-CT correlation. *AJNR* **1983**;4:927-935