

Are your **MRI contrast agents** cost-effective?

Learn more about generic **Gadolinium-Based Contrast Agents**.



FRESENIUS
KABI

caring for life

AJNR

Intraoperative Sonographic Monitoring of Reduction of Thoracolumbar Burst Fractures

John P. McGahan, Daniel Benson, Bahram Chehrazi, John P. Walter and Franklin C. Wagner, Jr.

AJNR Am J Neuroradiol 1985, 6 (5) 787-790

<http://www.ajnr.org/content/6/5/787>

This information is current as
of April 20, 2024.

Intraoperative Sonographic Monitoring of Reduction of Thoracolumbar Burst Fractures

John P. McGahan¹
 Daniel Benson²
 Bahram Chehrizi³
 John P. Walter¹
 Franklin C. Wagner, Jr.³

Intraoperative real-time sonography was used to monitor surgical reduction of acute thoracolumbar burst fractures in eight patients. Real-time sonography was performed after laminectomy through a saline-filled operative field using either a 5.0 or a 7.5 MHz transducer. Sonography was performed during Harrington rod distraction and during fracture reduction to confirm adequacy of decompression of the spinal canal. This technique is useful to monitor surgery and in defining adequate fracture reduction.

Treatment of vertebral fractures is undertaken to relieve neural compression and to stabilize the vertebral column [1]. Operative treatment may vary but often includes a method of stabilizing thoracolumbar fractures using metallic rods as proposed by Dickson et al. [2]. Previous authors have advocated several methods of evaluating intraoperative reduction of vertebral fractures including direct inspection, cross-table lateral radiographs, and intraoperative myelography [1]. Recently, high-resolution sonography has been shown to be helpful for intraoperative localization and guidance during surgical exploration of the spinal cord [3–5]. We show the use of high-resolution sonography for intraoperative monitoring of reduction of thoracolumbar vertebral fractures.

Materials and Methods

Intraoperative sonography was performed in eight patients using a 5 MHz or a 7.5 MHz ATL MK600 real-time sector scanner in seven and an ATL dedicated neurosector scanner in one (Advanced Technology Labs., Bellevue, WA). Hard-copy films were obtained in the operating room, but in three cases films were obtained from 1/2 inch (1.27 cm) videotape after leaving the operating room. All eight patients had fractures of the thoracolumbar vertebral column as diagnosed and evaluated preoperatively by radiographs and noncontrast computed tomography (CT). These were all burst fractures at the thoracolumbar junction, which are classified by Denis [6] as type B. In each case, the body was fractured anteriorly with an additional fracture of the superior part of the body and end-plate posteriorly. This part of the vertebral body protruded into the vertebral canal reducing the diameter of the neural canal. All fractures were acute with operations performed 12 hr to 2 weeks after injury (table 1).

Sonography was performed after laminectomy or hemilaminectomy and medial facetotomy with the patient in the prone position and with the operative field filled with saline. The sonographic scanner was placed in a sterile covering and then positioned in the saline water path, thus allowing an acoustic window without actually touching the dura. The posterior part of the vertebral bodies was scanned before placement of Harrington rods and while distraction was applied. Real-time sonography allowed monitoring of the spinal cord and the displaced vertebral fracture. Since adequate reduction was not obtained after a Harrington rod distraction alone, manipulation of the fracture was performed using a narrow bone impactor placed into the canal lateral to the dural margin in seven of eight cases (table 1). In these cases, in addition to using longitudinal sonograms, the transverse sonographic plane was helpful in locating laterally displaced fragments. Sonography was also used to check adequacy of final bony decompression.

While complete restoration of the normal contour of the posterior aspect of the spinal canal

This article appears in the September/October 1985 issue of *AJNR* and the December 1985 issue of *AJR*.

Received October 24, 1984; accepted after revision February 15, 1985.

¹ Department of Radiology, University of California, Davis, School of Medicine, 4301 X St., Room 109R, Sacramento, CA 95817. Address reprint requests to J. P. McGahan.

² Department of Orthopedic Surgery, University of California, Davis, School of Medicine, Sacramento, CA 95817.

³ Department of Neurosurgery, University of California, Davis, School of Medicine, Sacramento, CA 95817.

AJNR 6:787–790, September/October 1985
 0195–6108/85/0605–0787

© American Roentgen Ray Society

TABLE 1: Summary of Patients with Thoracolumbar Burst Fractures Monitored by Intraoperative Sonography

Case No. (age, gender)	Type of Accident	Fracture (Age of Fracture at Surgery)	Neurologic Deficit	Intraoperative Sonography	Surgery	Follow-up
1 (20, M)	Motor vehicle	L1 burst fracture with fragment displaced 8 mm into canal (4 days)	Mild conus injury	Fracture, step-off reduced to 2 mm	Laminectomy + Harrington rods + fusion T10-L3	No neurologic deficit
2 (37, M)	Motor vehicle	T12 burst fracture with 8 mm displacement into right side of canal (2 days)	Right leg weakness	Complete reduction of fracture	Laminectomy + Harrington rods + fusion T9-L2 + bone impaction	Improving strength, right leg
3 (25, M)	Motor vehicle	T12 burst fracture with 10 mm displacement into canal + associated fracture of lamina of T12 (8 days)	None	Fracture, step-off reduced to 1 mm	Laminectomy + Harrington rods + fusion T9-L2 + bone impaction	Normal
4 (40, M)	Motor vehicle	L1 burst fracture with 10 mm displacement into the canal + fracture of L1 lamina (2 weeks)	None	Fracture reduced to 2 mm	Laminectomy + Harrington rods + fusion T10-L3 + bone impaction	Normal
5 (34, M)	Motorcycle	T12 burst fracture with 12 mm displacement into canal (12 hr)	Incomplete L1 paraplegia	Fracture reduced to 1 mm	Laminectomy + Harrington rods + fusion T9-L2 + bone impaction	Incomplete L1 paraplegia (improving)
6 (50, F)	Golf cart	T12 burst fracture with 6 mm displacement to canal (2 weeks)	None	Complete reduction of fracture	Laminectomy + Harrington rods + fusion T9-L2 + bone impaction	Normal
7 (60, F)	Fall from ladder	L1 burst fracture with 8 mm displacement into canal (12 hr)	Mild conus injury	Fracture, step-off reduced to 1-2 mm	Laminectomy + Harrington rods + fusion T10-L4 + bone impaction	Improving conus injury
8 (28, F)	Thrown from horse	T12 burst fracture with 12 mm displacement into canal (12 hr)	Incomplete L1 paraplegia	Fracture, step-off reduced to 2 mm	Laminectomy + Harrington rods + fusion T9-L2 + bone impaction	Incomplete L1 paraplegia

was not always achieved, sonography was helpful in demonstrating relief of cord impingement and the degree of restoration of the ventral subarachnoid space (table 1, figs. 1 and 2). In all patients, postoperative radiographs and CT scans of the vertebral column were obtained.

Results

The vertebral canal and its contents were well demonstrated on sonography in all eight cases. The fracture location and patient data, including neurologic status and surgical procedure, are listed in table 1. The bony fragments that caused the compression of the vertebral canal were seen

with sonography, both before and after reduction, and during distraction with Harrington rods (figs. 1 and 2). No other intraoperative radiographic method was used to assess reduction of the vertebral canal. Follow-up radiographs and CT scans all confirmed the intraoperative sonographic findings of good vertebral alignment and canal decompression.

Discussion

It is commonly accepted that operative reduction and stabilization of the thoracolumbar vertebral fractures can be performed regardless of the present neurologic damage. The rationale for this intervention is to relieve any persisting

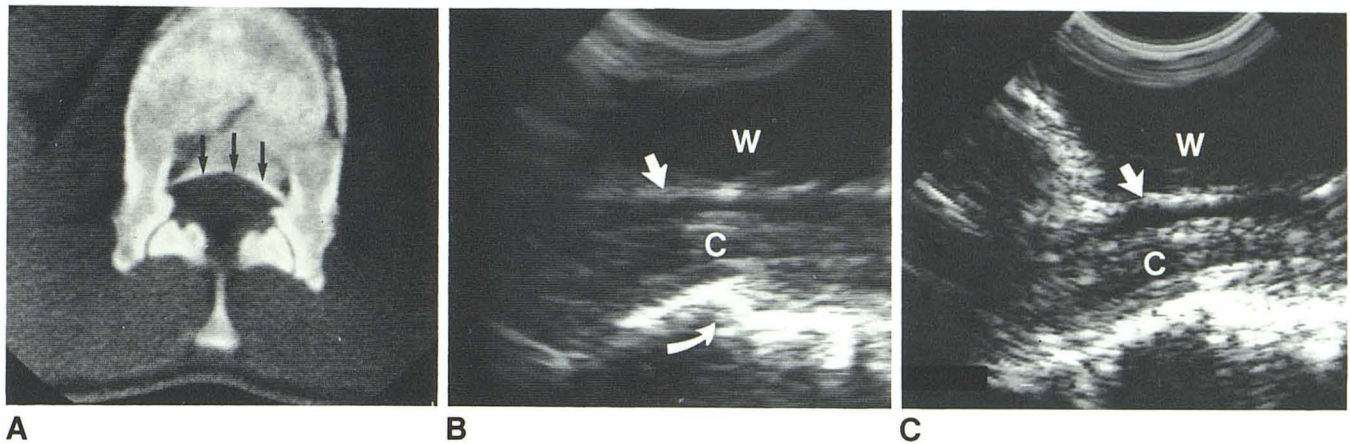


Fig. 1.—Case 1. **A**, Burst fracture of vertebral body of L1 with posterior displacement into spinal canal (arrows). **B**, Intraoperative sonogram. Spinal cord (C) with posterior aspect of dura (straight arrow) scanned through saline water path (W). Step-off of fracture of lumbar spine (curved arrow). **C**, Postre-

duction intraoperative sonogram. Spinal cord, dura (arrow), and water path. In addition to Harrington rod distraction, bone impaction was needed to cause improvement in step-off fracture of L1.

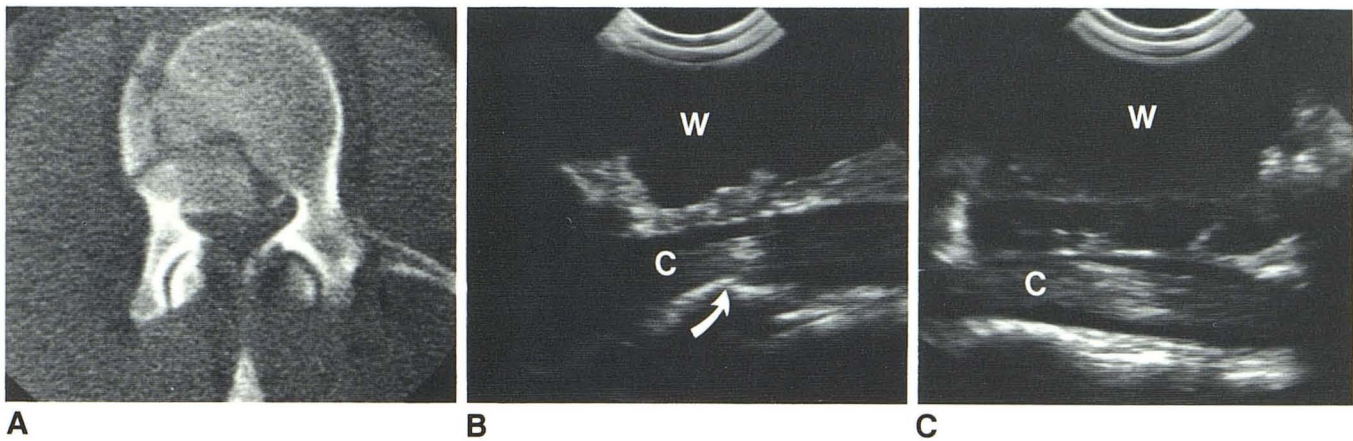


Fig. 2.—Case 2. **A**, Burst fracture involving mainly right side of vertebral body of T12 with bony displacement into spinal canal. **B**, Intraoperative sonogram. Spinal cord (C) is scanned through saline path (W) showing displaced fracture of posterior part of T12 (arrow). **C**, Postreduction sonogram of same

area. Spinal cord is scanned through saline path with good reduction of fracture. In addition to Harrington rod distraction, bone impaction was needed to cause improvement in step-off fracture of L1.

spinal cord compression and alleviate the potential for any future neurologic compromise by stabilizing the vertebral column [1]. Incomplete lesions have the potential for significant recovery, and neurologically intact patients can develop neurologic compromise if there is late angulation deformity of the vertebral column [7].

An unstable vertebral fracture is defined as a fracture that has the potential to displace with time and may cause further bony compression of the cord or the cauda equina. We believe stabilization is beneficial in acute burst fractures in both neurologically normal patients to prevent deterioration and in neurologically compromised patients in the hopes of improving neurologic deficit. Reduction was attempted only in acute fractures (less than 2 weeks old), as the ability of fracture reduction would decrease with fractures 3–4 weeks of age due to fracture healing and callus formation.

Harrington distraction rods were used in all eight of our cases to restore vertebral body height, maintain spinal alignment, and correct the kyphotic deformity. Harrington distraction alone usually does not reduce the bony fragment from the vertebral canal in type B burst fractures. To remove the bony fragment from the vertebral canal, it must either be impacted posteriorly or removed anteriorly. A laminectomy allows access for the impaction to be accomplished during the Harrington distraction process. This eliminates a second procedure and allows access for the monitoring of the operation with the sonographic technique described. In all eight of these patients, decompression was obtained in this manner, although in other previous patients at our institution, a posterior or posterolateral approach was used to reduce the bony fragment. This lateral method is less preferred since it is more time-consuming.

Intraoperative monitoring of vertebral fracture reductions is often difficult, with the surgeon having to either probe or attempt direct inspection of the anterior margins of the vertebral canal. Plain films in the operating room may be inadequate in detailing thin displaced fractures and herniated disk material. Intraoperative myelography has been advocated as a method to check for reduction of spinal cord compression, but it suffers from time delay and the potential for arachnoiditis in the face of bloody cerebrospinal fluid [2]. It also is a one-time demonstration of the spinal canal rather than continuous monitoring, as can be achieved with sonography. Intraoperative sonography provides for direct demonstration and monitoring of the posterior part of the vertebral body fracture and its encroachment on the spinal cord [8].

While complete anatomic alignment of the dorsal part of the vertebral body was not always obtained in our patients (table 1), we accepted fracture step-off of 2 mm with accompanying relief of cord impingement and restoration of ventral subarachnoid space. During the distraction with rods, a fragment of the fractured vertebral body could potentially be turned along its remaining fibrous attachments and cause increased compromise of the spinal cord, especially if there is associated partial tear of the posterior longitudinal ligament. Since the bony anatomy is covered with the dura and its contents, such a focal canal compromise may go unnoticed. However, intraoperative monitoring of the spinal fracture during distraction may be extremely useful in detecting such an event. Operative sonography allows simultaneous demonstration of the reduction of the fracture fragment, is a safe and accurate technique, and is time-efficient relative to previous methods. The procedure takes just 1 hr of the technician's time and about 30 min of the radiologist's time. Another advantage of operative sonography is the potential for show-

ing spinal abnormalities associated with trauma, such as an intracanalicular hematoma. In the future, as smaller sonographic probes become available, monitoring may be possible through the interlaminar window. For these reasons, we believe that intraoperative sonography provides an excellent method for evaluation of adequacy of reduction of vertebral burst fractures.

ACKNOWLEDGMENTS

We thank Karen Anderson for manuscript preparation and Reisha Bryan, Joen Traeger, and Debbie Jarvis for technical assistance.

REFERENCES

1. Jelsma RK, Kirsh PT, Jelsma LF, et al. Surgical treatment of thoracolumbar fractures. *Surg Neurol* **1982**;18:156-166
2. Dickson JH, Harrington PR, Erwin WD. Results of reduction and stabilization of the severely fractured thoracic and lumbar spine. *J Bone Joint Surg [Am]* **1978**;60:799-805
3. Braun IF, Raghavendra BN, Kricheff II. Spinal cord imaging using real-time high resolution ultrasound. *Radiology* **1983**;147:459-465
4. Dohrmann GJ, Rubin JM. Intraoperative ultrasound imaging of the spinal cord: syringomyelia, cysts, and tumors—a preliminary report. *Surg Neurol* **1982**;18:395-399
5. Rubin JM, Dohrmann GJ. Work in progress: intraoperative ultrasonography of the spine. *Radiology* **1983**;146:173-175
6. Denis F. The three column spine and its significance in the classification of acute thoracolumbar spinal injuries. *Spine* **1983**;8:817-831
7. Chehrazai B, Wagner FC, Collins WF, et al. A scale for evaluation of spinal cord injury. *J Neurosurg* **1981**;54:310-315
8. Montalvo BM, Quencer RM, Green BA, et al. Intraoperative sonography in spinal trauma. *Radiology* **1984**;153:125-134