

Are your **MRI contrast agents** cost-effective?

Learn more about generic **Gadolinium-Based Contrast Agents**.



FRESENIUS
KABI

caring for life

AJNR

CT myelography of calcified thoracic neurilemmoma.

P E Dross and M R Raji

AJNR Am J Neuroradiol 1985, 6 (6) 967-968

<http://www.ajnr.org/content/6/6/967.citation>

This information is current as
of April 16, 2024.

CT Myelography of Calcified Thoracic Neurilemoma

P. E. Dross¹ and M. R. Raji¹

Radiographic demonstration of calcification within spinal canal tumors is rare [1]. The most common lesion of this type showing calcification is a meningioma. Other lesions showing calcification include neurofibromas, hemangioblastomas, neuroblastomas, ganglioneuromas, and herniated thoracic disks. Very rarely is calcification seen within neurilemmomas [2, 3], and, if present, it may be noted histologically but not radiographically [2]. Our case is the first reported computed tomographic (CT) myelography demonstration of a rare, calcified, thoracic, extradural neurilemoma.

Case Report

A 47-year-old woman presented to our hospital with a 20 year history of mid and lower back pain that had recently increased in severity leaving her with a "heavy sensation" in her back. Routine physical and neurologic examinations revealed numbness in the T11 nerve root distribution on the right side. The thoracic spine plain films and myelogram showed a well calcified, extradural, dumbbell-type, intra- and extra-spinal-canal lesion on the right side at the T11-T12 level causing compression of the spinal cord (fig. 1A). The CT myelogram demonstrated marked enlargement of the adjacent intervertebral foramen with destruction of the right T11 lamina (fig. 1B) and a smooth compression erosion of the posterior T11 vertebral body (fig. 1C).

The patient underwent surgical exploration and decompression with a T11 and T12 laminectomy and total resection of the tumor. Microscopic evaluation of the specimen showed the characteristic Antoni type A cells with dense spindle-shaped cells and aggregates of palisading nuclei. Postoperatively, the patient's neurologic examination returned to normal and the patient remained symptom-free.

The patient underwent surgical exploration and decompression with a T11 and T12 laminectomy and total resection of the tumor. Microscopic evaluation of the specimen showed the characteristic Antoni type A cells with dense spindle-shaped cells and aggregates of palisading nuclei. Postoperatively, the patient's neurologic examination returned to normal and the patient remained symptom-free.

Discussion

Neurilemmomas are benign, smoothly encapsulated, soft-tissue tumors that can occur along a nerve root at any level of the craniospinal axis. The most common location is in the thoracic region of the spinal canal [4]. They usually produce signs and symptoms of myelopathy because of associated compression of the spinal cord and/or nerve roots. In the lumbar region, they can simulate disk disease [4]. Most of these tumors (67%) are intradural in location, with only 16% being entirely extradural [3].

Radiographically demonstrable calcification within spinal

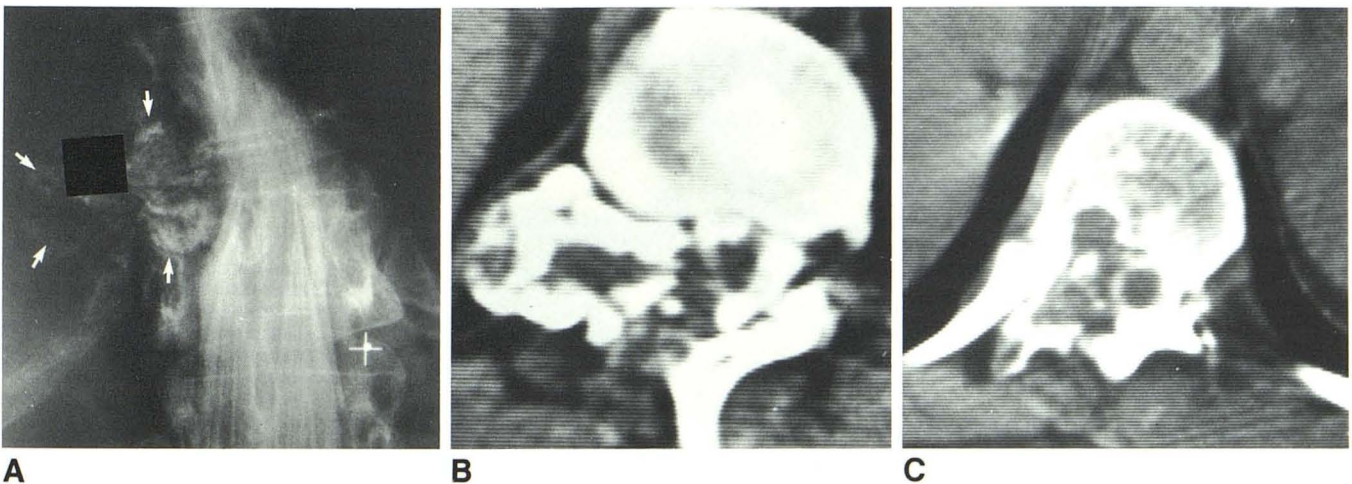


Fig. 1.—**A**, Well defined, calcified, intra- and paraspinous mass (arrows) with destruction of T11 pedicle and compression of spinal cord. **B**, CT myelogram at level of lesion. Intra- and paraspinous mass is well delineated. Marked widening

of foramina and destruction of pedicle and lamina. **C**, Intraosseous extension of lesion into right posterior vertebral body with well defined ring of sclerosis.

Received April 30, 1984; accepted after revision August 8, 1984.

¹ Department of Radiology, Section of Neuroradiology, Mercy Hospital, Pride & Locust Sts., Pittsburgh, PA 15219. Address reprint requests to M. R. Raji.

neurilemmas is rare and has been said not to occur [2, 3]. A review of the literature shows two previous case reports of calcified, spinal neurilemmas: one in the cervical spine [1] and the other in the thoracic spine [5]. Calcification within a neurilemma located outside the spinal axis is also very rare. Kinoshita et al. [6] reported a case of calcification with a mandibular lesion and Naeim and Waisman [7] reported a calcified neurilemma of the larynx. Our case is only the second report to our knowledge of calcification within a thoracic intraspinal neurilemma and the first to be evaluated by CT myelography.

The radiologic appearance of spinal neurilemmas is variable. They may present as dumbbell-type lesions with erosion or destruction of the adjacent intervertebral foramen, pedicle, or lamina and can cause erosion of the posterior vertebral body surface, usually with preservation of a thin sclerotic margin. Bone changes are four times as common in neurilemmas as in meningiomas [3]. In our case, the extraspinal extension and bone destruction are unusual for a meningioma. The degree of bony destruction seen on the plain films, however, made the differential diagnosis more difficult and suggested an osteoblastoma, as these lesions commonly involve the neural arch and show variable amounts of tumor matrix calcification [8].

In our case, CT was able to delineate the degree of bony destruction and intraosseous extension to better advantage. It further aided in the differentiation from osteoblastoma. Conceivably, in the future, CT will further delineate faintly calcified neurilemmas not seen on plain films alone.

REFERENCES

1. Bonstelle C, Vines F. Calcification in a cervical intraspinal neurilemma. *Neuroradiology* **1976**;10:231-233
2. Lombardi G, Passerini A. Spinal cord tumors. *Radiology* **1961**;76:381
3. Shapiro R. *Myelography*, 3d ed. Chicago: Year Book Medical, **1975**:300-309
4. Chaddock W. Intraspinal neurilemmas simulating lumbar disc disease. *Va Med* **1971**;98:25-30
5. Schimmel D, Newton T. Calcification within a thoracic neurilemma. *Neuroradiology* **1974**;8:55-56
6. Kinoshita Y, Takaesu T, Shimura K, Komori A. Central neurilemma of the mandible associated with diffuse calcification: report of a case. *Nippon Koku Geka Gakkai Zasshi* **1976**;22:488-497
7. Naeim F, Waisman J. Calcified neurilemma of the larynx. *Ann Otol Rhinol Laryngol* **1973**;82:212-215
8. Resnick D, Niwayama G. *Diagnosis of bone and joint disorders*. Philadelphia: Saunders, **1981**:2656-2659