

Are your MRI contrast agents cost-effective?
Learn more about generic Gadolinium-Based Contrast Agents.



AJNR

Three-Dimensional CT Reformation in Children

Nolan R. Altman, Donald H. Altman, S. Anthony Wolfe and
Glenn Morrison

AJNR Am J Neuroradiol 1986, 7 (2) 287-293
<http://www.ajnr.org/content/7/2/287>

This information is current as
of April 18, 2024.

Three-Dimensional CT Reformation in Children

Nolan R. Altman¹
 Donald H. Altman¹
 S. Anthony Wolfe²
 Glenn Morrison³

Three-dimensional computed tomographic (CT) reformation has proven useful in the evaluation of congenital malformations of the brain as well as in the surgical approach and postoperative assessment of craniofacial anomalies in children. This technique was performed on 41 patients, of whom eight are presented. The congenital anomalies of semilobar holoprosencephaly and colpocephaly are described. Six representative cases of craniofacial anomalies with pre- and postoperative examinations include Crouzon syndrome, orbital fibrous dysplasia, frontonasal encephalocele, cranial involvement from neurofibromatosis, Treacher-Collins syndrome, and a Tessier III facial cleft. Addition of the dimension of depth provides a view heretofore not obtainable by standard imaging techniques and allows more accurate diagnosis as well as a more specific approach to surgical planning and follow-up.

Three-dimensional (3-D) computed tomographic (CT) reformation has been used successfully as an adjunct to standard axial CT in the evaluation of craniofacial disorders [1, 2]. In children we have found soft-tissue algorithms for ventricular casts useful in evaluating certain complex congenital anomalies of the brain. Craniofacial disorders are evaluated better with bone algorithms. The earlier work on 3-D reformations from CT scans of Herman et al. [3, 4] is the basis from which our 3-D package program was obtained. Other methods of 3-D reformation have also been reported in the literature [5]. This study shows the valuable additional information from 3-D reformation of CT images in conjunction with routine axial images.

Subjects and Methods

Technique

Consecutive 1.5-mm-thick axial images were obtained with a GE 8800 scanner. The number of axial images depended on the size of the region of interest. A head-scanning circle was used. A low-dose technique can be employed for bone algorithms with a shortened pulse width of 1 at 20 mA. However, better smoothing is seen with a higher-dose technique. Our routine uses a pulse width of 2 at 200 mA and 120 kV.

3-D reformation of the images is performed about the X, Y, and Z axes (fig. 1). The 3-D program, "3-D 83," was developed by the Medical Imaging Processing Group, Department of Radiology, Hospital of the University of Pennsylvania, for General Electric Medical Systems. This program takes the consecutive 1.5 mm axial images and redisplay them in 3-D projections by rearranging the volume elements (voxels). This is done by subregioning the desired area on the axial images and determining the number of axial slices to be used, thereby defining the superior-inferior limits. The interpolated slices are then created by forming new voxels from the original densities obtained from the axial images. Congenital brain abnormalities are best evaluated using the soft-tissue algorithm; craniofacial abnormalities are displayed using the bone algorithm. The 3-D effect is conferred by the various shading techniques used with our program package. This procedure has been described by Hemmy et al. [1]. We have found 15° angular increments of rotation about the X, Y, and Z

This article appears in the March/April 1986 issue of *AJNR* and the June 1986 issue of *AJR*.

Received April 10, 1985; accepted after revision July 24, 1985.

Presented in part at the annual meeting of the American Roentgen Ray Society, Boston, April 1985.

¹Department of Radiology, Miami Children's Hospital, 6125 S.W. 31st St., Miami, FL 33155. Address reprint requests to N. R. Altman.

²Division of Plastic Surgery, Miami Children's Hospital, Miami, FL 33155.

³Division of Neurosurgery, Miami Children's Hospital, Miami, FL 33155.

AJNR 7:287-293, March/April 1986
 0195-6108/86/0702-0287

© American Society of Neuroradiology

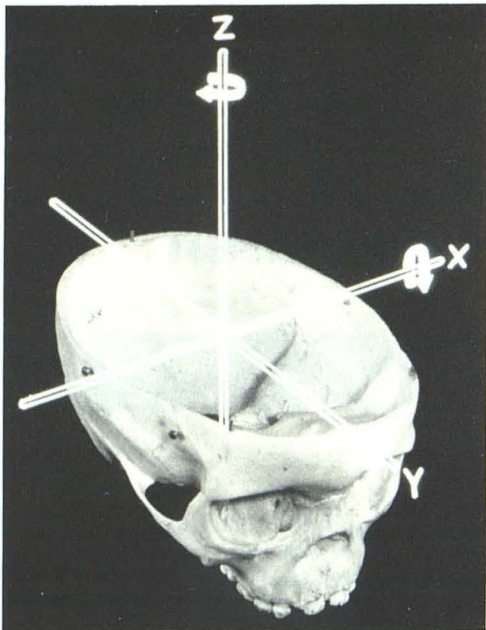


Fig. 1.—Planes of reformation. Each study was performed about X, Y, and Z axes as displayed. Selected single planes of rotation are demonstrated in Figs. 2–9.

axes, resulting in 24 images per axis of rotation, to be satisfactory. About 75 min of computer time is required.

Subjects

Forty-one patients from the departments of neurological surgery and plastic surgery at Miami Children's Hospital were studied with this technique. Eleven patients had both pre- and postoperative examinations. Of these, two patients are presented to illustrate the soft-tissue algorithms in evaluation of the brain anomalies. Six examples of craniofacial anomalies illustrate the procedure with the bone algorithm.

Representative Case Reports

Case 1: Colpocephaly (fig. 2)

A 7-month-old child was evaluated for developmental delay. Delivery at 38 weeks gestation by cesarean section was reportedly due to enlarged ventricles shown on fetal sonography. No neonatal infections were identified. The neurologic examination was intact except that the infant's vision appeared decreased on neuroophthalmologic examination. Visual-evoked responses were determined to be normal. Routine CT with 3-D reformation showed that the configuration of the ventricular system was normal except for the marked dilatation of the occipital poles. This finding has been described as colpocephaly [6]. The abnormality was believed to represent a disorder in the

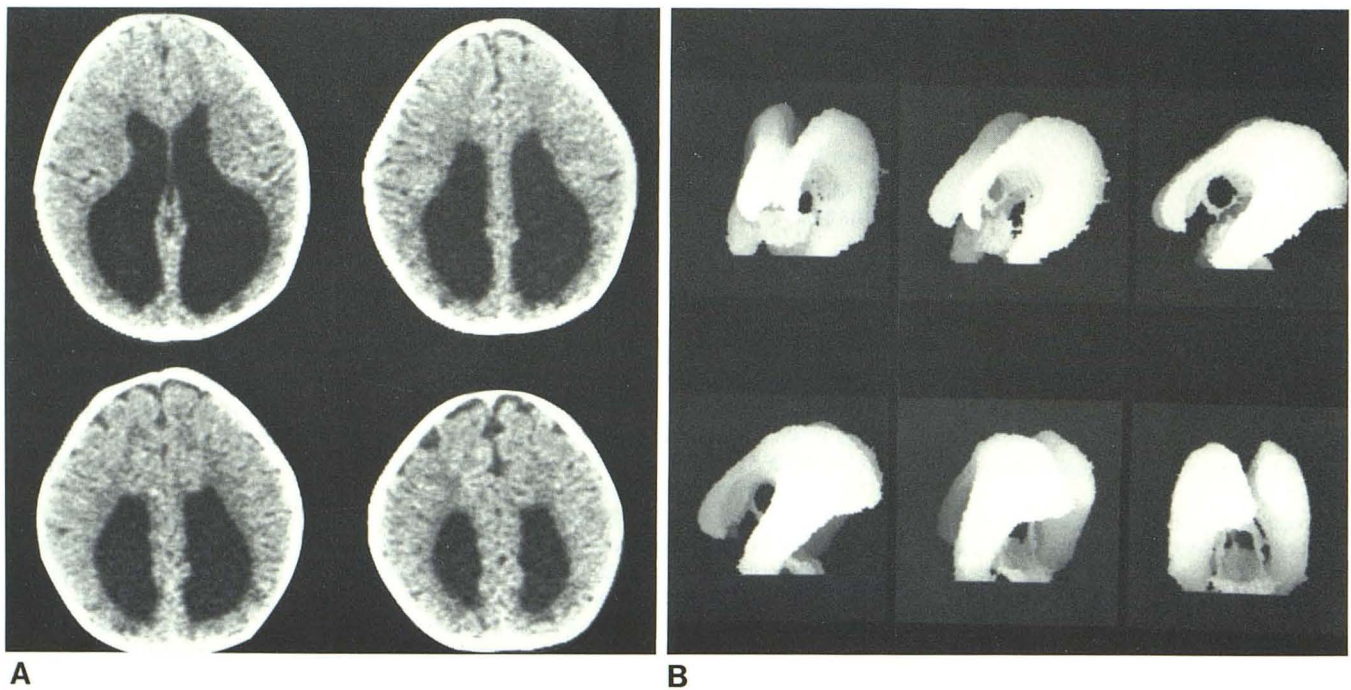


Fig. 2.—Case 1. Colpocephaly. A, Axial scans through brain show lateral ventriculomegaly with disproportionate enlargement of occipital poles. B, 3-D CT reformations about Z axis show ventricular enlargement proceeding from

frontal to lateral planes (top) and lateral to posterior frontal planes (bottom). Lateral, third, and fourth ventricles are seen without water-soluble contrast medium.

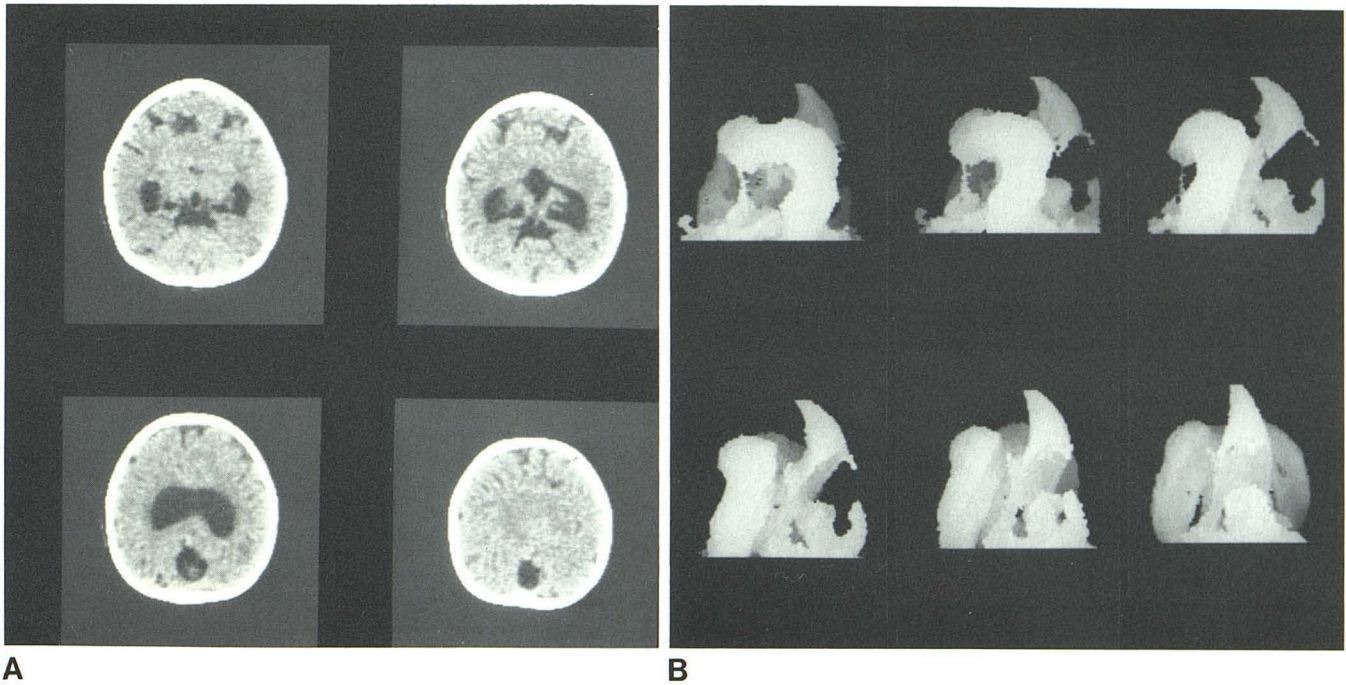


Fig. 3.—Case 2. Semilobar holoprosencephaly. **A**, Axial images show typical semilobar holoprosencephaly. Note monoventricle with dorsal cyst and fusion of thalami. White matter crosses midline in frontal region. **B**, 3-D projections about Z axis show rotation of structures from anterior frontal to lateral (top)

and lateral to posterior frontal planes (bottom). Monoventricle with fusion anteriorly and rudimentary development of temporal horns are seen. Dorsal cyst projects posteriorly and superiorly to monoventricle. Spatial relations are uniquely demonstrated.

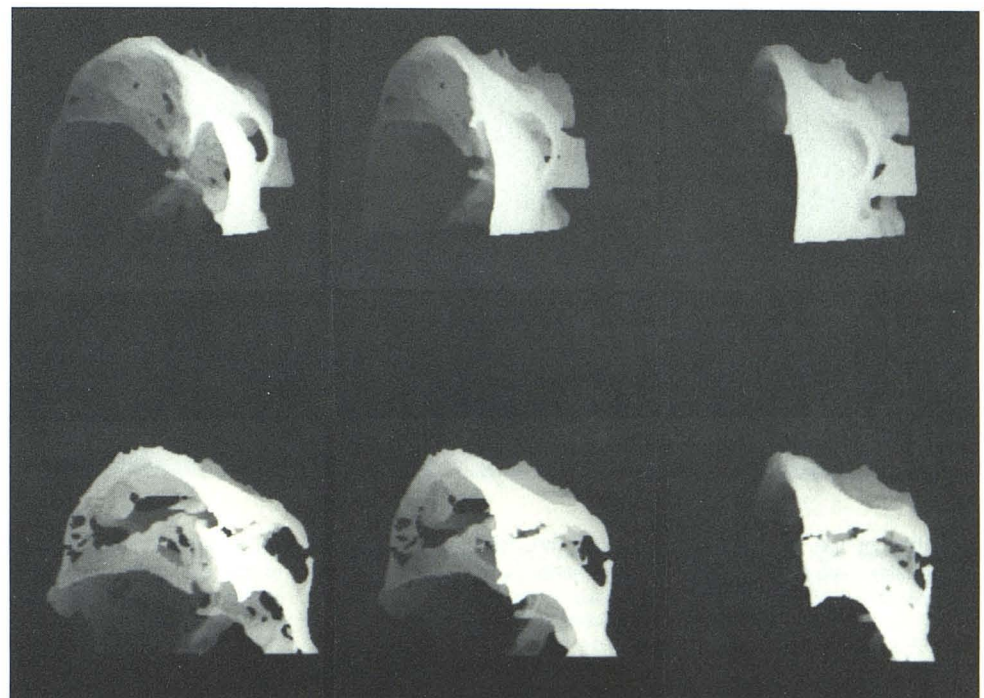
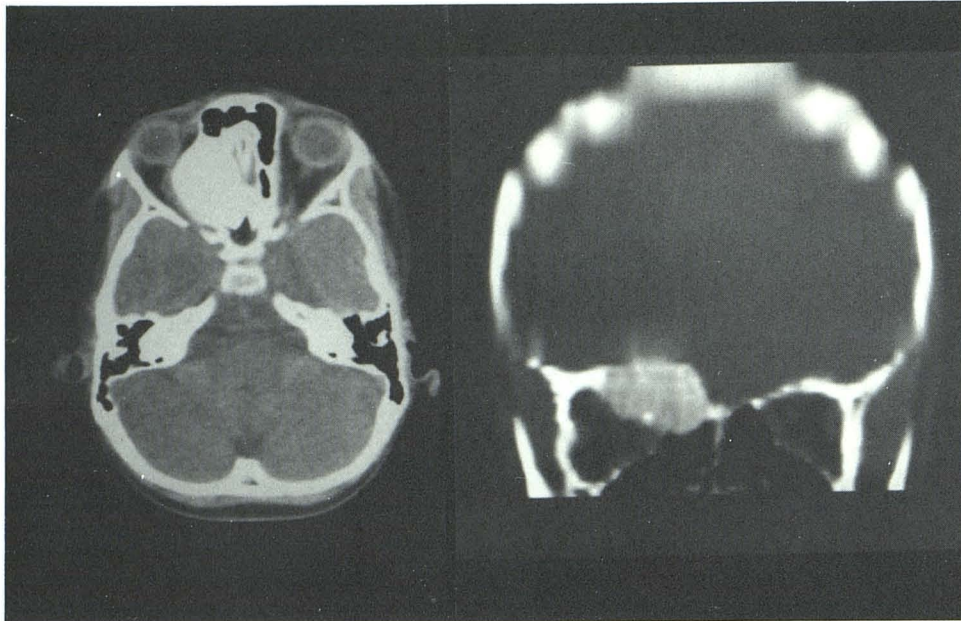
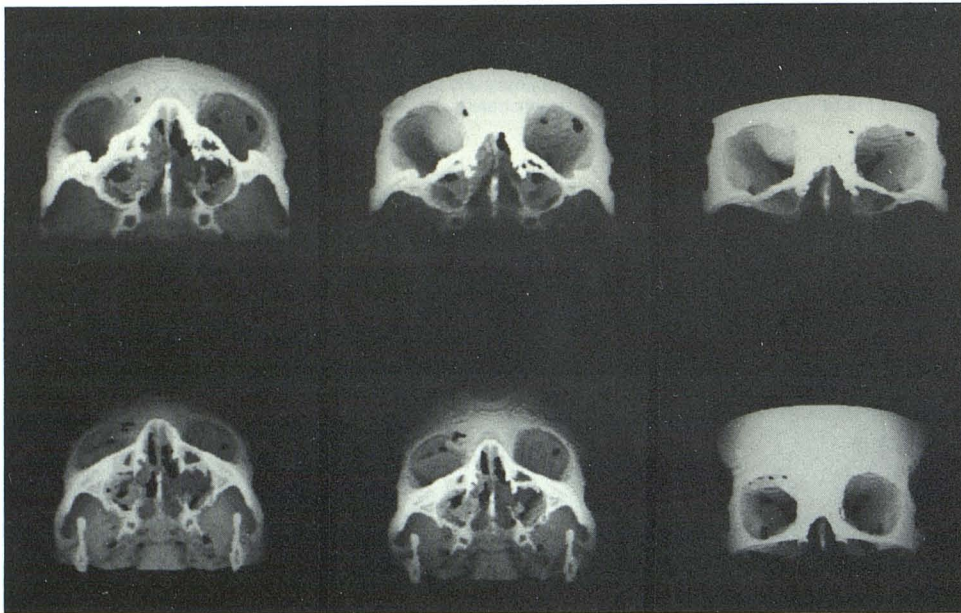


Fig. 4.—Case 3. Crouzon syndrome. 3-D CT reformations about Y axis preoperatively (top) show shallow anterior cranial fossa and maxillary hypoplasia. Postoperative study (bottom) shows craniotomy along anterior cranial fossa floor, through roofs of orbits and cribriform plate. Advancement of anterior cranial fossa, zygomatic arches, temporal bone, and maxilla is beautifully illustrated.



A



B

Fig. 5.—Case 4. Orbital fibrous dysplasia. **A**, Direct axial and coronal reformatted images show large bony lesion in region of right orbital roof, extending into right orbit and involving both inner and outer tables of bone. Right optic nerve and medial rectus muscle are displaced. **B**, 3-D CT reformation about X axis with preoperative (top) and postoperative (bottom) examinations. On preoperative study, spatial relation of bony lesion of orbital roof is seen. Postoperative views show suitability of bone overlay graft to orbital roof.

formation of the lateral ventricles about the calcar avis. Similar abnormalities are noted in Chiari II malformation.

Case 2: Semilobar Holoprosencephaly (fig. 3)

A 6-day-old girl was born to a 33-year-old diabetic mother. Apgar scores were 3 at 1 min and 1 at 5 min. The child's head was microcephalic (circumference, 27 cm), and her forehead slanted backward. Chromosomal karyotype revealed a dislocation of 13 with translocation of 22. Initial CT revealed a semilobar holoprosencephaly,

which has been previously reported [7]. She was seen at 1½ years of age with profound developmental delay. A repeat CT scan was obtained with 3-D reformation.

Case 3: Crouzon Syndrome (fig. 4)

A 3-year-old boy presented for craniofacial reconstructive surgery. He had one previous operation for release of a bilateral cranial synostosis of the coronal suture. The patient exhibited bilateral

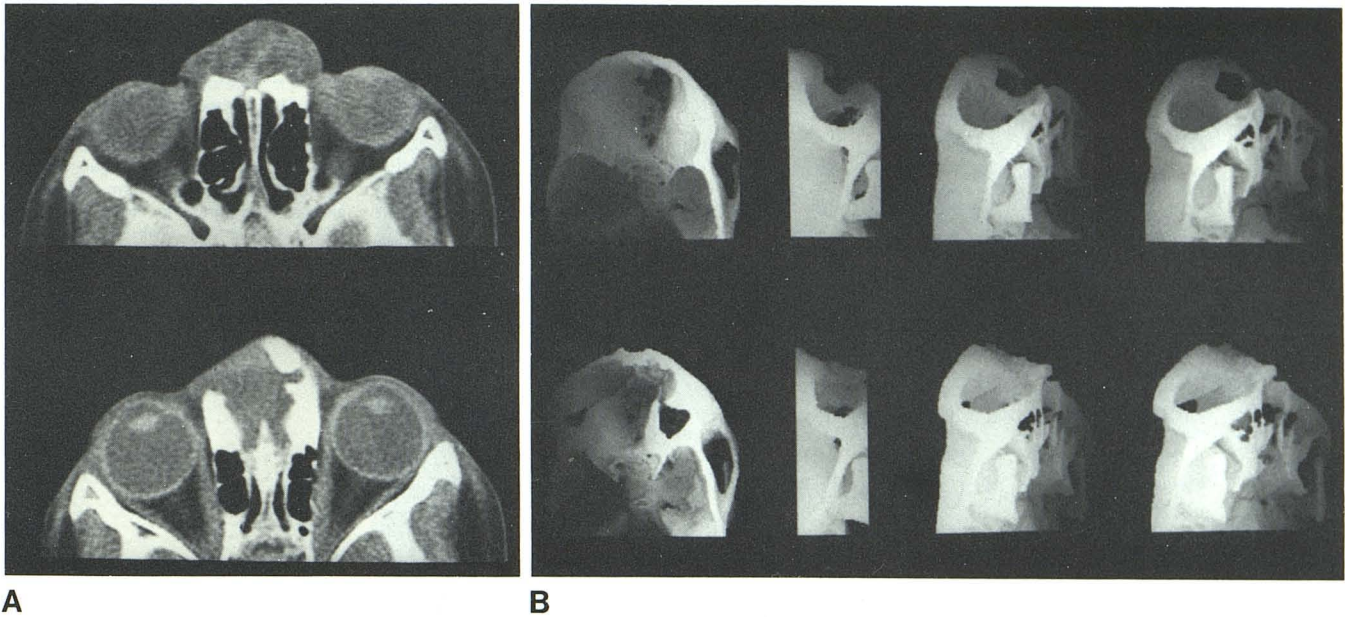


Fig. 6.—Case 5. Frontonasal encephalocele. **A**, Axial images of soft-tissue density extending below cribriform plate as well as anteriorly. **B**, 3-D CT reformation about X axis preoperatively (top) and postoperatively (bottom).

Bony defect in region of glabella, extending through cribriform plate. Nasion is intact. Postoperatively, bone graft appears to be perfectly suited to bony defect.

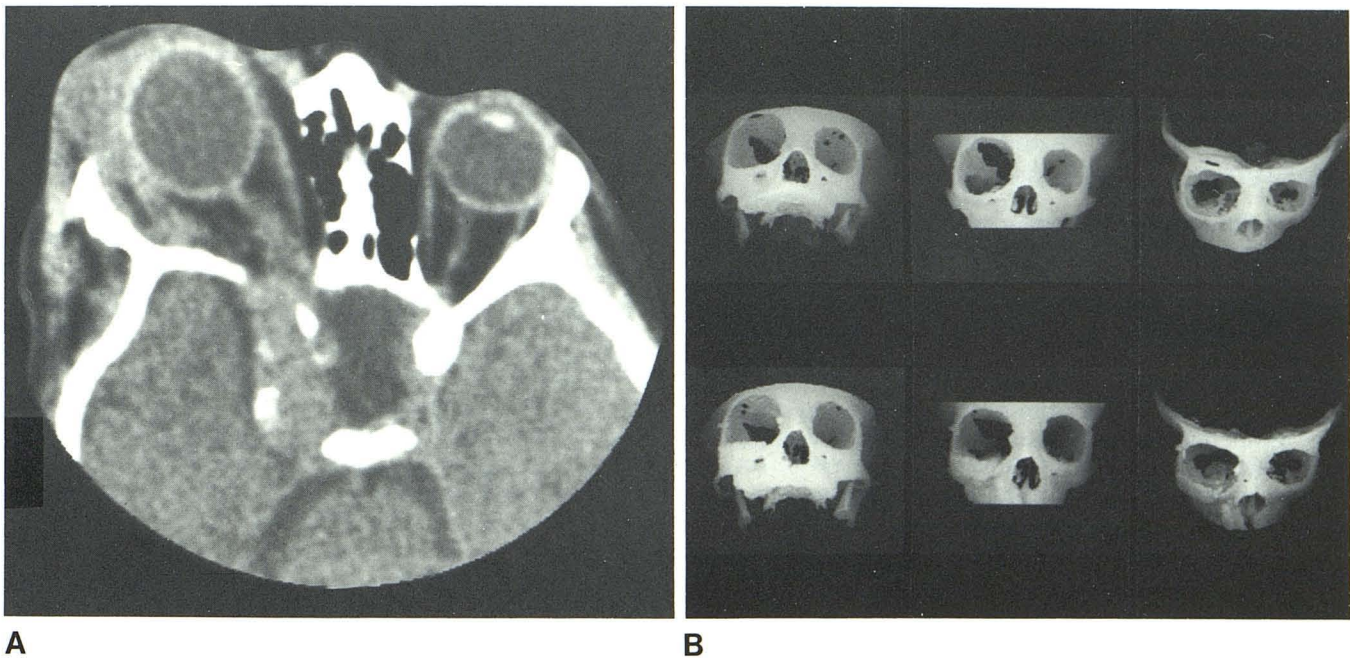


Fig. 7.—Case 6. Orbital involvement of neurofibromatosis. **A**, Axial image of right sphenoid wing dysplasia. Enlargement of optic nerve, particularly at apex, represents optic nerve glioma. Extraorbital mass seen anteriorly represents plexiform neurofibroma. Gasserian ganglion is involved. **B**, 3-D CT reformation about X axis preoperatively (top) shows marked asymmetry in

orbital size; right is about twice size of left. Absence of right sphenoid bone and enlargement of superior and infraorbital fissures are seen. Postoperative examination (bottom) shows overlay bone graft of orbital floor with reduction of right orbit and previously described bony defect.

coronal synostosis, exorbitism, and midfacial retrusion. He underwent a monoblock, frontofacial Lefort III advancement. Postoperatively, the child did well. Pre- and postoperative 3-D reformation CT scans were obtained.

Case 4: Orbital Fibrous Dysplasia (fig. 5)

A 7-year-old girl had a large right orbital mass that was slowly enlarging and producing moderate exophthalmus. The vision of the

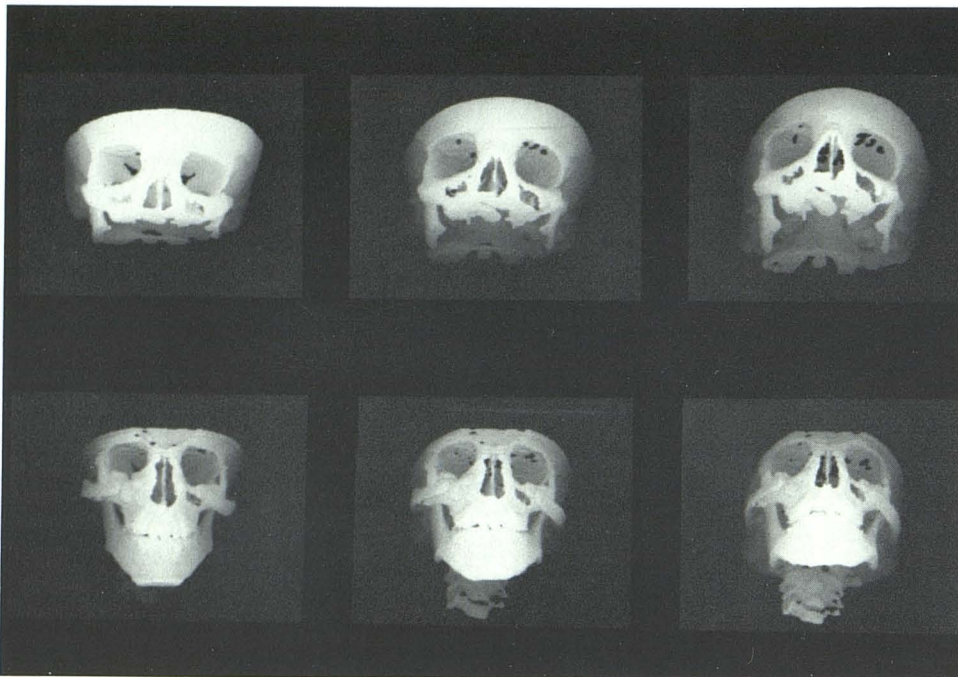


Fig. 8.—Case 7. Treacher-Collins syndrome. 3-D CT reformation about X axis shows preoperative asymmetry (top) of sides. Left side shows marked hypoplasia of frontal process of frontal bone and zygoma, seen to lesser degree on right. Zygomatic arches are not developed bilaterally. On postoperative examination (bottom), bone grafts form zygomatic arches. Asymmetry is noted as left is angulated inferiorly. Overlay bone grafts along lateral orbital walls.

eye was unaffected. A transcranial removal of this mass, which filled the superomedial angle of the right orbit, was performed. On the plain film, calcification was noted above the orbital roof. Axial CT with coronal reformation and pre- and postoperative 3-D CT were performed.

Case 5: Frontonasal Encephalocele (fig. 6)

This 2-year-old girl had a previous operation at birth for a frontonasal encephalocele. She still had a closure defect in the glabellar region. Preoperative 3-D CT showed the extent of the defect, which was in the glabellar region but did not extend to the nasal bone. The encephalocele defect was almost entirely closed by orbital bone after trimming of the orbital roof. Preoperative 3-D CT provided better planning of the procedure by allowing the surgeon to know exactly what size bone graft he needed to close this defect.

Case 6: Cranial Involvement of Neurofibromatosis (fig. 7)

A 4-year-old girl with the diagnosis of neurofibromatosis presented with a plexiform neurofibroma, increasing right orbital proptosis, and maxillary soft-tissue involvement. She was admitted and underwent a hemi-Lefort I osteotomy with removal of the tumor from the cheek, maxilla, and orbital floor, which allowed for further expansion of the orbit. Axial pre- and postoperative 3-D CT was done.

Case 7: Treacher-Collins Syndrome (fig. 8)

A 12-year-old girl was first seen at the age of 2 years 10 months when a diagnosis of Treacher-Collins syndrome (mandibulofacial dysostosis) was made. She had a hearing difficulty as well as delayed cognitive functions. Pre- and postoperative 3-D CT scans were obtained.

Case 8: Tessier Type III Facial Cleft (fig. 9)

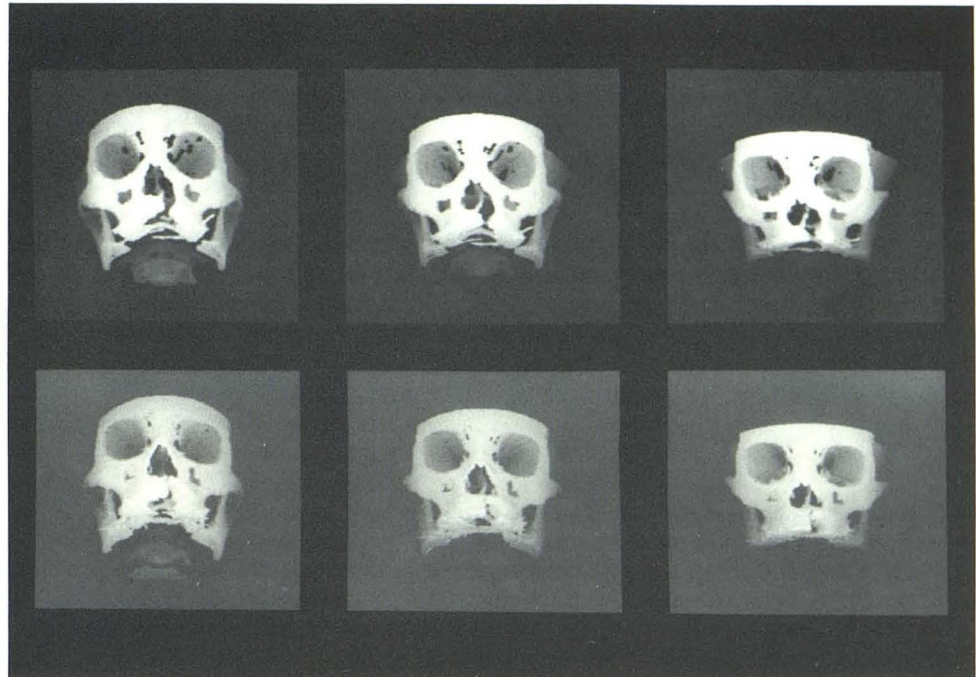
An 11-year-old girl with a complete cleft of the lip and palate and a large residual alveolar cleft presented for reconstructive surgery. An iliac bone graft of the left alveolar cleft was performed with closure of the anterior cleft and the oronasal fistula. Pre- and postoperative CT scans were obtained. The preoperative 3-D CT scan demonstrated a Tessier type III facial cleft that could not have been predicted by the overlying soft-tissue abnormality.

Discussion

In evaluation of the child with a complex congenital anomaly of the brain or a craniofacial abnormality, this technique of 3-D reformation of CT images proved most helpful. The ability to assess the volume of the ventricular system and display this with spatial relations allows perception of these abnormalities not previously possible. Subarachnoid contrast agents are obviated, which was demonstrated with our cases of holoprosencephaly and colpocephaly.

In the craniofacial anomalies, we believe that this method offers a valuable adjunct to routine radiographic techniques. Previously, these children were evaluated by conventional tomograms, which expose the eye to a relatively high dose of radiation. The skin dose may be as high as 50–75 rad (0.5–0.75 Gy) [2]. With this technique, the dose is considerably lower, in the range of 2–3 rad (0.2–0.3 Gy). In addition, demonstration of osseous anatomy with the added dimension of depth markedly facilitates preoperative assessment. Craniofacial defects of bone as presented with the cases of frontonasal encephalocele, Tessier type III facial cleft, and orbital involvement of neurofibromatosis are more accurately described. Hypoplasia and agenesis of bone, as in the

Fig. 9.—Case 8. Tessier type III facial cleft. 3-D reformation about X axis preoperatively (top) shows defect of hard palate just left of midline. No associated naso-orbital clefts. On postoperative examination (bottom), note overlay bone grafts with reduction in size of cleft.



Treacher-Collins and Crouzon syndromes, are demonstrated beautifully. Symmetry is important, and is well appreciated in these cases as well as in the cases of orbital fibrous dysplasia. Posttraumatic preoperative evaluation for reconstructive surgery has also been performed by us as well as by others [2].

The postoperative studies demonstrate symmetry as well as a specific way to evaluate surgical results. Postoperative 3-D studies are found to be accurate when compared with surgical findings. The exact relation of bone implants and/or grafts can be assessed as well as followed. Measurements can be obtained directly from these images, but this capacity is limited and is currently being evaluated at our institution. Metallic sutures do not appear to pose a significant problem. Dental metallic artifacts limit the examination; however, in these young children, it was not a particular problem. Other artifacts that can be misleading are in areas of thin bone that may appear as defects on 3-D scans. Adequate knowledge of these regions and of this artifact is essential for interpretation.

In summary, we conclude that 3-D CT reformation is a valuable adjunct in the evaluation of congenital abnormalities of the brain as well as craniofacial disorders. Its use may obviate routine tomography in preoperative planning as well

as postoperative follow-up of reconstructive surgery in children.

REFERENCES

1. Hemmy DC, David DJ, Herman GT. Three-dimensional reconstruction of craniofacial deformity using computed tomography. *Neurosurgery* **1983**;13:534-541
2. Vannier MW, Marsh JL, Warren JO. Three-dimensional CT reconstruction images for craniofacial surgical planning and evaluation. *Radiology* **1984**;150:179-184
3. Herman GT, Lim HK. Three-dimensional display of human organs from computed tomograms. *Comput Graphics Image Process* **1979**;9:1-21
4. Artzy E, Frieder G, Herman GT. The theory, design, implementation and evaluation of a three-dimensional surface detection algorithm. *Comput Graphics Image Process* **1981**;15:1-24
5. Vannier MW, Marsh JL, Warren JO, Barkier J. Three-dimensional computer graphics for craniofacial surgical planning and evaluation. *Comput Graphics Image Process* **1983**;17:263-273
6. Gorg BP. Colpocephaly: an error of morphogenesis? *Arch Neurol* **1982**;39:243-246
7. Altman NR, Altman DH, Sheldon JJ, Leborgne J. Holoprosencephaly classified by computed tomography. *AJNR* **1984**;5:433-437