AJNR

CT Evaluation of Effects of Cranial Radiation Therapy in Children

Patricia C. Davis, James C. Hoffman, Jr., Gary S. Pearl and Ira F. Braun

AJNR Am J Neuroradiol 1986, 7 (4) 639-644
http://www.ajnr.org/content/7/4/639

This information is current as of April 16, 2024.

CT Evaluation of Effects of Cranial Radiation Therapy in Children

Patricia C. Davis[1]
James C. Hoffman, Jr.[1]
Gary S. Pearl[2]
Ira F. Braun[1]

A retrospective evaluation was completed of 49 children who received conventional cranial radiation therapy for primary central nervous system and/or skull-base neoplasia and who had follow-up CT studies. In these children, abnormalities in normal parenchyma away from the tumor itself were surprisingly frequent, with or without chemotherapy. Generalized volume loss or atrophy was the most frequent abnormality (51%), but in this population it may have resulted from a variety of causes. Calcification in nontumorous parenchyma was common (28%) with or without chemotherapy. The most frequent site of calcification was subcortical at the gray-white junction. Calcification was progressive over 1–2 years and correlated pathologically with mineralizing microangiopathy and dystrophic calcification with demyelination. White-matter abnormalities other than those associated with shunt malfunction and tumor edema occurred in 26% of the patients. Both white-matter abnormalities and calcification occurred predominantly in younger children, particularly those under 3 years old at the time of radiation therapy. Of the 21 children who received chemotherapy in this series, only two received methotrexate. White-matter abnormalities and calcifications occurred with similar frequency in children with and without chemotherapy; thus, radiation therapy is the most likely cause of these findings.

Cranial radiation therapy is a standard component of treatment for children with central nervous system (CNS) neoplasia. However, the long-term effects of this therapy on the developing brain are only recently being recognized. The literature [1–5] describes a decline in neuropsychological skills after radiation therapy, but the source of this decline is unclear. Pathologic studies [3, 6–10] suggest that radiation-induced abnormalities at therapeutic levels of radiation therapy are uncommon, or are exacerbated by the synergistic effect of chemotherapy, particularly methotrexate [11–25].

In this study a retrospective evaluation was completed of children who received therapeutic radiation for CNS neoplasia to determine (1) the frequency of CT abnormalities occurring in normal brain and (2) the contribution of radiation therapy to these abnormalities.

Materials and Methods

A retrospective review was completed of all children with primary CNS or skull-base neoplasia who underwent cranial radiation therapy between 1979 and 1982 (53 children). Only those with a follow-up CT examination at least 3 months after radiation therapy were included (mean follow-up time = 2.3 years, range = 3 months to 5½ years). Forty-nine children met these criteria.

Charts were reviewed to determine the surgical procedures performed; histologic diagnosis; age at time of radiation therapy; dose, fractionation, and portal of treatment; dates and types of chemotherapy administered; and clinical status at last follow-up visit.

CT scans were reviewed for abnormalities unrelated to the tumor itself. Abnormalities evaluated included presence, location, and progression of calcification; presence and location of white-matter abnormalities; focal or generalized atrophy; hydrocephalus; and infarction.

This article appears in the July/August 1986 issue of *AJNR* and the September 1986 issue of *AJR*.

Received May 20, 1985; accepted after revision August 27, 1985.

[1] Department of Radiology, Section of Neuroradiology, Emory University School of Medicine, 1365 Clifton Rd., N.E., Atlanta, GA 30322. Address reprint requests to P. C. Davis.

[2] Department of Pathology and Laboratory Medicine, Emory University School of Medicine, 1365 Clifton Rd., N.E., Atlanta, GA 30322.

***AJNR* 7:639–644, July/August 1986**
0195–6108/86/0704–0639
© American Society of Neuroradiology

TABLE 1: **Histologic Diagnosis, Location, and Radiation Dose**

Tumor Type	Location	Dose (Rads)	
		Whole Brain	Tumor
Medulloblastoma	Posterior fossa (17)	2550–4040	4500–5480
Medulloneuroblastoma	Posterior fossa (1)	3500	4450
Astrocytoma:fibrillary/pilocytic	Pons; no biopsy (2)	5000 (1)	4484 (1)
	Hypothalamus/chiasm (5)	4140–5600 (4)	3960 (1)
	Thalamus; no biopsy (1)	—	5000
Glioblastoma multiforme	Brainstem (1)	—	5000
	Rt. cereb. hemis. (1)	—	6100
	Lt. cereb. hemis. (1)	6500	—
Primitive neuroectoderm (malignant small cell)	Rt. frontal lobe (1)	3960	5960
Small-cell sarcoma	Thalamus (1)	—	5610
Ependymoma	4th cranial nerve (4)	3910–4980	4420–4800
	Lt. cereb. hemis. (2)	—	5500–5580
Ependymoma, malignant	4th ventricle (2)	3520	4800
Gangliocytoma	Rt. frontal lobe (1)	—	5500
Melanoma, malignant	Rt. temporal–parietal (1)	4050	5550
Pineal	Pineal; no biopsy (3)	4000	1000–1500
Craniopharyngioma	Suprasellar (1)	—	5700
Neuroblastoma	Rt. frontal (1)	5000	5800
	Both lateral vent. (1)	5000	—
Teratoma	Suprasellar & lt. temporal (1)	3500	—
Juvenile fibroma	Rt. orbit (1)	—	5500
Esthesioneuroblastoma	Sphenoid, lt. orbit, maxillary sinus (1)	—	5000

White-matter abnormalities related to tumor edema and/or shunt malfunction were excluded. Atrophy was described only when sulci, cisterns, and ventricles were enlarged consistently over a period of time proportionate to the child's age.

Nonneoplastic tissue, obtained after radiation therapy, was available from seven children, including three with complete postmortem examination of the CNS. This tissue was evaluated histologically, and results were correlated with radiographic and clinical findings.

Results

Forty-nine children ranging in age from 6 weeks to 17 years at the time of presentation were evaluated in this study. Diagnoses, histologic location, and radiation dose are charted in Table 1. Mean age at the time of radiation therapy was 7½ years (range 3 months to 17 years). Fractionation of radiation dose was less than or equal to 200 rads per day. Twenty-eight children were treated with surgery and radiation alone, and 21 children also received one or more courses of chemotherapy. Chemotherapeutic agents administered varied in type, dose, and route of administration. Only two children received methotrexate. Many children received acute steroid therapy during radiation therapy; however, none were on chronic steroid therapy. Many were maintained on chronic phenobarbital and/or phenytoin for seizure control or prophylaxis. Thirty-nine patients had ventricular shunts for hydrocephalus.

CT abnormalities encountered in nontumorous parenchyma are correlated with age at the time of radiation therapy and chemotherapy in Table 2. Atrophy for age was the most frequent abnormality encountered (Fig. 1), and was usually

TABLE 2: **CT Abnormalities Correlated with Age at Time of Radiation Therapy and Chemotherapy**

		Chemotherapy		Totals (%)
		+	−	
Atrophy:				
<3 yr (n = 14)	+	3	3	6 (43)
	−	2	6	
3–12 yr (n = 22)	+	6	6	12 (54)
	−	5	5	
>12 yr (n = 13)	+	2 (1*)	5	7 (54)
	−	3 (1*)	3	
Total				25 (51)
White-matter abnormalities:				
<3 yr	+	0	6	6 (43)
	−	5	3	
3–12 yr	+	1	2	3 (14)
	−	10	9	
>12 yr	+	4 (2*)	0	4 (31)
	−	1	8	
Total				13 (26)
Calcifications:				
<3 yr	+	2	6	8 (57)
	−	3	3	
3–12 yr	+	0	4	4 (18)
	−	11	7	
>12 yr	+	2 (1*)	0	2 (15)
		3 (1*)	8	
Total				14 (28)

Note.—The presence (+) or absence (−) of CT abnormalities is correlated with age in years at the time of radiation therapy on the vertical axis and with whether (+) or not (−) chemotherapy was administered on the horizontal axis.

* Two children received methotrexate as part of their chemotherapy; abnormalities in these children are in parentheses.

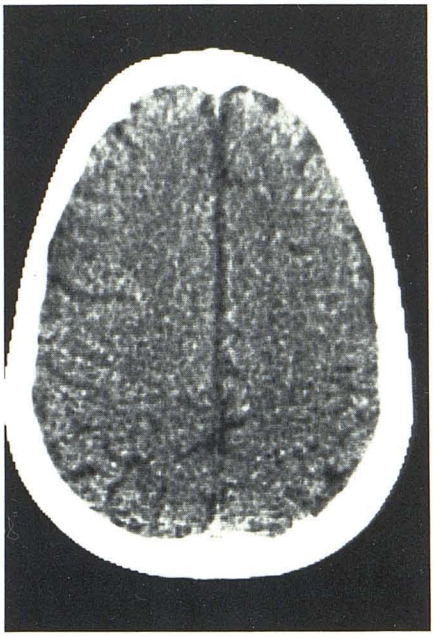

Fig. 1.—Generalized enlargement of cerebral sulci in 6-year-old child treated for ependymoma 2 years earlier with 4500 rads.

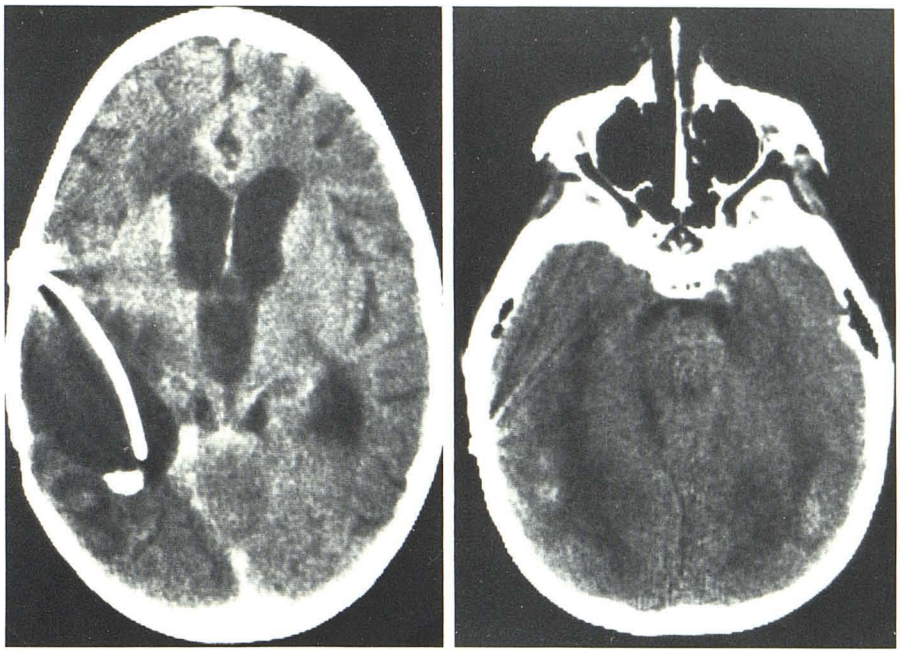

Fig. 2.—**A**, Focal right frontal white-matter area of decreased attenuation representing demyelination as confirmed by biopsy in an 11-year-old child treated for neuroblastoma 21 months earlier with 5000 rads. **B**, Lucent occipital white matter with adjacent gray-white junction calcification in a child treated for medulloblastoma 15 months earlier with 4535 rads to the posterior fossa.

generalized in distribution. Because the CT appearance of volume loss could vary from scan to scan, atrophy was described only when seen on multiple studies. Atrophy incidence varied little with age or administration of chemotherapy. Seventeen children had generalized atrophy as the only CT abnormality unrelated to the tumor itself.

Focal (three cases) or generalized (10 cases) areas of decreased white-matter attenuation were identified in 26% of the patients (Fig. 2). Nine of these also had focal calcifications. White-matter abnormalities occurred in nine patients who were younger than 12 years old. Two of the four children older than 12 years with white-matter abnormalities had received methotrexate. White-matter abnormalities were always within the radiation portal and were identified in children who had never received chemotherapy. Radiation dosage in this group ranged from 2600–5000 rads.

Calcifications in nontumorous parenchyma were identified in 14 children (Fig. 3), appearing as early as 3 months after radiation therapy. These tended to occur in younger children, with or without chemotherapy. Calcification occurred most frequently at the gray-white junction of the cerebral hemispheres followed by the basal ganglia, with one patient each having calcification in the caudate nucleus and cerebellum. In six children, calcification progressed in extent and density (Fig. 4). Calcification was encountered without CT evidence of white-matter disease or atrophy in four patients. Radiation doses in children with calcification ranged from 3500–5500 rads.

Infarction was encountered in only two children. Both had large chiasmal/hypothalamic gliomas; thus, their infarcts were not clearly related to radiation therapy [26]. Of these, one with bilateral middle cerebral artery infarcts developed extensive calcification in the infarcted tissue (Fig. 5).

No secondary neoplasms were identified in radiated tissue in this series.

Available information about intelligence and functional level was obtained from chart review; thus, detailed testing was not performed. Five children who showed no CT evidence of recurrent or residual tumor were intellectually and/or functionally impaired.

Nonneoplastic tissue was available for histologic examination after radiation therapy in seven children (four biopsy specimens, three autopsy). All demonstrated multiple abnormalities typical of radiation effects in normal tissue, including gliosis, demyelination, vascular fibrosis and/or fibrinoid necrosis, and calcification both in the neuropil and in or around vessels (Fig. 6). These changes were most striking in tissue near the neoplasm, but the extent of each change was variable from case to case. Six of the seven children had atrophy by CT with no histologic correlate. Only two had visible calcification on CT (one in basal ganglia, one in extensive infarctions); thus, the predilection for calcifications at the gray-white junction noted by CT could not be confirmed pathologically. Three specimens contained perivascular and/or dystrophic calcifications histologically that were not visible on CT. By CT, only one child of the seven had white-matter

hypolucency; this correlated histologically with extensive vascular fibrosis, calcification, and gliosis. The other six children had histologically identifiable white-matter abnormalities that were not apparent on CT.

Discussion

Although radiation therapy is of significant value in the management of children with primary CNS neoplasia, the long-term effects on survivors are unclear. Pathologic studies describe adverse effects of radiation therapy as uncommon both in adults and children [3, 6–10]; however, adverse effects in survivors are largely undocumented. Likewise, CT abnormalities in survivors may not be confirmed by biopsy and/or resection; thus, the true incidence of radiation-induced lesions is unknown. Many reports document the adverse effects of radiation therapy with large single or cumulative radiation dosages, or with daily fractions of greater than 200 rads [3, 6], but the relationship between these examples and conventional radiation therapy is unclear. To further complicate the issue, patients may also receive chemotherapeutic agents with known adverse effects on normal parenchyma or that have a synergistic effect with radiation therapy.

In children surviving acute lymphocytic leukemia, the adverse effects demonstrable by CT and pathology of methotrexate combined with low doses of radiation therapy are well documented [12–25, 27]. A synergistic effect exists between intrathecal or intravenous methotrexate and low levels of radiation, resulting in damage to normal parenchyma. Abnormalities include white-matter necrosis and mineralizing microangiopathy with secondary decreased intellectual function [5]. The sequelae in children treated with radiation therapy alone, however, are less clear.

In this series, primary goals were to identify abnormalities

Fig. 3.—Basal ganglia and gray-white junction calcification in a 4-year-old child treated for medulloblastoma at age 7 months with 3420 rads.

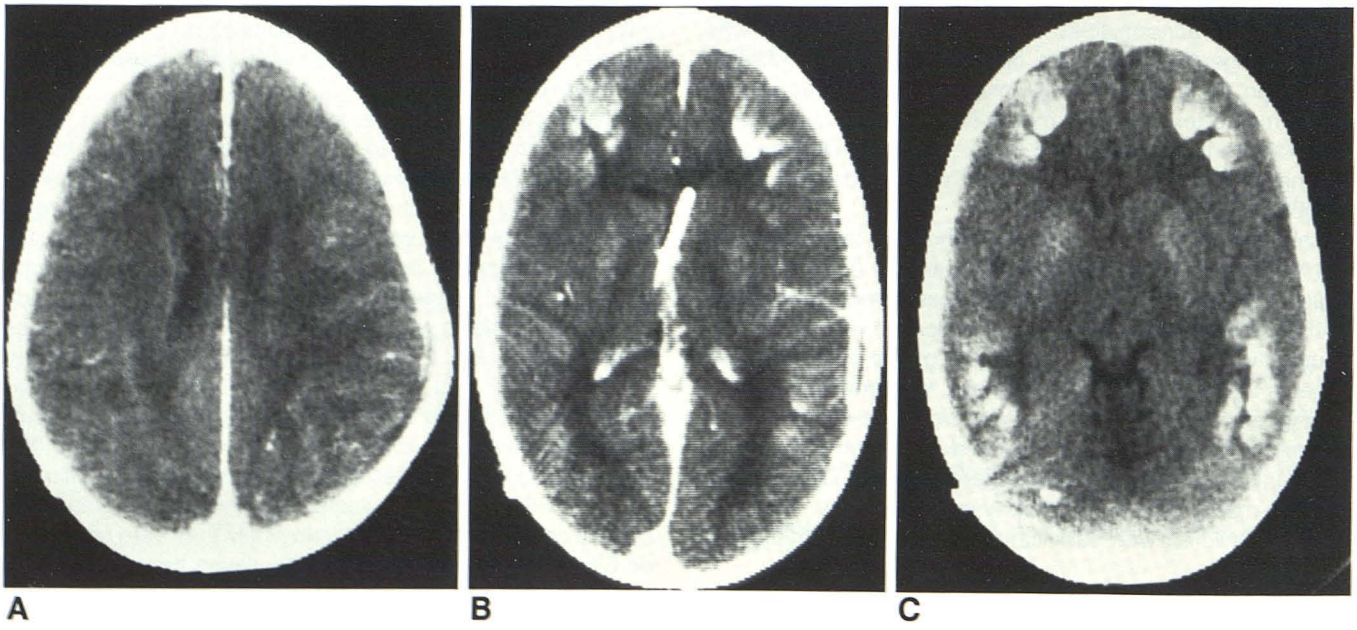

Fig. 4.—**A**, Calcifications first identified 7 months after radiation therapy for medulloblastoma (4930 rads at age 2½ years) progressed in extent and density over a 3-year follow-up (**B**). **C**, Noncontrast CT confirms calcifications.

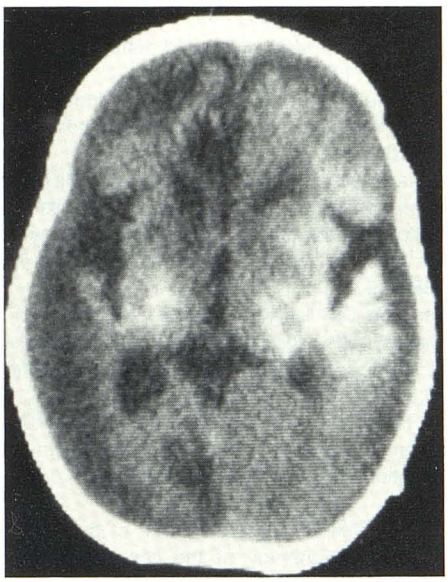

Fig. 5.—Extensive calcification of previously infarcted tissue in a child who received radiation therapy for optic chiasm/hypothalamic glioma 10 months earlier (4140 rads at age 5 months).

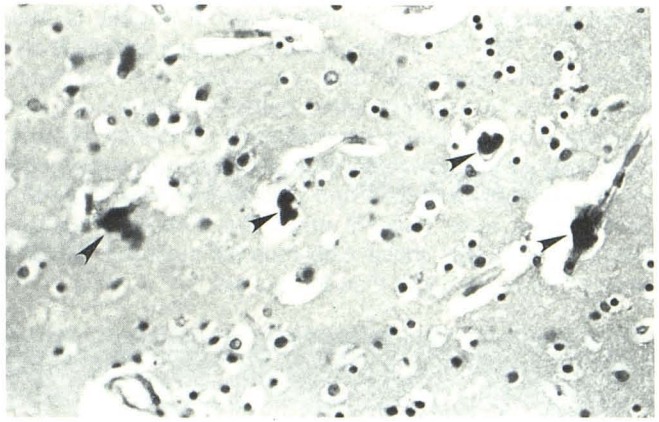

Fig. 6.—Mineralizing microangiopathy without methotrexate. Calcifications (*arrowheads*) are seen within and beside walls of small vessels in subcortical white matter in patient with hypothalamic astrocytoma treated 1 year earlier (age 5 months) with 4140 rads (hematoxylin-eosin, × 400).

apart from the tumor itself and to determine the relationship between these and the child's age at the time of radiation therapy and chemotherapy. The most frequent abnormality encountered (51%) was generalized volume loss or atrophy for the child's age. Although radiation therapy may be contributory, it is difficult to attribute atrophy to radiation alone. In this population, chemotherapy, other drugs (i.e., steroids and phenytoin), repeated episodes of increased intracranial pressure, postoperative subdural hygromas and/or hematomas, and nutritional disorders may be contributory. Furthermore, with serial CT studies "atrophy" may be transient or variable in degree.

The frequency of calcification on CT in nontumorous tissue in this series was surprising (28%). Interestingly, six of seven children with histologic evaluation showed significant calcification at the microscopic level. Calcification of the basal ganglia after radiation therapy is well recognized [28]. In this series, however, the most frequently identified site of calcification was subcortical at the gray-white junction, perhaps because of the image quality of high-resolution later-generation CT. Calcifications could be progressive over 1–2 years. Correlation with available pathology suggested that this subcortical calcification was a result of radiation-induced vasculopathy with perivascular calcification (mineralizing microangiopathy) or with demyelination and tissue necrosis followed by dystrophic calcification. Although mineralizing microangiopathy and dystrophic calcification are thought to be specific for the combination of methotrexate and radiation therapy [13, 24], in this series these pathologic abnormalities occurred with radiation alone.

White-matter abnormalities were identified in 26% of radiated children. White-matter abnormalities after radiation and methotrexate have been described [3, 12, 14, 17, 19, 21, 25]; however, in this group only two children received methotrexate. White-matter abnormalities tended to occur in younger children, particularly those under 3 years old, with or without chemotherapy. A rapid phase of myelination occurs in early childhood, so it is predictable that radiation therapy would adversely affect the proliferating glial elements in young children [6].

Premature atherosclerotic and arteriosclerotic vascular disease and even a moyamoya appearance have been attributed to radiation therapy [29–31]. In this series, however, the only infarcts encountered were in children with chiasmal and/or hypothalamic tumors. In our experience, these tumors may encase and obliterate major vessels at the skull base in the absence of radiation therapy [26]. Thus, the infarcts in this series cannot definitely be attributed to radiation.

A synergistic effect on tissue has been described with radiation and ischemia [6, 9]. This was apparent in one child who developed extensive calcification in infarcted tissue after radiation therapy.

Tumor induction from radiation therapy has a latency period of up to 15 years [32–36]; thus, the absence of new or secondary neoplasms in this series with a mean follow-up of 2.3 years is not surprising.

Radiation necrosis may result in frank disruption of the blood-brain barrier with contrast enhancement and mass effect mimicking tumor recurrence [21–22, 24, 37]. This was suspected but not documented in one patient in our series. The possibility exists that radiation necrosis may have been responsible for enhancing masses seen in children in this series who were not surgically reevaluated.

Of major significance is the clinical impact of the CT abnormalities identified. In the absence of detailed clinical testing, deficits cannot be clearly related to the abnormalities identified. The five children with deficits but with no evidence of residual or recurrent tumor were of concern and warrant further study.

In summary, in our series, adverse effects on nontumorous parenchyma by CT after radiation therapy in the pediatric population were not unusual. In this series, 39% of patients had white-matter abnormalities and/or calcifications whether

or not chemotherapy was administered. If atrophy is also considered, 73% of children evaluated had abnormalities unrelated to the tumor itself. Only two children received methotrexate; thus, a synergistic effect between methotrexate and radiation therapy cannot be implicated. Radiation therapy alone was the primary therapeutic modality associated with white-matter abnormalities and calcification. These abnormalities were more frequent and more severe in younger children, particularly those who received radiation therapy when they were younger than 3 years old.

ACKNOWLEDGMENT

The authors gratefully acknowledge the expert assistance of Francine Hollowell and photographer Joe Jackson.

REFERENCES

1. Danoff BF, Cowchock S, Marquette C, Mulgre W, Kramer S. Assessment of the long-term effects of primary radiation therapy for brain tumors in children. *Cancer* **1982**;49:1580–1586
2. Kun LE, Mulhern RK, Crisco J. Quality of life in children treated for brain tumors. Intellectual, emotional, and academic function. *J Neurosurg* **1983**;58:1–6
3. Gilbert HA, Kagen AR. Radiation damage to the nervous system. New York: Raven Press, **1980**
4. Bamford FN, Morris-Jones P, Pearson D, Ribeiro CG, Shalet SM, Beardwell CG. Residual disabilities in children treated for intracranial space-occupying lesions. *Cancer* **1976**;37:1149–1151
5. Eiser C. Intellectual abilities among survivors of childhood leukaemia as a function of CNS irradiation. *Arch Dis Child* **1978**;53:391–395
6. Kramer S, Southard ME, Mansfield CM. Radiation effect and tolerance of the central nervous system. *Front Radiat Ther Oncol* **1972**;6:332–345
7. Kramer S, Lee KF. Complications of radiation therapy: the central nervous system. *Semin Roentgenol* **1974**;11:75–83
8. Husain MM, Garcia JH. Cerebral radiation necrosis: vascular and glial features. *ACTA Neuropathol (Berl)* **1974**;36:331–385
9. Kramer S. The hazards of therapeutic irradiation of the central nervous system. *Clin Neurosurg* **1968**;15:301–318
10. Mahaley MS, Vogel FS, Burger P, Ghatak NR. Neuropathology of tissues from patients treated by the brain tumor study group. *Natl Cancer Inst Monogr* **1977**;46:77–82
11. Burger PC, Mahaley MS, Dudka L, Vogel FS. The morphologic effects of radiation administered therapeutically for intracranial gliomas. *Cancer* **1979**;44:1256–1272
12. Price RA, Jamieson PA. The central nervous system in childhood leukemia. II. Subacute leukoencephalopathy. *Cancer* **1975**; 35:306–318
13. Price RA, Birdwell DA. The central nervous system in childhood leukemia. III. Mineralizing microangiopathy and dystrophic calcification. *Cancer* **1978**;42:717–728
14. Pedersen H, Clausen N. The development of cerebral CT changes during treatment of acute lymphocytic leukemia in childhood. *Neuroradiology* **1981**;22:79–84
15. Mueller S, Bell W, Seibert J. Cerebral calcification associated with intrathecal methotrexate therapy in acute lymphocytic leukemia. *J Pediatr* **1976**;88:650–653
16. Kretzschmar K, Gutjahr P, Kutzner J. CT studies before and after CNS treatment for acute lymphoblastic leukemia and malignant non-Hodgkin's lymphoma in childhood. *Neuroradiology* **1980**;20:173–180
17. Kingsley DPE, Kendall BE. Cranial computed tomography in leukaemia. *Neuroradiology* **1978**;16:543–546
18. Arnold H, Kuhne D, Franke H, Grosch I. Findings in computerized axial tomography after intrathecal methotrexate and radiation. *Neuroradiology* **1978**;16:65–68
19. Peylan-Ramu N, Poplack DG, Pizzo PA, Adornata BT, DiChiro G. Abnormal CT scans of the brain in asymptomatic children with acute lymphocytic leukemia after prophylactic of the central nervous system with radiation and intrathecal chemotherapy. *N Engl J Med* **1978**;298:815–818
20. Wendling LR, Bleyer WA, DiChiro G, McIlvanie SK. Transient, severe periventricular hypodensity after leukemic prophylaxis with cranial irradiation and intrathecal methotrexate. *J Comput Assist Tomogr* **1978**;2:502–505
21. Wang A, Skias DD, Rumbaugh CL, Schoene WC, Zamani A. Central nervous system changes after radiation therapy and/or chemotherapy: correlation of CT and autopsy findings. *AJNR* **1983**;4:466–471
22. Shalen PR, Ostrow PT, Glass PJ. Enhancement of the white matter following prophylactic therapy of the central nervous system for leukemia. *Radiology* **1981**;140:409–412
23. Scotti G, Bracchi M, Masera G, Auriti L, De Grandi C, Uderzo C. Prophylactic treatment of the central nervous system in acute lymphoblastic leukemia. CT findings in 45 children off therapy. *Ital J Neurol Sci* **1981**;4:361–366
24. Kingsley DPE, Kendall BE. Review: CT of the adverse effects of therapeutic radiation of the central nervous system. *AJNR* **1981**;2:453–460
25. Price RA. Histopathology of CNS leukemia and complications of therapy. *Am J Pediatr Hematol Oncol* **1979**;1:21–30
26. Davis PC, Hoffman JC, Weidenheim KM. Large hypothalamic and optic chiasm gliomas in infants: difficulties in distinction. *AJNR* **1984**;5:579–585
27. Flament-Durand J, Ketelbant-Balasse P, Maurus R, Regnier R, Spehl M. Intracerebral calcifications appearing during the course of acute lymphocytic leukemia treated with methotrexate and x-rays. *Cancer* **1975**;35:319–325
28. Harwood-Nash DCF, Reilly BJ. Calcification of basal ganglia following radiation therapy. *AJR* **1970**;108:392–395
29. Wright TL, Bresnan MJ. Radiation-induced cerebrovascular disease in children. *Neurology* **1976**;26:540–543
30. Conomy JP, Kellermeyer RW. Delayed cerebrovascular consequences of therapeutic radiation. *Cancer* **1975**;36:1702–1708
31. Painter MJ, Chutorian AM, Hilal SK. Cerebrovasculopathy following irradiation in childhood. *Neurology* **1975**;25:189–194
32. Pearl GS, Mirra SS, Miles MI. Glioblastoma multiforme occurring 13 years after treatment of a medulloblastoma. *Neurosurgery* **1980**;6:546–551
33. Sandler DP, Comstock GW, Matanoski GN. Neoplasms following childhood radium irradiation of the nasopharynx. *JNCI* **1982**;68:3–8
34. Rubinstein AB, Shalit MN, Cohen ML, Zandbank U, Reichenthal E. Radiation-induced cerebral meningioma: a recognizable entity. *J Neurosurg* **1984**;61:966–971
35. Tiberin P, Maor E, Zaizov R, et al. Brain sarcoma of meningeal origin after cranial irradiation in childhood acute lymphocytic leukemia. *J Neurosurg* **1984**;61:772–776
36. Anderson JR, Treip CS. Radiation induced intracranial neoplasms: a report of three possible cases. *Cancer* **1984**;53:426–429
37. Mikhael MA. Radiation necrosis of the brain. Correlation between computed tomography, pathology and dose distribution. *J Comput Assist Tomogr* **1978**;2:71–80