

Are your **MRI contrast agents** cost-effective?

Learn more about generic **Gadolinium-Based Contrast Agents**.



FRESENIUS
KABI

caring for life

AJNR

Ophthalmopathy of Graves' disease: computerized volume measurements of the orbital fat and muscle.

G Forbes, C A Gorman, M D Brennan, D G Gehring, D M Ilstrup
and F Earnest, 4th

This information is current as
of April 18, 2024.

AJNR Am J Neuroradiol 1986, 7 (4) 651-656
<http://www.ajnr.org/content/7/4/651>

Ophthalmopathy of Graves' Disease: Computerized Volume Measurements of the Orbital Fat and Muscle

Glenn Forbes¹
 Colum A. Gorman²
 Michael D. Brennan²
 Dale G. Gehring^{1,3}
 Duane M. Ilstrup⁴
 Franklin Earnest IV¹

Pixel-calibrated volume measurements of muscle and fat in the bony orbit were made from CT scans of 72 patients with Graves' disease, with and without ophthalmopathy, to define characteristic changes present in clinical subgroups. Measurement abnormalities were detected in 87% of Graves' patients with clinically detectable ophthalmopathy and in 70% of hyperthyroid patients without clinical eye signs. Abnormal enlargement of the fat compartment in addition to muscle enlargement was found in 46% of patients with clinical ophthalmopathy; 8% of patients had only increased size of the fat compartment with normal muscle volumes. The ratio of muscle to fat and the volumes of orbital muscle and fat all varied widely in each clinical subgroup. Statistically significant ($p < 0.0001$) total muscle-volume increase (range = 3.68–17.06 cm³) and borderline significant ($p < 0.06$) fat-compartment increase (range = 6.05–22.63 cm³) were documented in all clinical subgroups. The degree of change of muscle and fat volumes was independent of the clinical group. Abnormal changes were found in the contralateral orbit in six of seven patients who appeared to have unilateral ophthalmopathy on clinical examination. A higher frequency of medial and inferior muscle enlargement was documented in all clinical subgroups.

The pathophysiology of the ophthalmopathy in Graves' disease (OGD) remains poorly understood [1, 2]. An unidentified pathogen or its mediator may induce the swelling and lymphocytic infiltration that produces proptosis and later the fibrosis that restricts the mobility of the extraocular muscles [3, 4]. Imaging studies have shown variable enlargement of the extraocular muscles [5–8], and enlargement of the retrobulbar fat spaces has been reported [9–11]. Ocular manifestations of Graves' disease may occur in patients without hyperthyroidism (euthyroid ophthalmic Graves' disease [EOGD]) as well as in those with controlled or uncontrolled hyperthyroidism [12]. Controversy continues, however, on whether the effects of the ocular pathogen or its mediator in Graves' disease are seen uncommonly within the overall population of Graves' disease patients or whether some degree of ophthalmopathy, perhaps detectable only by refined techniques, is present in the majority or all of these patients.

We recently reported the development of special CT techniques for measurement of small structural volumes in the orbit with a three-dimensional display based on previous techniques used for large-volume analysis [9, 13–18]. We have used these techniques in an attempt to answer several questions regarding OGD: (1) What is the frequency with which abnormal orbital changes can be measured in hyperthyroid patients with Graves' disease without clinically apparent eye involvement? (2) Can volumetric analysis of the retrobulbar space, compared with subjective image interpretation, increase the frequency with which the diagnosis of OGD can be made? (3) Are the orbital changes of EOGD different, in terms of muscle or fat involvement, from changes in patients with thyrotoxic OGD? (4) Are measurable changes present in the contralateral orbit in patients with clinically apparent unilateral OGD? (5) What is the frequency of orbital fat volume change in OGD?

Received May 13, 1985; accepted after revision December 31, 1985.

¹ Department of Diagnostic Radiology, Mayo Clinic and Mayo Foundation, Rochester, MN 55905. Address reprint requests to G. Forbes.

² Division of Endocrinology, Metabolism, and Internal Medicine, Mayo Clinic and Mayo Foundation, Rochester, MN 55905.

³ Information Processing and Systems, Mayo Clinic and Mayo Foundation, Rochester, MN 55905.

⁴ Department of Medical Statistics and Epidemiology, Mayo Clinic and Mayo Foundation, Rochester, MN 55905.

AJNR 7:651–656, July/August 1986
 0195–6108/86/0704–0651

© American Society of Neuroradiology

Methods

All examinations were performed with a GE 8800 system. Thirty to 40 1.5-mm adjacent axial slices were taken at 0° to -10° from the orbitomeatal baseline to cover the entire orbital region. Off-axis reformatting perpendicular and parallel to the muscle cone axis was obtained in each orbit. Computer digital data from the patient examinations were transferred by tape to a stand-alone system for off-line analysis. Volumes of the muscle and fat compartments were obtained through summated pixel counts of each muscle and fat compartment as described [9, 13].

Physical phantoms and a dry skull fitted with predetermined volumes of barium-impregnated Silastic to simulate orbital structures were used to determine the accuracy of the technique.

Techniques for boundary determination and density range settings that were perfected from phantom studies were uniformly used in all patient studies. For determining muscle-pattern distributions, pixel counts were obtained from reformatted views of individual superior, inferior, medial, and lateral rectus groups incorporating levator and oblique muscles in superior and inferior groups.

Statistical analysis was applied to muscle and fat volumes correlated with normal controls and Graves' disease patients. Patients were arbitrarily considered to have abnormal measurements if their orbital fat or muscle volumes exceeded 2 SD above the mean for normal controls. These limits should be used only for this study. A much larger sample of normal patients would be needed to estimate the true upper limits (97.5 percentile) in healthy patients.

The study group consisted of 22 normal persons and 72 patients (48 women and 24 men, 15-77 years old) with OGD. Patients referred for orbital imaging because of unusual field cuts or scotoma who had no history or findings to suggest thyroid disease were used as normal controls. The OGD group consisted of: (1) 17 untreated hyperthyroid patients with gradations of ophthalmopathy from lid lag and restricted gaze (extraocular muscle-motion restriction) to prominent proptosis (group 1); (2) 10 untreated hyperthyroid patients without clinically apparent eye findings (group 2); (3) 23 euthyroid patients with no history or findings of hyperthyroidism but who had eye symptoms clinically indicative of endocrine ophthalmopathy (group 3); and (4) 22 treated hyperthyroid patients who are now euthyroid or hypothyroid, with or without replacement therapy after thyroidectomy, ¹³¹I, or antithyroid drugs, but with symptoms of ophthalmopathy (group 4) [19, 20]. Based on clinical eye examination, seven of the 72 patients apparently had unilateral proptosis.

Results

The mean values for muscle volume in the right and left orbits are given in Table 1. The total group of patients with clinically apparent eye disease had a definite increase in extraocular muscle volume compared with normal controls ($p < 0.0001$) (Fig. 1). In hyperthyroid patients without eye manifestations, mean muscle volume was slightly increased ($p < 0.06$). The other patient subgroups all had significantly greater muscle volume compared with normal (Fig. 2). Muscle volume differed only slightly from normal when patients with hyperthyroidism without overt ophthalmopathy were considered as a group. However, four in this group had muscle volumes more than 2 SD beyond the normal mean (Table 2).

The mean values for fat volume in the right and left orbits are given in Table 3. The mean for all groups as a whole showed borderline significance ($p < 0.06$) for fat-compartment increase (Fig. 3). Taken separately, the subgroup of treated hyperthyroid patients showed statistical significance ($p <$

TABLE 1: Muscle Measurements

	Mean (cm ³)		Range (cm ³)	<i>p</i> for Difference from Normal	No. Above Upper Limit of Normal ^a
	Right	Left			
Normal male	4.98	4.97	3.07-6.80	—	—
Normal female	4.68	4.70	3.66-6.20	—	—
Group 1	8.52	8.35	4.26-21.57	<0.004	14
Group 2	5.99	5.67	3.50-9.10	<0.06	4
Group 3	7.38	7.55	3.80-16.15	<0.0003	16
Group 4	8.53	8.52	4.55-17.06	<0.0001	20
Total	7.81	7.75	3.50-21.57	<0.0001	54

Note.—See text for group descriptions and totals. All patients' values are adjusted for gender.

^a Upper limit: 6.8 cm³ for men; 6.2 cm³ for women.

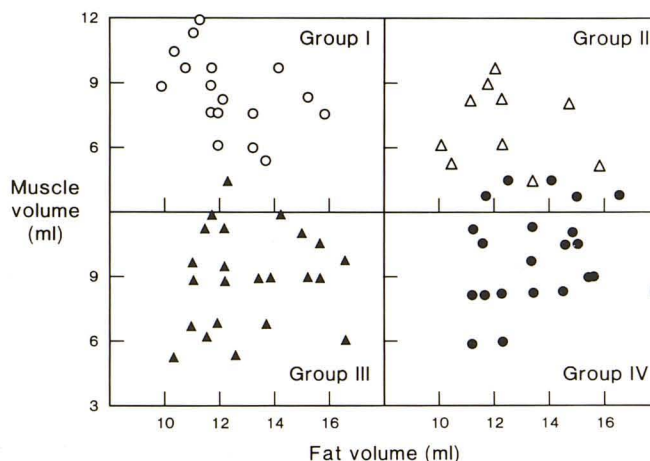


Fig. 1.—Muscle and fat enlargement by clinical group. Note random distribution of muscle and fat enlargement. Open circles, group 1; open triangles, group 2; closed triangles, group 3; closed circles, group 4.

0.004) for fat increase. Changes in fat volume in the hyperthyroid patients with eye manifestations and the euthyroid group were of borderline significance ($p < 0.05$ and $p < 0.10$), and the patients who had hyperthyroidism without eye manifestations showed no difference from normal. Several patients in each group had individual measurements more than 2 SD beyond the normal mean (Table 2).

An abnormal measurement for muscle or fat did not always result in abnormal total volume nor was it always associated with clinical proptosis. Of the 61 patients with some measurement abnormality, 47 had abnormal total volumes of soft tissue. In 14 patients there was an abnormal muscle or fat volume measurement, but the overall total volume still fell within normal limits. The group of patients with some measurement abnormality consisted of those with enlargement of muscle only (24 patients), of fat compartment only (seven patients), or of both (30 patients) (Fig. 4).

Seven patients distributed among the four groups had unilateral proptosis on clinical examination. In six of these seven patients, volume studies gave abnormal results in both the clinically abnormal orbit and the contralateral orbit. The results were within normal limits in the seventh patient, although there was a difference between the right and left orbits and this resulted in a subjective impression that the scan was positive. The six patients with abnormal results all

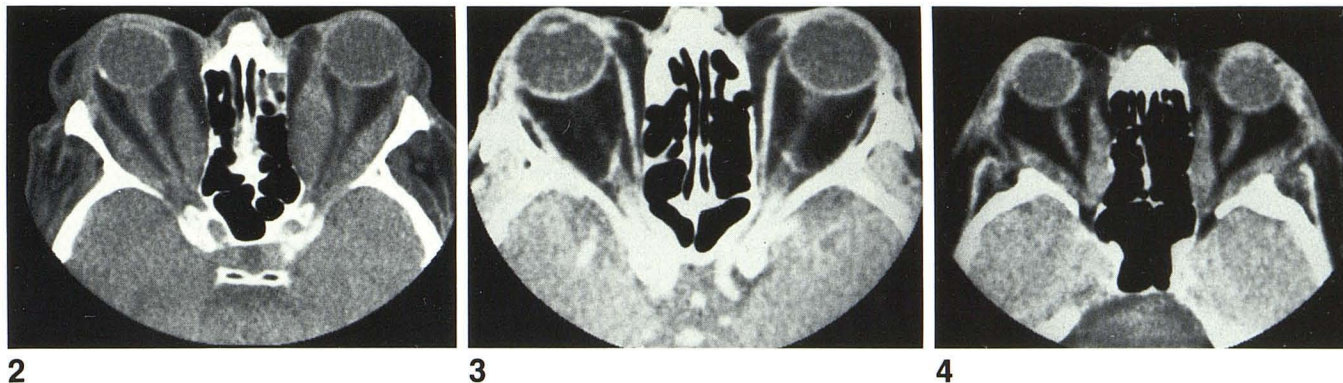


Fig. 2.—Muscle enlargement. Characteristic spindle-shaped enlargement of muscle bundles is present with tapering to normal-sized tendon at site of attachment. Enlarged muscles are isodense and produce slight distortion of optic nerve, early expansion of medial orbital wall, and marked bilateral proptosis. Total muscle volume: 17.1 cm³ (right) and 16.3 cm³ (left).

Fig. 3.—Fat enlargement. Bilateral proptosis is produced by expansion of fat compartment (see text). Muscles are not significantly enlarged. Increase in

fat space occurs in both intraconal and extraconal compartments. Fat volume: 20.2 cm³ (right) and 20.1 cm³ (left). Muscle volume: 8.9 cm³ (right) and 9.3 cm³ (left).

Fig. 4.—Enlargement of muscle and fat. Marked bilateral proptosis is due to enlargement of both muscle and fat compartments in each orbit. Comparison with Figs. 2 and 3 demonstrates characteristics of both the muscle and the fat changes. Total fat and muscle volume: 30.8 cm³ (right) and 31.4 cm³ (left).

TABLE 2: Distribution of Measurement Abnormalities

Patient Group*	No. of Patients	Measurement Abnormality Present	Total Soft-Tissue Volume Abnormal ^a	Fat Volume Abnormal ^a	Muscle Volume Abnormal ^a	Image Abnormal ^b
1	17	16	14	7	14	16
2	10	7	3	3	4	4
3	23	18	12	10	16	15
4	22	20	18	13	20	20
Total	72	61	47	33	54	55

* See text for group descriptions.
^a Abnormality is defined as a value more than 2 SD of the normal mean (corrected for gender).
^b Abnormality defined as image demonstrating any of the recognized signs of ophthalmopathy of Graves' disease, including single muscle enlargement.

TABLE 3: Fat Measurements

	Mean (cm ³)		Range (cm ³)	p for Difference from Normal	No. Above Upper Limit of Normal ^a
	Right	Left			
Normal male	10.78	11.13	8.56–14.00	—	—
Normal female	9.93	10.27	8.22–12.20	—	—
Group 1	12.35	12.03	7.67–22.63	<0.05	7
Group 2	10.22	9.88	3.77–16.39	NS	0
Group 3	11.88	12.12	6.14–20.15	<0.10	10
Group 4	13.04	13.20	6.05–22.36	<0.004	13
Total ^b	12.12	12.12	3.77–22.63	<0.06	33

Note.—See text for group descriptions and totals. All patients' values are adjusted for gender.
^a Upper limit: 12.85 cm³ for men; 12.20 cm³ for women.
^b Includes 19 men and 14 women.

had increased muscle volumes on the side of clinical proptosis. Two also had increased muscle volume on the contralateral side. Three had increased fat on the side of clinical proptosis; four had increased fat on the contralateral side also. The total volumes were increased bilaterally in five and were within normal limits in two.

Of 144 orbits evaluated in patients with Graves' disease, 101 orbits had muscle enlargement—bilateral in 47 patients

and unilateral in seven. The most common patterns were: (1) all muscles enlarged, (2) only one muscle enlarged, and (3) both medial and inferior rectus groups enlarged (Table 4). The medial and inferior rectus muscle groups were the groups most frequently enlarged. Enlargement of the lateral rectus group was the least frequent and was never found as an isolated change. No specific distribution pattern correlated with the clinical subgroups. No difference was found in patterns between men and women.

The mean volume of the bony orbit in patients with Graves' disease was 22.45 ml in females and 29.15 ml in males. No overall difference between the right and left orbit was detected. Previously reported ranges for normal orbit volume are 21.58–29.43 ml in females and 16.18–30.11 in males [13].

There was bowing and expansion of the medial bony orbit wall as a consequence of chronic pressure of the muscle groups in seven patients (three men and four women). In all seven, the adjacent medial rectus group was markedly enlarged and the total soft-tissue volumes of the orbits were at the high end of the abnormal range (mean = 27.4 ml). This expansion of the medial wall showed no correlation with a clinical subgroup of endocrine disease.

By two radiologic subjective interpretations, characteristic changes were present on the CT images in 50 (80%) patients who had clinical eye signs. An abnormality was detected on the radiographs in two cases in which the volume measurements were within normal limits. No intracranial abnormalities were detected in any of the cases. Two patients had minimal membrane thickenings in the sinuses from chronic inflammatory disease.

Discussion

Subjective interpretation of high-resolution images produced by late-generation scanning techniques revealed characteristic CT changes in 82% of our Graves' disease patients with clinical ophthalmopathy. Quantitative volume analysis

TABLE 4: Patterns of Muscle Enlargement in Patients with Graves' Disease

Orbits	No. with Involvement	No. by Individual Muscle Group Involved (%) ^a			
		Medial	Lateral	Superior	Inferior
Total with muscle enlargement	101	54 (75)	17 (24)	38 (53)	57 (79)
Common Patterns					
All muscles enlarged	19	—	—	—	—
One muscle enlarged	17	7 (10)	0	2 (3)	4 (6)
Both medial and inferior muscle groups enlarged	13	—	—	—	—

^a Percentages represent the fraction of patients with that particular muscle-enlargement pattern compared with all 72 patients in the study group.

revealed measurement abnormalities in 87% of the same group with ophthalmopathy (values more than 2 SD from the normal mean were considered abnormal). This difference is not considered to be significant for clinical purposes, particularly because some abnormalities are better detected by radiographic observation and vice versa. Many thyrotoxic Graves' disease patients and those who were euthyroid with clinically obvious eye disease had recognizable abnormalities on the CT scan. In some, the abnormalities were confined to a single muscle group, in which case the subjective interpretation is most helpful. More diffuse involvement is better recognized by volume analysis.

In our small sample, abnormalities in volume measurements were present in 70% of patients who had Graves' disease without significant clinical eye manifestations, indicating that early detection of ophthalmopathy may be possible with increasingly sensitive techniques. This had first been shown by Enzmann et al. [5], who found CT changes in up to 40% of asymptomatic patients with Graves' disease by using earlier scanning techniques. Finding abnormal volume measurements in the contralateral orbit of six of our seven patients with unilateral proptosis supports the concept of an infiltrative process from a systemic disease affecting both orbits, albeit unevenly. Although expansion of the medial orbital wall was seen in 7% of the cases, no overall change in bony orbit volume or differences between right and left bony orbit were detected in Graves' disease patients, when taken as a whole.

The significant tendency toward medial and inferior muscle enlargement in our group supports the findings of similar distribution patterns reported by Enzmann et al. [5]. Although the inferior muscle group is difficult to distinguish from the orbital floor on axial views, the use of coronal and other reformatted images frequently will show change in this muscle group (Figs. 5 and 6). This pattern was commonly seen in each of our clinical subgroups. Early infiltration of these muscle groups has also been recognized clinically by careful observation of eye movements in suspected cases of endocrine ophthalmopathy.

Although muscle enlargement from cellular infiltration has long been recognized as a major component of endocrine ophthalmopathy, changes in the orbital fat compartment have

been less well understood. In our group, 46% of patients with clinical ophthalmopathy had abnormal enlargement of the fat compartment in addition to muscle enlargement and 8% of patients had increased size of the fat compartment only, with muscle volumes within normal limits. We suspect that more than one causative mechanism is operating to increase the fat compartment because we found such increases both with and without associated muscle enlargement. The mean orbital fat volume for all of our clinical subgroups of Graves' disease was above the normal mean to a level of borderline statistical significance (Fig. 7).

Others have commented on orbital fat changes as observed by different techniques with various interpretations that might appear confusing until one recognizes that different components of the supporting tissues are being examined by each method. Rundle and Pochin [21] first reported finding increased orbital fat volume at autopsies of patients with thyrotoxic Graves' disease. Werner et al. [8] later suggested that the fatty bulk observed by Rundle and Pochin might have represented postinflammatory tissue replacement associated with thyrotoxicosis. Smelser [22] had earlier indicated that fat tissue was actually replaced by connective tissue in Graves' disease, a finding supported by Riley [23], who did histologic analysis of fat removed during the course of orbital decompression. Riley [23] found focal accumulation of inflammatory lymphocytes and increased ground substance, presumably mucopolysaccharide. Both Trokel and Jakobiec [11] and Yamamoto et al. [24] referred to the appearance, on CT scans and sonograms, respectively, of increased orbital fat in some patients with Graves' disease.

Although analysis of postmortem or surgical biopsy tissue cannot relate to overall changes in fat volume, such results do indicate that volume change does not necessarily indicate an increase or enlargement of adipocytes. Other mechanisms must be considered, including increased hydration from an osmotic effect of the mucopolysaccharide ground substance and vascular congestion from venous stasis due to anatomic crowding at the orbital apex. Interstitial edema has long been recognized as a component of the infiltrative change in orbits of patients with Graves' disease [25, 26].

Other methods have been used in smaller groups to assess orbital structure volumes in Graves' disease. Yamamoto et al. [24] used B-mode sonography to measure orbital muscle volume in 31 Graves' disease patients and six normal controls. Although no phantom studies were performed to establish the accuracy of their technique, the ranges found for normal and abnormal values were similar to those found by off-line CT analysis. In their six normal Japanese controls, the mean for the unilateral orbital muscle volume was 3.32 ± 1.31 cm³ and total bony orbit volume range was 24.0–26.7 cm³. The mean unilateral orbital muscle volume in patients with Graves' disease was 6.57 ± 2.70 cm³. However, orbit volumes of Japanese and white subjects have never been compared directly by using the same technique.

Feldon and Weiner [27] used a cursor to trace muscle contours in either 5- or 1.5-cm slices from eight CT scans of patients with Graves' disease to estimate muscle volumes. Although no phantom studies were reported to indicate the

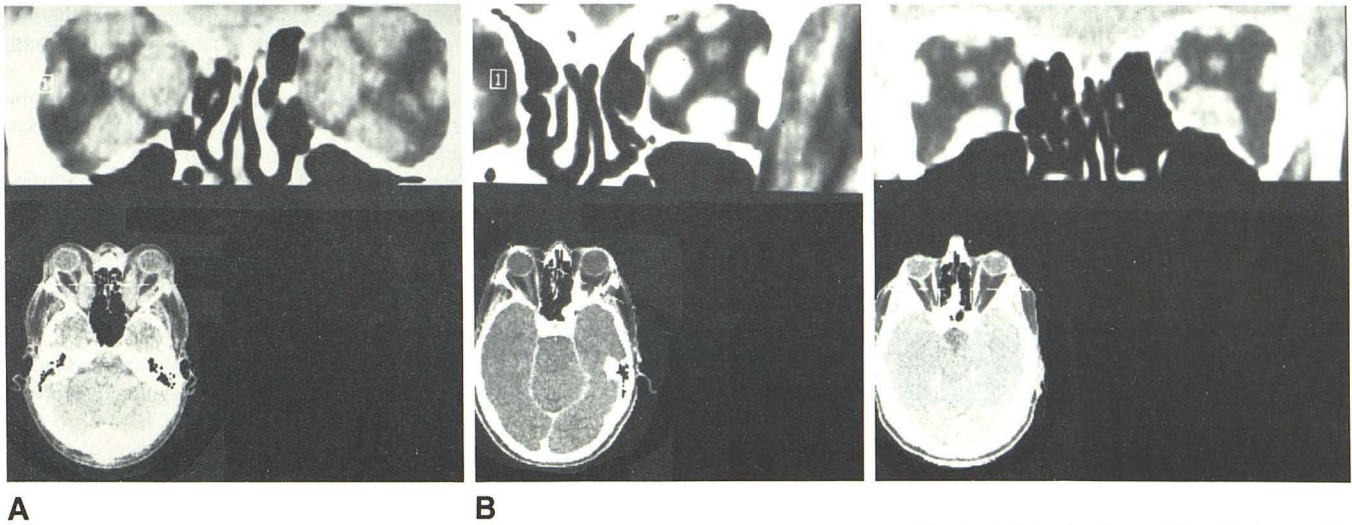


Fig. 5.—Characteristic patterns. If two or more muscles are enlarged, the medial, inferior, and superior groups are involved in that order. Note relative sparing of lateral rectus in both A and B, which is usually last to become enlarged after other groups are affected.

Fig. 6.—Individual patterns. Either inferior, medial, or superior muscle group may become individually enlarged as an isolated muscle finding, in that order of frequency. Isolated inferior muscle enlargement usually requires multiple reformatted views for proper detection. Coronal sections demonstrate isolated inferior rectus muscle enlargement.

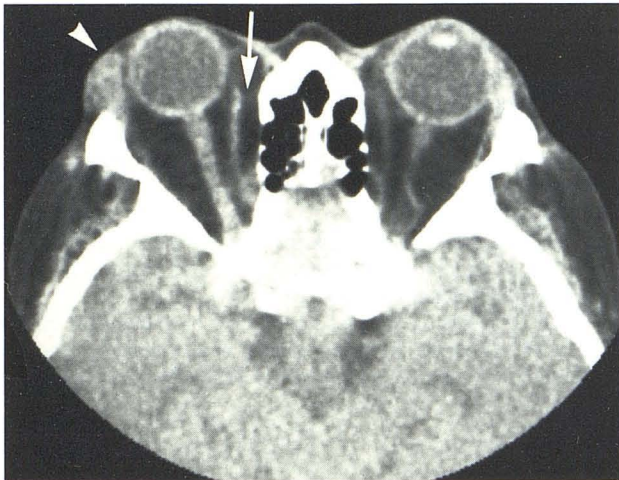


Fig. 7.—Fat and lacrimal gland. Enlargement of periorbital tissues and gland in lacrimal fossa may be seen as first reported by Trokel and Hillal [10] (arrowhead). Excessive fatty tissue in extraconal compartment between medial rectus and superior oblique and medial orbital wall may be seen if there is general increase in fat compartment (arrow).

accuracy of this method, they found a quantitative increase in the muscle volume, compared with four normal controls, that correlated with the degree of clinical ophthalmopathy.

The accuracy of any quantitative method must be taken into account when estimating the degree of volume change necessary to produce clinical proptosis. Certain assumptions have been made in comparing orbit volumes in Graves' disease patients with normal controls. Small neurovascular chan-

nels are isodense in CT imaging and thus are averaged into muscle bundles in volume measurements. Because the anterior border of the orbit is open, it is subject to different definitions of boundary. As we described in an earlier report [13], an 8% increase in soft-tissue volume would be necessary to provide reliable measurement of ophthalmopathy with this computer method in an individual subject, and increases of at least 11% and 17% would be necessary to detect ophthalmopathy on the basis of only fat or muscle change, respectively.

CT is established as a standard for imaging examinations in OGD. The characteristic changes that provide the diagnosis can be differentiated from those of most other orbital problems. The extent of orbital involvement can be assessed reliably with high-resolution CT. Future work should be directed toward correlation of the wide spectrum of patterns with clinical subgroups and continued analysis of the ground-substance changes. The nature of the pathologic change in ground substance may lend itself well to the potentially greater specificity of MRI.

In summary, measurements of the orbital soft-tissue volume demonstrate a higher frequency of abnormal changes in hyperthyroid patients with Graves' disease without clinically apparent eye involvement than previously reported. Volumetric analysis of the retrobulbar space complements but does not significantly increase the frequency with which the diagnosis of OGD can be made. No statistically significant difference was found in terms of muscle- or fat-volume changes in patients with euthyroid ophthalmopathy compared to thyrotoxic ophthalmopathy. Almost all patients with clinically apparent unilateral ophthalmopathy were found to have some measurable abnormality in the contralateral eye with volu-

metric analysis. Almost half of all patients with OGD had a measurable increase in the orbital fat compartment volume with or without concomitant muscle-volume increase.

REFERENCES

- Gorman CA. Ophthalmopathy of Graves' disease (editorial). *N Engl J Med* **1983**;308:453-454
- Gorman CA. Temporal relationship between onset of Graves' ophthalmopathy and diagnosis of thyrotoxicosis. *Mayo Clin Proc* **1983**;58:515-519
- Kodama K, Sikorska H, Bandy-Dafoe P, Bayly R, Wall JR. Demonstration of a circulating autoantibody against a soluble eye-muscle antigen in Graves' ophthalmopathy. *Lancet* **1982**; 2:1353-1356
- Jensen SF. Endocrine ophthalmoplegia: is it due to myopathy or to mechanical immobilization? *Acta Ophthalmol (Copenh)* **1971**;49:679-684
- Enzmann DR, Donaldson SS, Kriss JP. Appearance of Graves' disease on orbital computed tomography. *J Comput Assist Tomogr* **1979**;3:815-819
- Forrester JV, Sutherland GR, McDougall IR. Dysthyroid ophthalmopathy: orbital evaluation with B-scan ultrasonography. *J Clin Endocrinol Metab* **1977**;45:221-224
- Coleman DJ, Jack RL, Franzen LA, Werner SC. High resolution B scan ultrasonography of the orbit. V. Eye changes of Graves' disease. *Arch Ophthalmol* **1972**;88:465-471
- Werner SC, Coleman DJ, Franzen LA. Ultrasonographic evidence of consistent orbital involvement in Graves' disease. *N Engl J Med* **1974**;290:1447-1450
- Forbes G, Gorman C, Gehring D, Baker HL. Computer analysis of orbital fat and muscle volumes in Graves' ophthalmopathy. *AJNR* **1983**;4:737-740
- Trokel SL, Hilal MK. Recognition and differential diagnosis of enlarged extraocular muscles in computed tomography. *Am J Ophthalmol* **1979**;87:503-512
- Trokel SL, Jakobiec FA. Correlation of CT scanning and pathologic features of ophthalmic Graves' disease. *Ophthalmology (Rochester)* **1981**;88:553-564
- Volpé R. The thyroid. In: Spittell JA Jr, ed. *Clinical medicine*, Vol. 8. Philadelphia: Harper & Row, **1984**:1-70
- Forbes G, Gehring DG, Gorman CA, Brennan MD, Jackson IT. Volume measurements of normal orbital structures by computed tomographic analysis. *AJNR* **1985**;6:419-424, *AJR* **1985**; 145:149-154
- Bite U, Jackson IT, Forbes GS, Gehring DG. Orbital volume measurements in enophthalmos using three-dimensional CT imaging. *Plast Reconstr Surg* **1985**;75:502-507
- Brenner DE, Whitley NO, Houk TL, Aisner J, Wiernik P, Whitley J. Volume determinations in computed tomography. *JAMA* **1982**;247:1299-1302
- Heymsfield SB, Fulenwider T, Nordlinger B, Barlow R, Sones P, Kutner M. Accurate measurement of liver, kidney, and spleen volume and mass by computerized axial tomography. *Ann Intern Med* **1979**;90:185-187
- Moss AA, Friedman MA, Brito AC. Determination of liver, kidney, and spleen volumes by computed tomography: an experimental study in dogs. *J Comput Assist Tomogr* **1981**;5:12-14
- Keller J, Edwards FM, Rundle R. Automatic outlining of regions on CT scans. *J Comput Assist Tomogr* **1981**;5:240-245
- Werner SC. Classification of the eye changes of Graves' disease (letter to the editor). *J Clin Endocrinol Metab* **1969**;29:982-984
- Werner SC. Modification of the classification of the eye changes of Graves' disease: recommendations of the ad hoc committee of the American Thyroid Association (letter to the editor). *J Clin Endocrinol Metab* **1977**;44:203-204
- Rundle FF, Pochin E. The orbital tissues in thyrotoxicosis: a quantitative analysis relating to exophthalmos. *Clin Sci* **1944**; 5:51-74
- Smelser GK. A comparative study of experimental and clinical exophthalmos. *Am J Ophthalmol* **1937**;20:1189-1203.
- Riley FC. Orbital pathology in Graves' disease. *Mayo Clin Proc* **1972**;47:975-979
- Yamamoto K, Itoh K, Yoshida S, et al. A quantitative analysis of orbital soft tissue in Graves' disease based on B-mode ultrasonography. *Endocrinol Jpn* **1979**;26:255-261
- Kroll AJ, Kuwabara T. Dysthyroid ocular myopathy: anatomy, histology, and electron microscopy. *Arch Ophthalmol* **1966**; 76:244-257
- Tengroth B. Histological studies of orbital tissues in a case of endocrine exophthalmos before and after remission. *Acta Ophthalmol (Copenh)* **1964**;42:588-591
- Feldon S, Weiner J. Clinical significance of extraocular muscle volumes in Graves' ophthalmopathy: a quantitative computed tomography study. *Arch Ophthalmol* **1982**;100:1266-1269