

Are your **MRI contrast agents** cost-effective?

Learn more about generic **Gadolinium-Based Contrast Agents**.



FRESENIUS
KABI

caring for life

AJNR

MRI of an aneurysm of the vein of Galen.

N Roosen, M Schirmer, E Lins, W J Bock, W Stork and D Gahlen

AJNR Am J Neuroradiol 1986, 7 (4) 733-735

<http://www.ajnr.org/content/7/4/733.citation>

This information is current as
of April 17, 2024.

MRI of an Aneurysm of the Vein of Galen

Norbert Roosen,¹ Michael Schirmer,¹ Evaldo Lins,¹ Wolfgang J. Bock,¹ Wolfgang Stork,² and Dorothee Gahlen²

Arteriovenous malformations of the vein of Galen are rare, usually presenting with cardiac failure in infancy or with hydrocephalus and raised intracranial pressure in older children [1]. Computed tomographic (CT) and angiographic features are well known [2, 3]. Magnetic resonance imaging (MRI), however, is a new imaging modality, and experience with aneurysms of the vein of Galen is not yet available.

Case Report

A 4-month-old baby boy developed clinical signs of intracranial hypertension. Pregnancy, delivery, and neonatal development had been uneventful apart from progressive macrocrania. The child was admitted to the Hospital of the University of Düsseldorf. Clinical examination showed macrocrania, sunset sign, enlarged tense fontanels, and prominent scalp veins. There was no bruit on auscultation of the head. The baby was adynamic and vomited. Cardiac failure was not present.

Skull X-rays revealed diastatic sutures. Sonography demonstrated extreme hydrocephalus of both lateral ventricles and suggested a "cystic" midline lesion, which extended somewhat to the left.

CT confirmed the hydrocephalic enlargement of the lateral and third ventricles (Fig. 1). A large, slightly hyperdense midline lesion was located in the pineal region. After intravenous injection of contrast medium, dense enhancement ensued (Fig. 1).

After ventriculoperitoneal shunting of cerebrospinal fluid, an MRI exam was performed using a Disonics MT/S superconductive magnetic resonance imager operating at 0.35 T with multislice technique. Images obtained using spin-echo sequences (TR 1.5 and 2.0 sec; TE 28 and 56 msec) showed a large lesion with smooth contours (Fig. 2). Significant differences were demonstrated on TE 28 msec and TE 56 msec images. As seen on TE 28 msec, the lesion was almost completely devoid of signal. On images obtained at TE 56 msec, greater signal heterogeneity was clearly detected.

Vertebral and bilateral carotid angiography was performed (Fig. 3), and demonstrated a giant aneurysm of the vein of Galen, fed by enlarged branches of the right carotid and the vertebrobasilar arteries. A jet of arterial blood entered the malformation, and afterward there was stasis of the contrast material within the aneurysm.

Surgery was performed to ligate feeding arteries. Postoperatively, the clinical course was one of progressive deterioration due to predominantly right hemispheric hyperemic hemorrhage. The patient died on the 10th postoperative day. Permission for autopsy was not obtained.

Discussion

Aneurysm of the vein of Galen is a well-known clinicopathologic entity with clearly defined CT and angiographic features [1-3]. Digital subtraction angiography has been proposed as a diagnostic alternative to conventional angiography [4, 5]. Sonography is a valuable screening method in the young child before closure of the fontanels [5, 6].

MRI was diagnostic of Galenic vein aneurysm in our case. The jetlike arterial filling of the aneurysm with turbulence and the relative stasis of blood within other parts of the malfor-

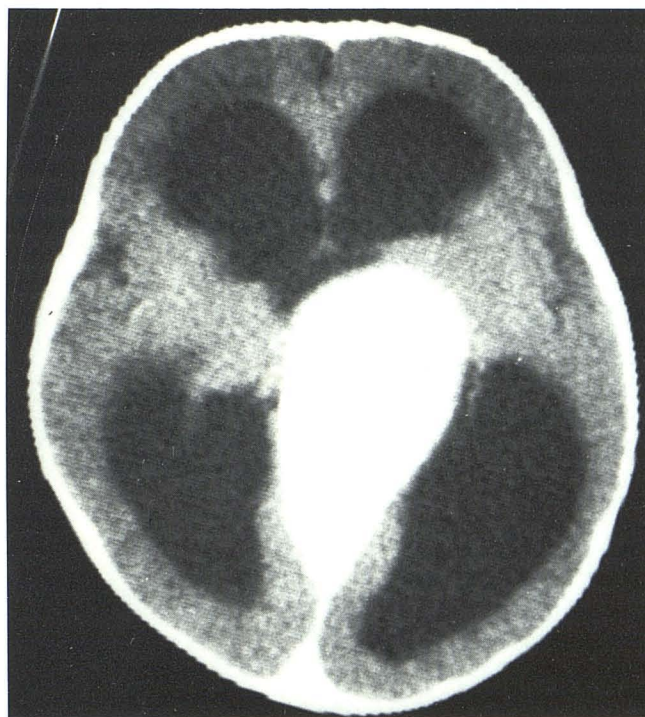

Fig. 1.—Obstructive hydrocephalus caused by large midline lesion, which was discretely hyperdense on nonenhanced CT and showed intensive enhancement after IV contrast injection.

Received August 9, 1985; accepted after revision December 10, 1985.

¹ Neurosurgical Clinic, Hospital of the University of Düsseldorf, Moorenstrasse 5, 4000 Düsseldorf 1, Federal Republic of Germany. Address reprint requests to N. Roosen.

² Institute of Roentgenology, Grafenberger Allee 63, 4000 Düsseldorf 1, Federal Republic of Germany.

AJNR 7:733-735, July/August 1986 0195-6108/86/0704-0733 © American Society of Neuroradiology

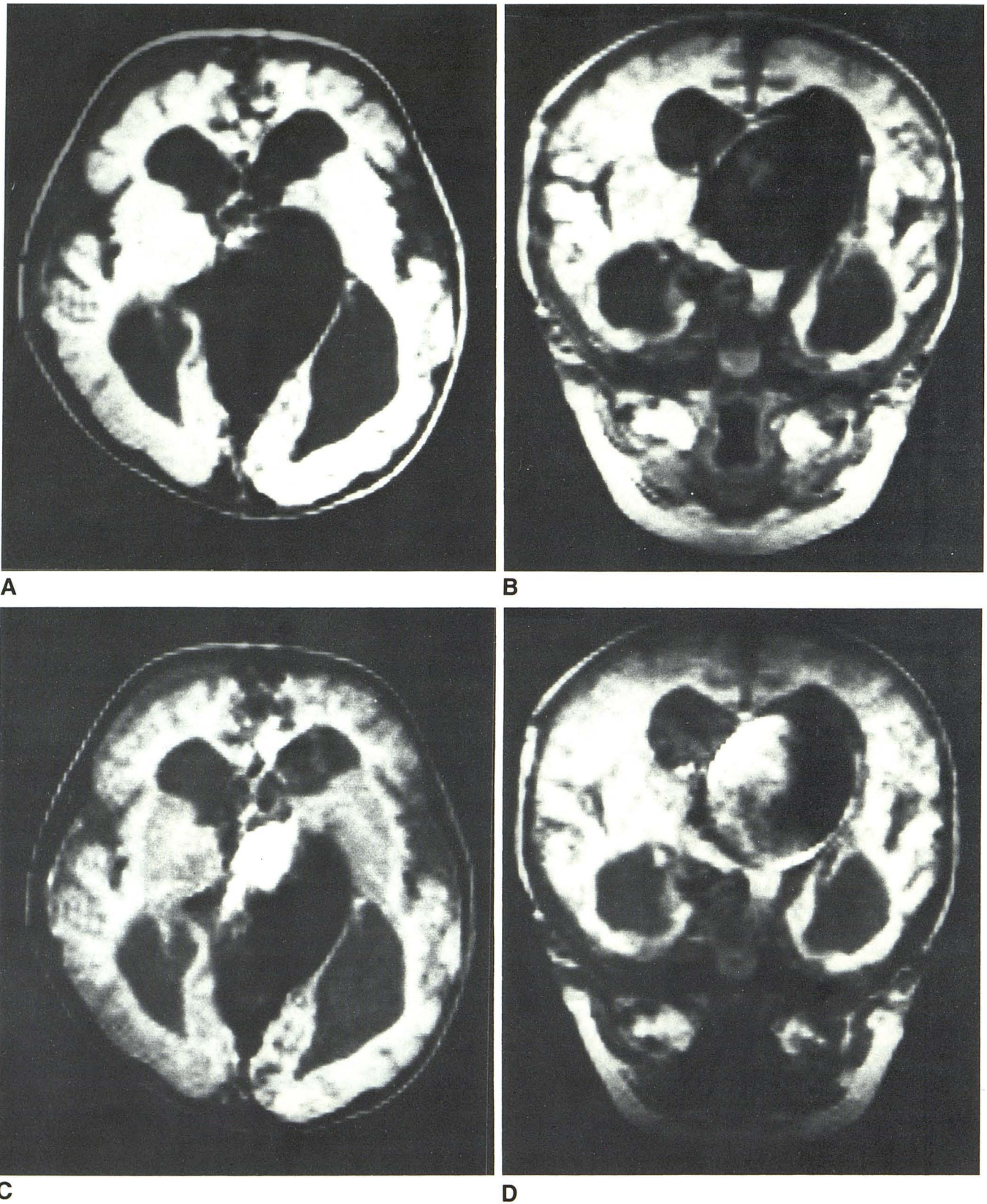
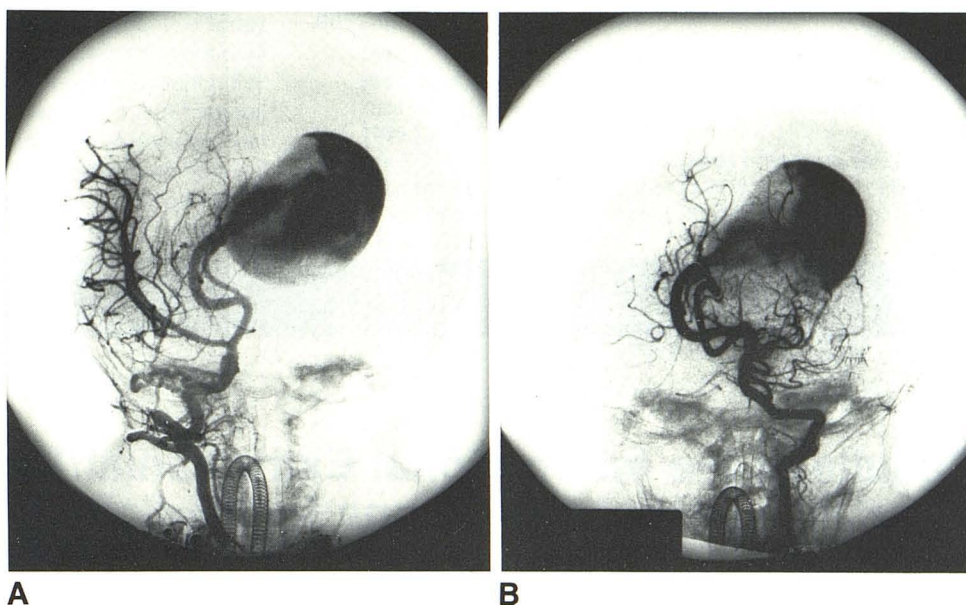


Fig. 2.—Axial, **A**, and coronal, **B**, MR sections (SE and TR 2.0 sec and 1.5 sec, respectively; TE 28 msec) demonstrate different signal intensities within large, ovoid malformation. The hyperintense part of largely hypointense lesion

correlates well with arterial jet of blood entering aneurysm (see Fig. 3); this is more evident on TE 56 msec images, **C** and **D** (SE and TR 2.0 sec and 1.5 sec, respectively; TE 56 msec).

Fig. 3.—Anteroposterior views of right internal carotid angiogram, **A**, and left vertebral angiogram, **B**. Large aneurysm of vein of Galen is fed by two hypertrophied arteries, which drain blood from basilar artery and, by way of right posterior communicating artery, from right internal carotid artery. The arterial jet of blood entering malformation and causing considerable turbulence is clearly depicted. This can be correlated with the hyperintense zone noted on MR scans (see Fig. 2, C and D).



mation, as demonstrated by angiography, resulted in different signal intensities within the lesion. This difference was much more apparent in the images obtained at TE 56 msec than at TE 28 msec. The short TE images were almost completely devoid of signal, whereas the T2-weighted images (SE 2000/56) show a region of high signal intensity within the lesion. This would be most unusual for an intravascular thrombus. Thus, the MR findings suggested the presence of turbulence and/or different velocities of the blood within the lesion. Owing to the phenomenon of cardiac pseudogating in the multislice technique, these high-intensity regions might represent high-velocity blood flow [7]. Indeed, in reviewing the different sections and comparing coronal with axial images, the high-intensity regions can be superimposed on the angiographically visualized trajectory of the pulsatile entry jet flow. Definite evaluation would have required an ECG-synchronized MR study.

Sensitivity of MRI for varying blood-flow rates and patterns within vascular lesions is known to be high, and it has been suggested that MRI should be used as the prime diagnostic modality in these cases, especially in children, because it precludes radiation exposure [8, 9]. MRI not only outlined the exact anatomical extent of the lesion in our patient, but was also diagnostic of aneurysm of the vein of Galen, clearly demonstrating the different blood-flow patterns within the malformation. This does not obviate, however, the need for a detailed angiographic examination, since the operative approach depends upon the precise identification of feeding arteries.

ACKNOWLEDGMENTS

We thank Ms. G. Hanke and Mrs. V. Konze from the Institute of Roentgenology for their valuable help in obtaining the MR scans of

this patient. Mrs. U. Hilbricht, Neurosurgical Clinic of the University of Düsseldorf, did the photographic work, which is gratefully acknowledged.

REFERENCES

1. Malis LI. Arteriovenous malformations of the brain. In: Youmans JR, ed. *Neurological surgery*, 2nd ed. Philadelphia: WB Saunders, 1982:1786-1806
2. Martelli A, Scotti G, Harwood-Nash DC, Fitz CR, Chuang SH. Aneurysms of the vein of Galen in children: CT and angiographic correlation. *Neuroradiology* 1980;20:123-133
3. Diebler C, Dulac O, Renier D, Ernest C, Lalande G. Aneurysms of the vein of Galen in infants aged 2 to 15 months. Diagnosis and natural evolution. *Neuroradiology* 1981;21:185-197
4. Carmody RF, Smith JRL, Seeger JF, Ovitt TW, Capp MP. Intracranial applications of digital intravenous subtraction angiography. *Radiology* 1982;144:529-534
5. Benz-Bohm G, Neufang KFR, Mennicken U. A.v. Missbildung im Bereich der Vena Galeni bei einem Neugeborenen. Nachweis durch Sonographie und digitale Subtraktionsangiographie. *Fortschr Röntgenstr* 1985;142:579-581
6. Cubberley DA, Jaffre RB, Nixon GW. Sonographic demonstration of Galenic arteriovenous malformations in the neonate. *AJNR* 1982;3:435-439
7. Bradley WG Jr, Waluch V. Blood flow: magnetic resonance imaging. *Radiology* 1985;154:443-450
8. Mills CM, Brant-Zawadzki M, Crooks LE, et al. Nuclear magnetic resonance: principles of blood flow imaging. *AJNR* 1983;4:1161-1166; *AJR* 1984;142:165-170
9. Ringertz HG, Brasch RC, Brody A, Ehman R, Gooding CA. Magnetic resonance imaging of vascular lesions in children. Assessment of flow patterns. *Acta Radiol [Diagn]* (Stockh) 1984;25:449-456