

Are your **MRI contrast agents** cost-effective?

Learn more about generic **Gadolinium-Based Contrast Agents**.



FRESENIUS
KABI

caring for life

AJNR

Percutaneous angioplasty of atherosclerotic and postsurgical stenosis of carotid arteries.

J Théron, J Raymond, A Casasco and F Courtheoux

AJNR Am J Neuroradiol 1987, 8 (3) 495-500

<http://www.ajnr.org/content/8/3/495>

This information is current as
of April 20, 2024.

Percutaneous Angioplasty of Atherosclerotic and Postsurgical Stenosis of Carotid Arteries

J. Théron^{1,2}
 J. Raymond^{1,3}
 A. Casasco²
 F. Courtheoux²

A technique for safe angioplasty of atherosclerotic stenosis of internal and common carotid arteries is described in which temporary balloon occlusion of the internal carotid artery is used to prevent cerebral embolization during manipulation of ulcerated plaques. Its successful use in six atherosclerotic stenoses is described. Five angioplasties of postsurgical stenoses are also reported in which the technique of temporary occlusion was not used. The future of carotid artery angioplasty is discussed.

Since its first description [1] and the introduction of double-balloon dilatation catheters [2], percutaneous transluminal angioplasty has become a well-established technique for treating arterial stenoses in various regions. Application of angioplasty to supraaortic arteries has lagged behind that in other regions [3-6]; only a few instances of angioplasty in atherosclerotic stenosis of the internal or common carotid artery have been reported [7-10], and the fear of dislodging an embolus from an ulcerative plaque [11] is still a common objection to this technique. We describe our experience with temporary distal balloon occlusion of the internal carotid artery to protect the cerebral circulation during angioplasty of six atherosclerotic carotid stenoses. Five postsurgical stenoses of the internal carotid artery, in which "cerebral protection" was not used, are also reported.

Materials and Methods

Eleven angioplasties were performed in six cases of atherosclerotic stenosis (in five patients) and in five cases of postsurgical stenosis.

In atherosclerotic stenoses, the common carotid artery was involved in two cases and the internal carotid artery in four. Three of these patients presented with ipsilateral transient ischemic attacks. In one of these patients a contralateral asymptomatic ulcerated stenosis was also treated. Another patient had repeated episodes of loss of consciousness. One patient was asymptomatic, and the lesion was discovered by Doppler sonography during a routine workup of patients with polyarteritis (Table 1).

All postsurgical stenoses involved the internal carotid artery in asymptomatic patients. The stenoses were detected by Doppler examination as part of a routine endarterectomy follow-up examination.

An bilateral femoral approach was used for angioplasty of atherosclerotic stenosis (Fig. 1A). An 0.8- by 1.8-mm latex balloon (Balt, Montmorency, France) attached to a 2-French 0.3- by 0.5-mm polyethylene catheter was introduced into the internal carotid artery via a 6-French guiding catheter (Cook, Bloomington, IN) and left in the common carotid artery. When the stenosis was at the carotid bifurcation (Fig. 1B), the balloon was positioned at the craniocervical junction. When the stenosis was located in the common carotid artery (Fig. 1C), the balloon was positioned at the origin of the internal carotid artery. An 8-French angioplasty catheter (Medi-Tech, Watertown, MA) with 8-mm balloon diameter was introduced through the contralateral femoral artery and positioned at the lesion over a straight guidewire. After systematic anticoagulation with 2000 IU of heparin [12], balloon occlusion of the internal carotid artery was performed. Tolerance to occlusion was assessed on the basis of consciousness, speech, and the ability to move the contralateral limbs. Any modification in the

Received August 20, 1986; accepted after revision December 9, 1986.

Presented at the annual meeting of the American Society of Neuroradiology, San Diego, January 1986.

¹ Department of Neuroradiology, Montreal Neurological Hospital, Montreal, Quebec H3A 2B4, Canada.

² Department of Neuroradiology, Centre Hospitalier Régional et Universitaire, Côte de Nacre, 14040 Caen, France. Address reprint requests to J. Théron.

³ Department of Radiology, Hôpital Saint-Luc, Montreal, Quebec H2X 3J4, Canada.

AJNR 8:495-500, May/June 1987
 0195-6108/87/0803-0495

© American Society of Neuroradiology

TABLE 1: Summary of Atherosclerotic Stenosis Treated by Angioplasty

Case No.	Symptoms	Preangioplasty			Postangioplasty		
		Lesion Location	% Stenosis	Ulceration	% Stenosis	Ulceration	Last Follow-up (months) ^a
1	TIA	CCA	80	No	10	No	18
2	TIA	CCA	80	Yes	10	No	15
3 ^b	TIA	ICA	98	No	20→5 ^c	No	14
	None	ICA	80	Yes	0	Irregularity	14
4	Recurrent loss of consciousness	ICA	90	No	0	No	16
5	None	ICA	80	No	10	No	12

Note.—TIA = transient ischemic attack; CCA = common carotid artery; ICA = internal carotid artery.

^a In no patients were there recurrent symptoms after the last follow-up.

^b There were two stenoses on opposite sides in case 3.

^c Immediate, 20%; 2 months later, 5%.

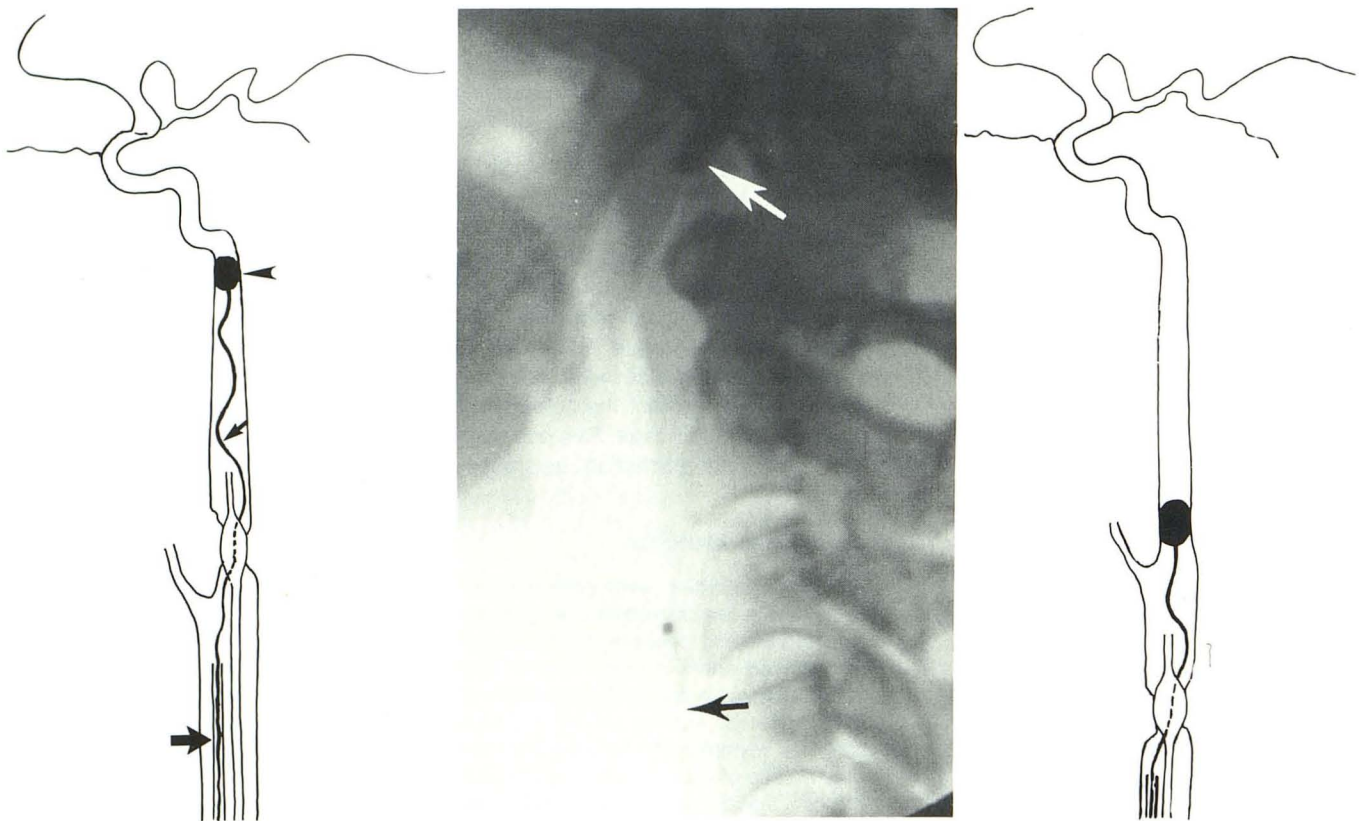


Fig. 1.—Technique of carotid artery angioplasty with temporary occlusion of internal carotid.

A, Guiding catheter (*large arrow*) is positioned in common carotid artery. Small polyethylene catheter (*small arrow*) with nondetachable balloon (*arrowhead*) is introduced into internal carotid. During inflation of angioplasty catheter, polyethylene catheter is between arterial wall and angioplasty balloon. After angioplasty, internal carotid is thoroughly aspirated with angioplasty catheter, which is then withdrawn. Further aspiration and flushing is performed with guiding catheter, with the objective of aspirating and flushing any particles detached from ulcerated plaque into external carotid.

B, Angioplasty of internal carotid, lateral projection. Nondetachable balloon occludes internal carotid (*white arrow*). Angioplasty catheter (*black arrow*).
C, Similar technique for common carotid stenosis.

clinical signs would have terminated the procedure. The lesion was dilated by repeated inflation of the angioplasty balloon (Fig. 1A). In one case, a 7-French catheter (balloon diameter, 5 mm) was first used to dilate a subocclusion (Fig. 2) before the occlusion balloon could be introduced beyond the lesion.

When the deformation of the balloon caused by the stenosis had disappeared, the carotid artery was thoroughly aspirated with the deflated angioplasty catheter, which was then withdrawn. The guiding catheter was then used to aspirate or flush any particles into the external carotid artery that might have become detached from an

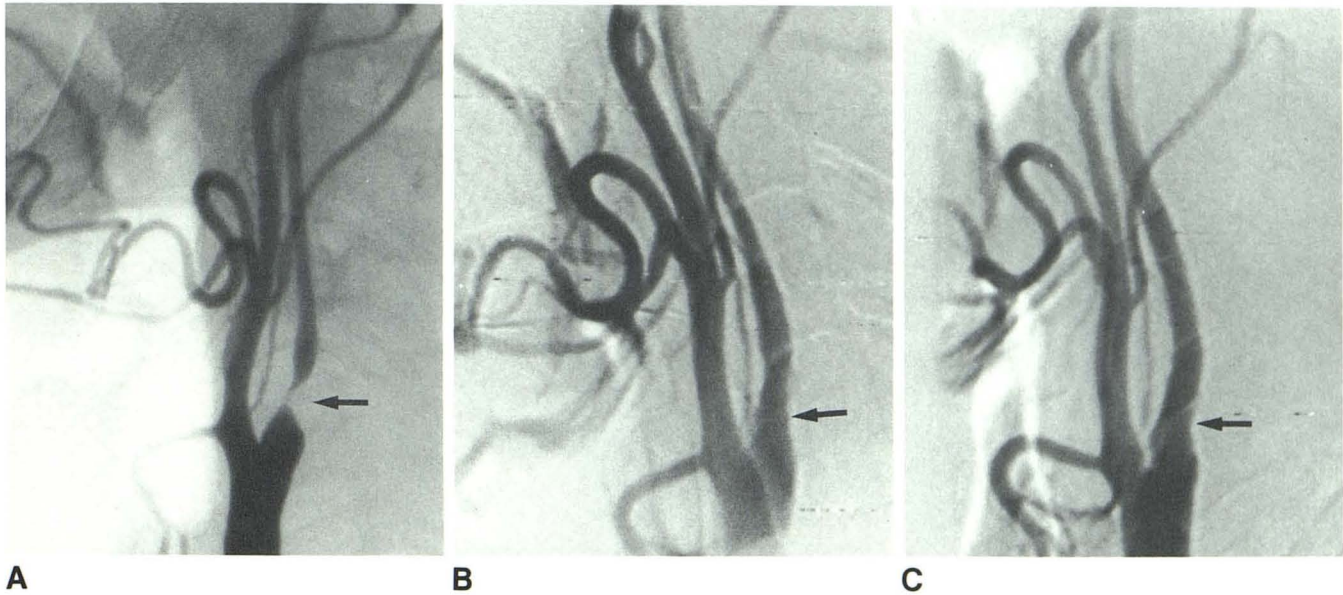


Fig. 2.—Narrow stenosis of right internal carotid (case 3 in Table 1). A 7-French catheter (5-mm balloon diameter) was first used to enlarge artery to enable occlusive balloon to pass stenosis, and an 8-French catheter (8-mm balloon diameter) was then introduced after occlusion of internal carotid.
A, Preangioplasty angiogram. Narrow stenosis (*arrow*).
B, Postangioplasty angiogram. Marked increase of arterial diameter (*arrow*).
C, 2 months later. Remodeling of dilated arterial segment with improvement in diameter (*arrow*).

ulcerated plaque. The occlusive balloon was then deflated and withdrawn. The occlusion time of the carotid usually was no longer than 10 min. Heparin was reversed with protamine at the conclusion of the procedure, and aspirin was administered indefinitely.

The last two patients were prepared by blocking the glossopharyngeal nerve [13] and administering IV atropine to avoid the reflex bradycardia and hypotension observed in two previous patients, which probably resulted from stimulation of the carotid sinus baroreceptors. This method of preparation was successful in both cases.

Angioplasty of five cases of postsurgical stenosis was performed without occlusion of the internal carotid artery by using the femoral approach and the standard direct introduction of an 8-French angioplasty catheter over a guidewire. Heparin was not used in these cases, and patients received 350 mg of aspirin 3 days before treatment and indefinitely thereafter.

Results

The caliber of the stenotic lumen was significantly enlarged in all cases of atherosclerotic stenosis (Figs. 2 and 3). In one patient, the narrowing of the external carotid artery was worse while the morphologic results were excellent at the origin of the internal carotid artery. No obvious macroscopic material was demonstrated in the aspirated blood after angioplasty, and the aspirated blood was not studied microscopically. Part of the potential atherosclerotic particles could have migrated in the external carotid during the flushing. In four postsurgical stenoses, the internal carotid artery was markedly dilated (Fig. 4), but in one case, angioplasty failed, with no significant change in the caliber of the lumen. Follow-up angiograms 2 months after angioplasty in a patient with two stenoses (Figs.

2 and 3) showed patent arteries with remodeling of the surface of the lesions, improving their morphologic aspect.

No complications occurred during or after the procedures. Reflex bradycardia and hypotension were seen on two occasions and were considered side effects affecting the baroreceptors, a phenomenon now controlled by administration of atropine.

The three patients who presented with frequent transient ischemic attacks before angioplasty were all asymptomatic by 14–18 months after the procedure. The patient with frequent loss of consciousness was also asymptomatic at a 6-month follow-up. All asymptomatic patients have remained free of ischemic episodes.

Discussion

Angiographically observed embolization is usually asymptomatic and occurs in 5% of peripheral angioplasties [14]. The atherosclerotic plaque of the carotid bifurcation is frequently ulcerated [11], and the area supplied is less likely to be clinically silent. The fear of cerebral embolization has delayed the application of angioplasty to the carotid bifurcation. Balloon angioplasty of the carotid artery was first reported in 1980 by Kerber et al. [15], who dilated a proximal common carotid artery during distal carotid endarterectomy. There were few other reports [7, 8] until recently, when eight cases were reported by Freitag et al. [9] and 21 cases by Tsai et al. [10]. These publications have established that carotid angioplasty is now a feasible technique. Considering the magnitude of the trials necessary to establish the value

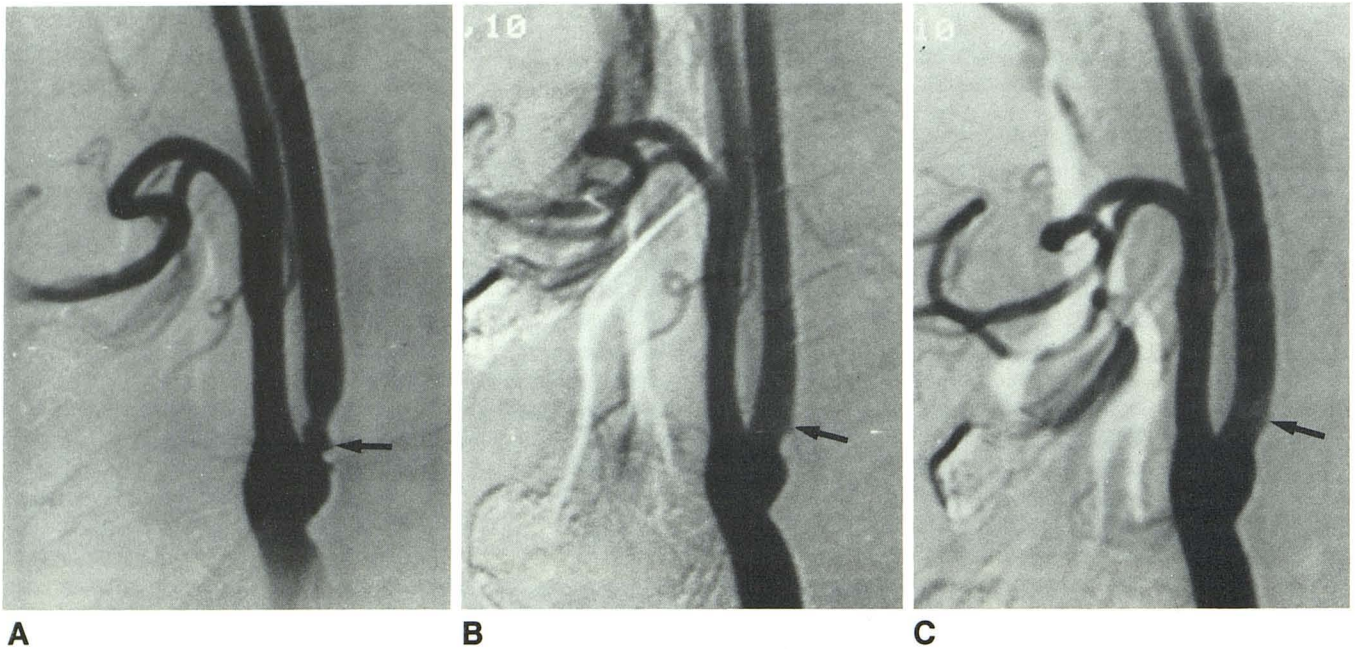


Fig. 3.—Ulcerated stenosis of internal carotid (case 3 in Table 1).

A, Preangioplasty angiogram shows stenosis of internal carotid with obvious ulceration (*arrow*).
B, Postangioplasty angiogram. Improvement in diameter of artery. Ulceration is still slightly visible (*arrow*).
C, 2 months later. Remodeling of dilated segment. Ulceration is barely visible (*arrow*).

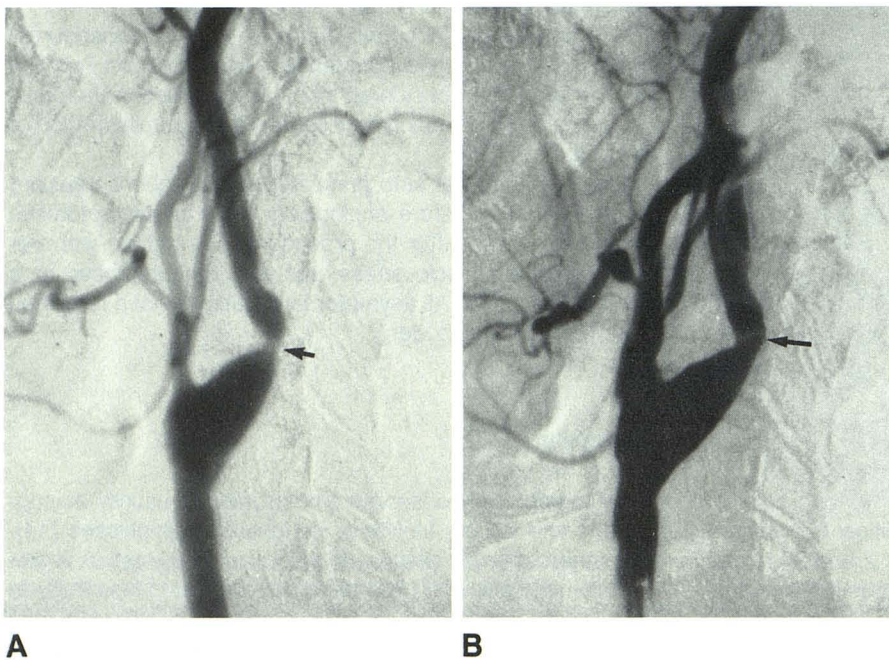


Fig. 4.—Postsurgical stenosis of internal carotid.

A, Preangioplasty angiogram. Narrow stenosis of internal carotid (*arrow*).
B, Postangiography angiogram. Marked improvement in diameter of internal carotid (*arrow*).

of endarterectomy in stroke prevention [16], the definite place of angioplasty in this disease will probably not be determined in the near future. If it were to be a viable alternative to surgery, it would have to be as successful, with a similar or

lower morbidity and mortality than are found with endarterectomy.

The morphologic results after angioplasty are undoubtedly different from those in endarterectomy. The carotid flow may

very well be significantly increased after angioplasty, but that probably plays a minor role in the pathogenesis of cerebral vascular disease. Ulcerations are prominently mentioned as being the usual source of emboli, and the presence of visible ulcerations has been considered a contraindication to carotid angioplasty [8]; however, the accuracy of the angiographic diagnosis of ulcerations is very poor [17]. The increased risks of dilatation of an ulcerated plaque is a theoretical assumption that remains to be proved. Our technique of "cerebral protection" may prevent most emboli from reaching the cerebral circulation. Furthermore, angioplasty may promote healing of the ulceration by modification of the turbulent flow that was caused by the stenosis. Remodeling of the media and intima with reendothelialization known to occur after angioplasty [18, 19] may prove an adequate treatment for ulcerated plaques (Fig. 3). For these reasons we would not restrict angioplasty to smooth lesions.

The reported morbidity and mortality of endarterectomy vary [20–23]. A stroke complication rate greater than 2.9% and a perioperative stroke and/or death rate greater than 10% have been calculated as unacceptable for symptomatic patients [24, 25]. Although the preliminary experience with carotid angioplasty does not permit statistical analysis, we believe that our technique of cerebral protection by temporary occlusion of the internal carotid [26] will help keep the complication rate below the "allowable" morbidity and mortality.

Several authors have described carotid angioplasty in fibromuscular dysplasia [27, 28], a different disease with fewer theoretical risks of cerebral embolization. We have used the same technique for recurrent stenosis after carotid endarterectomy because the early lesions are characterized by intimal fibroplasia [29, 30]. In our opinion, this kind of lesion should be treated as soon as possible when demonstrated on follow-up Doppler, because it may later become untreatable by angioplasty. This is why we have performed angioplasty on these asymptomatic patients. We also believe that, because of the nature of the lesion, it is unnecessary to use an occlusive balloon for this type of stenosis, which is not, when detected early, composed of atherosclerotic plaque.

Further investigation is necessary before angioplasty can play a significant role as a therapeutic tool in the clinical management of cerebrovascular disease. While the exact role of carotid plaques and ulcers in this disease, the effect of angioplasty on the ulcerated plaque, the subsequent risk of embolization, and the potential benefit of remodeling have yet to be elucidated, we believe that a carotid stenosis with an obvious ulcerated plaque poses a considerable risk of embolization to the patient. This is why we performed an angioplasty on the asymptomatic side in a patient who had a symptomatic stenosis on the opposite side (case 3 in Table 1).

At the present time patients may more likely be referred for percutaneous transluminal angioplasty of the carotid artery when the stenosis involves the intrathoracic or intracranial segments, where the surgical approach is difficult and has a higher morbidity [31]. Another indication could be postsurgical stenosis from myointimal proliferation because reoperation is technically difficult [27, 28]. Weblike stenosis (because of the

risk of total occlusion [32]), patients at high surgical risk, and prophylactic correction of carotid stenosis before cardiac surgery are other possible indications.

Carotid angioplasty is feasible. The true risks involved and the potential benefits have to be investigated further. However, it is essential to minimize potential complications by adequate preparation to block baroreceptor reflexes and protect the cerebral circulation by an occlusive balloon. Echotomography [33] or angiography may provide important information in defining the morphology of the plaque before and after angioplasty, in selecting cases, and in evaluating therapy.

REFERENCES

- Dotter CT, Judkins MP. Transluminal treatment of arteriosclerotic obstruction: description of a new technique and a preliminary report of its application. *Circulation* 1964;30:654–670
- Gruntzig A, Hopff H. Perkutane rekanalisation chronischer arterieller Verschlüsse mit einem neuen dilatationskatheter. Modifikation der Dottertechnik. *Dtsch Med Wochenschr* 1974;99:2502–2505
- Motarjeme A, Keifer JW, Zuska AJ. Percutaneous transluminal angioplasty of the brachiocephalic arteries. *AJR* 1982;138:457–462
- Vitek JJ, Raymon BC, Oh SJ. Innominate artery angioplasty. *AJNR* 1984;5:113–114
- Theron J, Courtheoux P, Henriot JP, et al. Angioplasty of supra-aortic arteries. *J Neuroradiol* 1984;11:187–200
- Theron J, Melancon S, Ethier R. Pre-subclavian steal syndromes and their treatment by angioplasty: hemodynamic classification of subclavian artery stenoses. *Neuroradiology* 1985;27:265–270
- Bockenheimer S, Mathias K. Percutaneous transluminal angioplasty in arteriosclerotic internal carotid artery stenosis. *AJNR* 1983;4:791–792
- Wiggli V, Gratzl O. Transluminal angioplasty of stenotic carotid arteries: case reports and protocol. *AJNR* 1983;4:793–795
- Freitag J, Koch RD, Wagemann W. Percutaneous angioplasty of the carotid artery stenoses. *Neuroradiology* 1986;28:126–127
- Tsai FY, Matovich V, Hieshima G, et al. Percutaneous transluminal angioplasty of the carotid artery. *AJNR* 1986;7:349–358
- Imparato AM, Rilez TS, Ecorstein F. The carotid bifurcation plaque: pathologic finding associated with cerebral ischemia. *Stroke* 1979;10:238–245
- Debrun GM, Vinuela FV, Fox AJ. Aspirin and systemic heparinization in diagnostic and interventional neuroradiology. *AJNR* 1982;3:337–343
- Murphy TM. Somatic blockade. In: Cousins MJ, Bridenbaugh PC, eds. *Neural blockade in clinical anesthesia and management of pain*. Philadelphia: Lippincott, 1980:417–418
- Waltman AC, Greenfield AJ, Athanasoulis CA. Transluminal angioplasty: general rules and basic considerations. In: Athanasoulis CA, Pfister RC, Green RE, Roberson GH, eds. *Interventional Radiology*. Philadelphia: Saunders, 1982:253–272
- Kerber CW, Cromwell LD, Leohden OL. Catheter dilatation of proximal stenosis during distal bifurcation endarterectomy. *AJNR* 1980;1(4):348–349
- Taylor DW, Sackett DL, Haynes RB. Sample size for randomized trials in stroke prevention: how many patients do we need. *Stroke* 1984;15(6):968–971
- Eikelboom BC, Riles TR, Mintzer R, et al. Inaccuracy of angiography in the diagnosis of carotid ulceration. *Stroke* 1983;14(6):882–886
- Castaneda-Zuniga WR, Formanek A, Tadavarthy M, et al. The mechanism of balloon angioplasty. *Radiology* 1980;135:565–571
- Zollikofer CL, Salomonowitz E, Sibley R, et al. Transluminal angioplasty evaluated by electron microscopy. *Radiology* 1984;153(2):372–374
- White JS, Sirinek KR, Root HD, Rogers W. Morbidity and mortality of carotid endarterectomy: rates of occurrence in asymptomatic and symptomatic patients. *Arch Surg* 1981;116:409–412
- Dyken ML, Pokras R. The performance of endarterectomy for disease of

- the extracranial arteries of the head. *Stroke* **1984**;15(6):948-955
22. Slavish LG, Nicholas GG, Gee W. Review of a community hospital experience with carotid endarterectomy. *Stroke* **1984**;15(6):956-958
 23. Brott TG, Labutta RG, Kempczinski RS. Changing patterns in the practice of carotid endarterectomy in a large metropolitan area. *JAMA* **1986**;255(19):2609-2612
 24. Chambers BR, Norris JW. The case against surgery for asymptomatic carotid stenosis. *Stroke* **1984**;15(6):964-967
 25. Barnett HJM, Plum F, Walton JN. Carotid endarterectomy—an expression of concern. *Stroke* **1984**;15(6):941-943
 26. Theron J, Cosgrove R, Melanson R, Ethier R. Embolization with temporary balloon occlusion of the internal carotid or vertebral arteries. *Neuroradiology* **1986**;28:246-253
 27. Hasson AN, Zinke DE, Thompson JR. Fibromuscular dysplasia of the internal carotid artery: percutaneous angioplasty. *AJNR* **1981**;2:175-180
 28. Belan A, Vesela M, Vanek I, Weiss K, Peregram JJ. Percutaneous transluminal angioplasty of fibromuscular dysplasia of the internal carotid. *Cardiovasc Intervent Radiol* **1982**;5:79-81
 29. Callow AD. Recurrent stenosis after carotid endarterectomy. *Arch Surg* **1982**;117:1082-1085
 30. Tievsky AL, Druy EM, Mardiat JG. Transluminal angioplasty in post-surgical stenosis of the extracranial carotid artery. *AJNR* **1983**;4:800-802
 31. O'Leary DH, Clouse ME. Percutaneous transluminal angioplasty of the cavernous carotid artery for recurrent ischemia. *AJNR* **1984**;5:644-645
 32. Mullan S, Duda EE, Patro NAS. Some examples of balloon technology in neurosurgery. *J Neurosurg* **1980**;52:321-329
 33. Franceschi CL, Franco G, Luizy F, Tanitte M. *Précis d'échotomographie vasculaire*. Paris: Vigot, **1986**