

Are your **MRI contrast agents** cost-effective?

Learn more about generic **Gadolinium-Based Contrast Agents**.



**FRESENIUS
KABI**

caring for life

AJNR

Bilateral interhemispheric subdural hematoma: a case report.

T G Cronin and D U Shippey

AJNR Am J Neuroradiol 1987, 8 (5) 909-910

<http://www.ajnr.org/content/8/5/909.citation>

This information is current as
of April 18, 2024.

Bilateral Interhemispheric Subdural Hematoma: A Case Report

Thomas G. Cronin,¹ and Dean U. Shippey²

Bilateral interhemispheric subdural hematoma is a rare posttraumatic lesion that has only received mention in the radiologic literature [1], and a mere four cases have been acknowledged in the medical literature [1, 2]. It is usually associated with severe trauma or extenuating circumstances (anticoagulation, ventriculoperitoneal shunt). We report a fifth case of bilateral interhemispheric subdural hematoma.

Case Report

A 68-year-old woman was involved in a motor vehicle accident, striking her chin and forehead. There was a history of a 20 min loss of consciousness. Ten years earlier she had undergone aortic and mitral valve replacements and had been taking Coumadin since. Prothrombin time on admission was 15.4 sec (control of 12.5 sec). The neurologic examination on admission was normal. Twelve hours

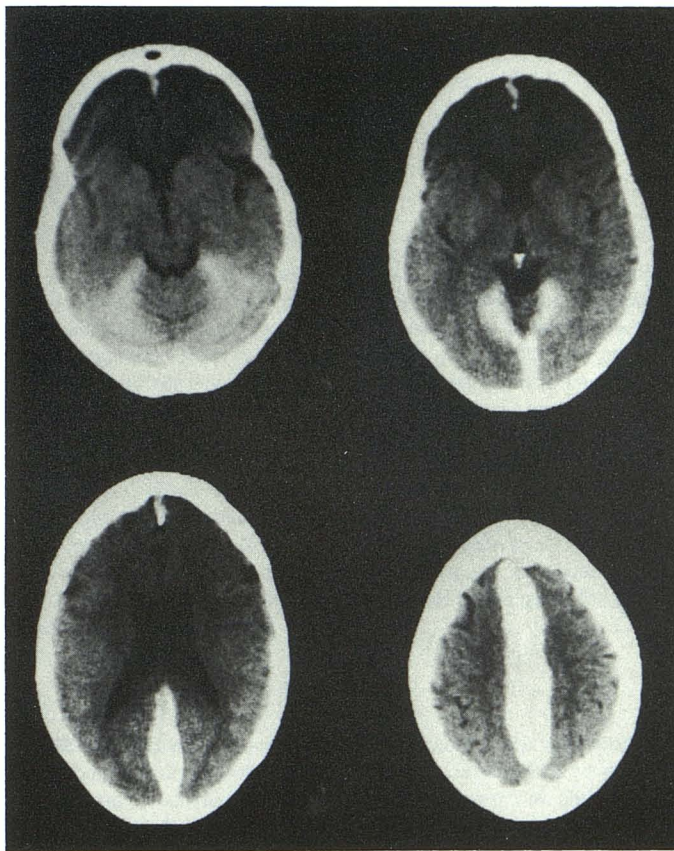


Fig. 1.—CT scans show dense interhemispheric collections of fresh blood extending down over tentorium.

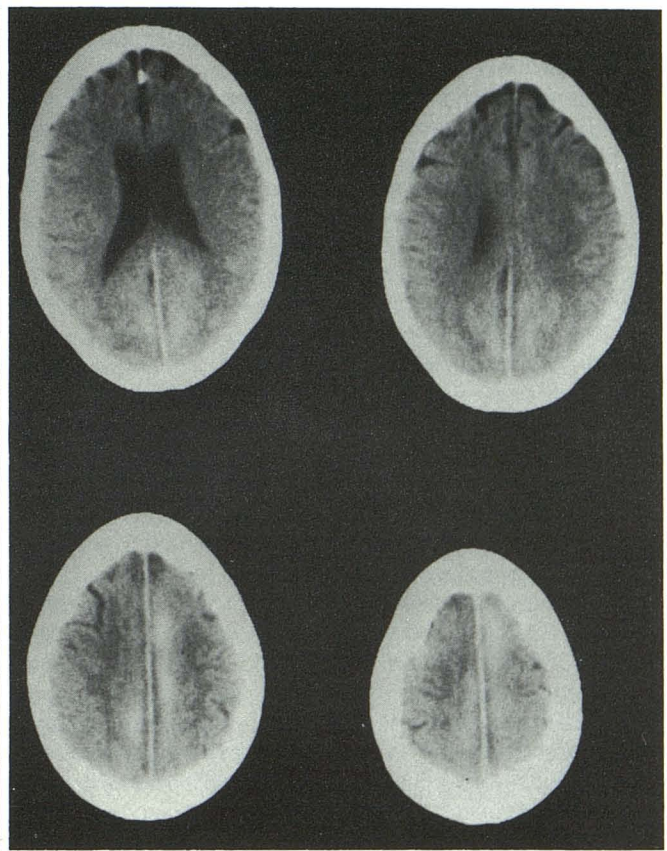


Fig. 2.—CT scans 2 weeks later show so-called "melting" resorption of bilateral interhemispheric subdural hematomas with some blood remaining in central areas.

Received July 24, 1985; accepted after revision November 19, 1985.

¹ Department of Radiology, Saint Francis Hospital, 355 Ridge Ave., Evanston, IL 60202. Address reprint requests to T. G. Cronin.

² 911 East 15th St., Winfield, KS 67156.

later she vomited and became lethargic, and a repeat neurologic exam revealed right leg weakness. CT scan at this time revealed dense and extensive bilateral interhemispheric subdural hematomas (Fig. 1). Ten hours later, the patient developed generalized clonic seizures, which responded to Valium and Dilantin. She was managed conservatively. Repeat CT scan 2 weeks later revealed some resolution of the hematoma (Fig. 2). Follow-up examination at 3-months revealed no residual leg weakness; her only complaint was of mild confusion. CT scan at this time showed complete resolution of the hematoma.

Discussion

Interhemispheric subdural hematomas are unusual post-traumatic intracranial lesions, with bilateral involvement being a rare subset. Zimmerman et al. [1] mentioned three cases in their article on the falx and the interhemispheric fissure, but presented no CT scans or clinical follow-up. Two of their three cases involved penetrating injuries to the cranium. Kasdon et al. [2] reported a case in the neurologic literature that occurred after trauma in a patient with a ventriculoperitoneal shunt for aqueductal stenosis. They surmised that the decreased intraventricular pressure was responsible for the extensive bilateral involvement. Our patient also had an extenuating circum-

stance, anticoagulation, although her prothrombin time on admission was not markedly prolonged.

The etiology of interhemispheric subdural hematoma is probably the traumatic interruption of the relatively fixed bridging veins between the parietal and occipital cortex and the superior sagittal sinus. There is some disagreement in the literature as to whether the interhemispheric subdural space communicates with the convexity subdural space [3]. The prevailing opinion is that it does not, and is prevented from doing so by pacchionian granulations. It is fairly well established that there is no communication between the right and left interhemispheric subdural spaces.

The treatment, whether surgical or conservative, is dictated by the patient's clinical condition. Serial scans will show resolution of the hematoma, demonstrating a melting type of resorption with clearing of the blood peripherally at first.

REFERENCES

1. Zimmerman RD, Russel EJ, Yurberg E, Leeds NE. Falx and interhemispheric fissure on axial CT. *AJNR* 1982;3:635-642
2. Kasdon DL, Magruder MR, Stevens EA, Paullus WS. Bilateral interhemispheric subdural hematomas. *Neurosurgery* 1979;5:57-59
3. Ogsbury JS, Schneck SA, Lehman RA. Aspects of interhemispheric subdural hematoma. *J Neurol Neurosurg Psychiatry* 1978;41:72-75