Are your MRI contrast agents cost-effective?
Learn more about generic Gadolinium-Based Contrast Agents.
FRESENIUS KABI
caring for life

AJNR

Treatment of carotid cavernous fistulae or cavernous aneurysms associated with a persistent trigeminal artery: report of three cases.

G M Debrun, K R Davis, H J Nauta, R E Heros and H S Ahn

AJNR Am J Neuroradiol 1988, 9 (4) 749-755
http://www.ajnr.org/content/9/4/749

This information is current as of April 18, 2024.

Treatment of Carotid Cavernous Fistulae or Cavernous Aneurysms Associated with a Persistent Trigeminal Artery: Report of Three Cases

Gerard M. Debrun[1]
Kenneth R. Davis[2]
Haring J. Nauta[1]
Roberto E. Heros[2]
Hyo S. Ahn[1]

One case of traumatic carotid cavernous fistula and two cases of cavernous aneurysm associated with a persistent trigeminal artery are reported. Since a significant rate of infarctions or hemorrhages in the vertebrobasilar territory is associated with PTA, we prefer to permanently occlude the PTA during treatment of a carotid cavernous fistula or a cavernous aneurysm if the trigeminal artery can be sacrificed without jeopardizing the basilar circulation. These three patients were cured without complications. The internal carotid artery could be preserved in only one case.

The frequency of a trigeminal artery in the normal population is less than 1%; however, there is a significant association with berry aneurysms, brain AVMs, cavernous aneurysms, and carotid cavernous fistulae. There is also a significant risk of transient ischemic attacks, infarctions, and hemorrhages in the distribution of the vertebrobasilar system. We present three cases that illustrate the difficulties in treating a carotid cavernous fistula or a cavernous aneurysm associated with a trigeminal artery.

Case Reports

Case 1

A 30-year-old man developed right proptosis, chemosis, and an audible bruit consistent with a right carotid cavernous fistula (CCF) a few weeks after sustaining a head trauma. Right internal carotid and right vertebral angiograms (Fig. 1) showed the CCF and the trigeminal artery. The basilar artery filled normally from the vertebral injection. The persistent trigeminal artery (PTA) was of the adult type. An 8F introducer was positioned into the right internal carotid artery so that a No. 16 latex balloon could easily enter the cavernous sinus. However, even when fully inflated it could not completely occlude the fistula, despite repeated repositioning. Left vertebral angiography showed that the fistula was still filling through the PTA. After several maneuvers and modification of the distal curve of the balloon catheter, it was possible to enter the trigeminal artery, since the tear of the internal carotid artery (ICA) communicating with the cavernous sinus was exactly at the junction of the PTA with the ICA (Fig. 1D). There was an appropriate inflation of the balloon with iodinated contrast material (Conray 60), which occluded both the PTA and the fistula with preservation of the carotid blood flow. Then the balloon was detached. Full recovery of the ocular symptoms occurred in 1 week and the patient remained asymptomatic thereafter.

Case 2

A 49-year-old woman was referred because of a cavernous sinus syndrome. She was a heavy smoker with high blood pressure (170/107) and she initially developed intermittent left sixth nerve paresis 2 years previously, which progressed to a sixth nerve palsy that became permanent 1 year before admission. She also had retroorbital pain. The left carotid angiogram (Fig. 2) filled the PTA and showed a jet of contrast into the cavernous aneurysm at the same time. The distal branches of the internal carotid artery filled on later films. The vertebral

Received July 28, 1987; accepted after revision December 3, 1987.

Presented at the XIII Symposium Neuroradiologicum, Stockholm, Sweden, June 1986.

[1] Departments of Radiology and Neurosurgery, The Johns Hopkins Medical Institutions, 600 N. Wolfe St., Baltimore, MD 21205. Address reprint requests to G. M. Debrun.

[2] Departments of Radiology and Cerebrovascular Surgery, The Massachusetts General Hospital, Boston, MA 02114.

AJNR 9:749–755, July/August 1988
0195–6108/88/0904–0749
© American Society of Neuroradiology

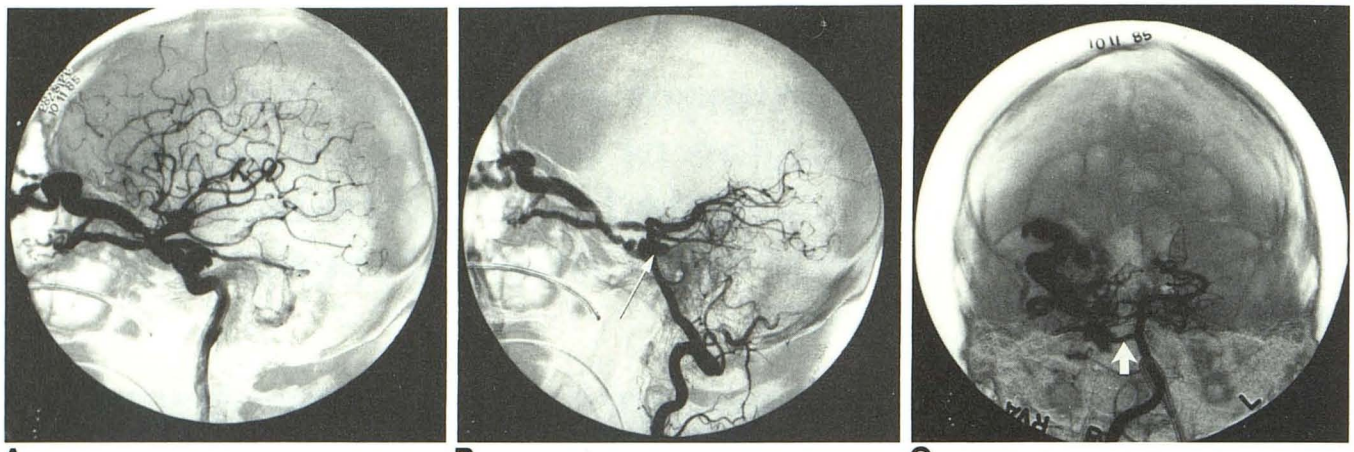

A B C

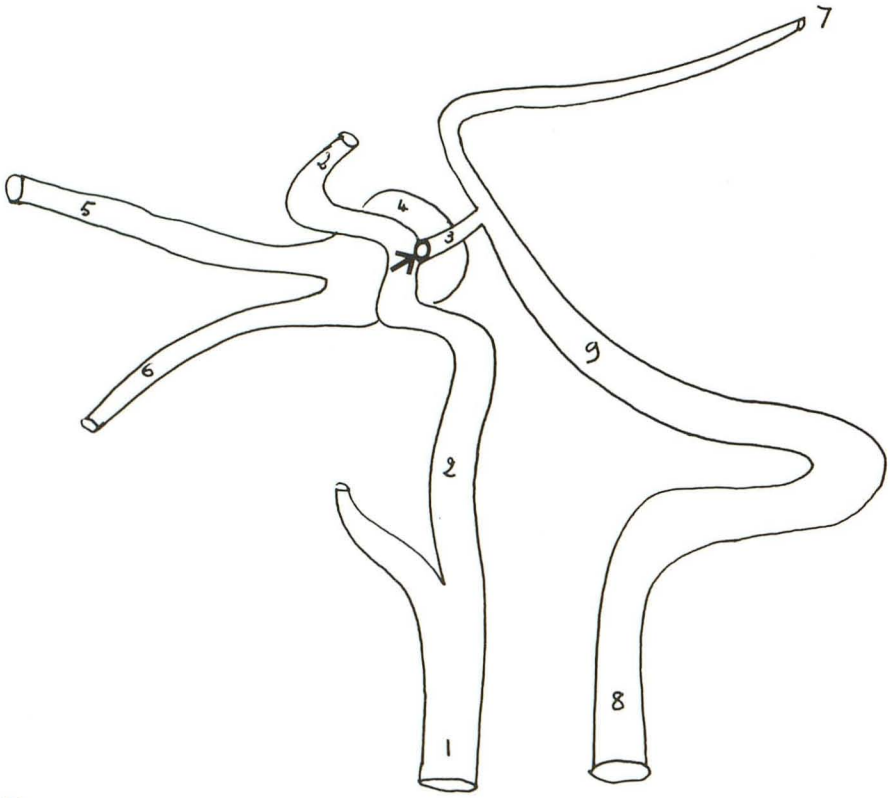

D

Fig. 1.—Case 1.

A, Right internal carotid angiogram of carotid cavernous fistula. Filling of cavernous sinus, superior petrosal sinus, and superior and inferior ophthalmic veins. No filling of persistent trigeminal artery (PTA), inferior petrosal sinus, or pterygoid plexus.

B, Right vertebral angiogram PTA (*arrow*) fills cavernous sinus and veins, as seen on carotid angiogram.

C, Right vertebral angiogram, anteroposterior view. PTA (*arrow*) is well seen above anterior inferior cerebellar artery.

D, Fistula (*arrow*) is at junction of PTA, internal carotid artery, and cavernous sinus. 1 = common carotid artery, 2 = internal carotid artery, 3 = persistent trigeminal artery, 4 = cavernous sinus, 5 = superior ophthalmic vein, 6 = inferior ophthalmic vein, 7 = posterior cerebral artery, 8 = vertebral artery, 9 = basilar artery.

E, Right carotid angiogram after detachment of balloon into PTA. Internal carotid artery is normal. Balloon is seen behind carotid siphon and metallic marker is visible at its tip (*arrow*).

F and *G*, Right vertebral angiogram after occlusion of PTA with one detached balloon. In lateral projection (*F*) basilar artery is normal. Balloon is seen in clear and projects "across" basilar artery (*arrow*). In anteroposterior projection, stump of PTA fills from basilar artery and stops filling when it reaches balloon (*arrow*).

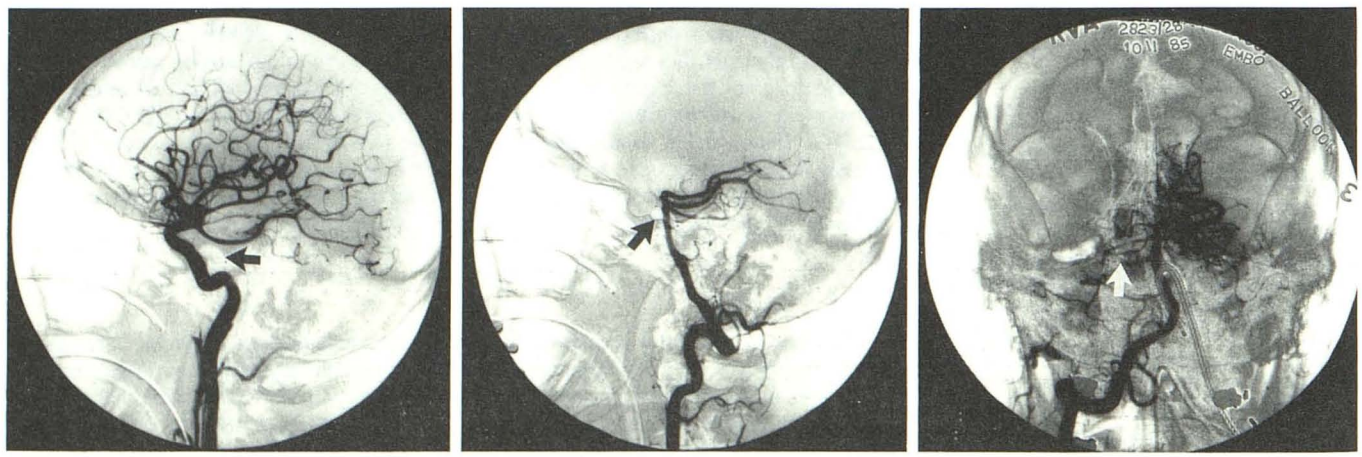

E F G

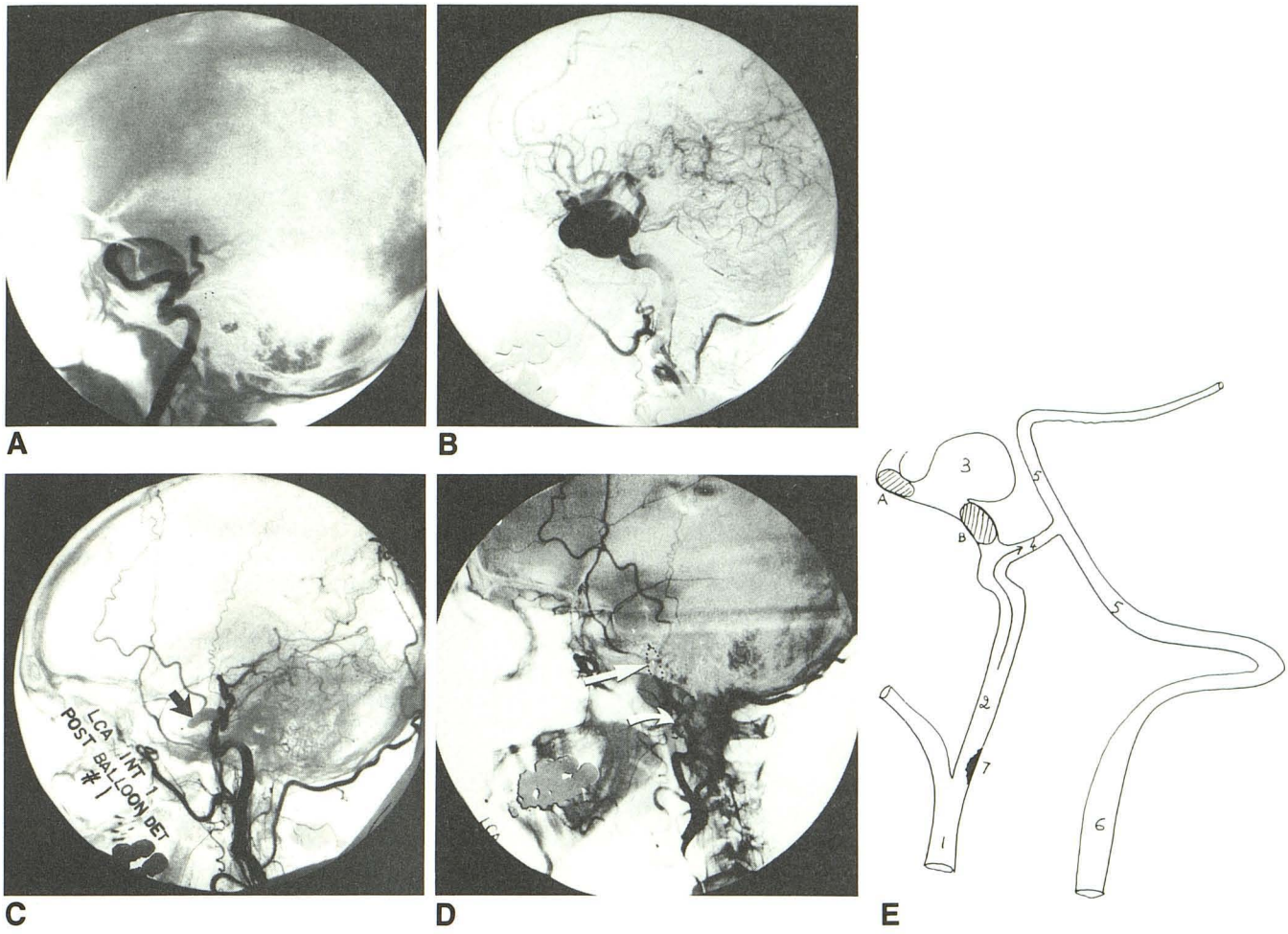

Fig. 2.—Case 2.

***A* and *B*, Left carotid angiogram. Early (A) and late (B) arterial phases show filling of PTA and giant cavernous aneurysm.**

***C* and *D*, Left common carotid angiogram after treatment. Three balloons have been detached. The first (*arrow* in *C*) occludes horizontal portion of carotid siphon. The second (*straight arrow* in *D*) occludes the PTA permanently; and the third (*curved arrow* in *D*) is detached for safety below the PTA.**

***E*, Giant cavernous aneurysm treated with trapping of internal carotid artery. Permanent occlusion of internal carotid artery above PTA. Adult type of PTA with no interruption of basilar artery. If PTA is left patent in such a case, any embolic material migrating into internal carotid artery will reach vertebrobasilar territory through PTA. Therefore, PTA should be occluded permanently. 1 = common carotid artery, 2 = internal carotid artery, 3 = giant cavernous aneurysm with broad neck, 4 = PTA of adult type, 5 = basilar artery, 6 = vertebral artery, 7 = plaque of atheroma at origin of internal carotid artery, A = balloon occluding internal carotid artery above neck of aneurysm, B = balloon occluding internal carotid artery below neck of aneurysm.**

angiogram filled the adult PTA and basilar artery. The first balloon (No. 16 Debrun) was inflated into the horizontal portion of the carotid siphon immediately below the neck of the aneurysm and above the PTA. Subsequent carotid injection opacified the distal basilar artery through the PTA. After 10 min of a well-tolerated test occlusion, the balloon was detached. A second No. 16 balloon was detached below the first, permanently occluding the junction of the internal carotid artery with the PTA. A third balloon was detached in the internal carotid artery at the base of the skull. The contralateral internal carotid angiogram showed ample cross flow. The vertebral angiogram opacified the basilar artery and filled the stump of the PTA without filling the aneurysm or carotid siphon. The patient recovered from her sixth nerve palsy in a few weeks and had a normal neurologic examination 1 year later. There was no filling of the aneurysm on follow-up angiography or on CT.

Case 3

A 67-year-old woman developed a progressive left cavernous syndrome with a complete sixth nerve palsy and a partial third nerve palsy at the time of admission. The left carotid angiogram showed a spherical cavernous aneurysm elongating the carotid siphon. It seemed that most of the neck of the aneurysm was coming off the PTA, which also filled the distal basilar artery (Figs. 3A and 3B). The angiographic work-up included contralateral carotid angiography, which failed to show any cross flow through the anterior communicating artery. The vertebral angiogram filled the basilar artery, but did not fill the PTA. The usual test compression of the ipsilateral internal carotid artery would have been meaningless since the PTA would have remained patent. The only valid occlusion test should have been done with a balloon transiently occluding the ICA above the PTA.

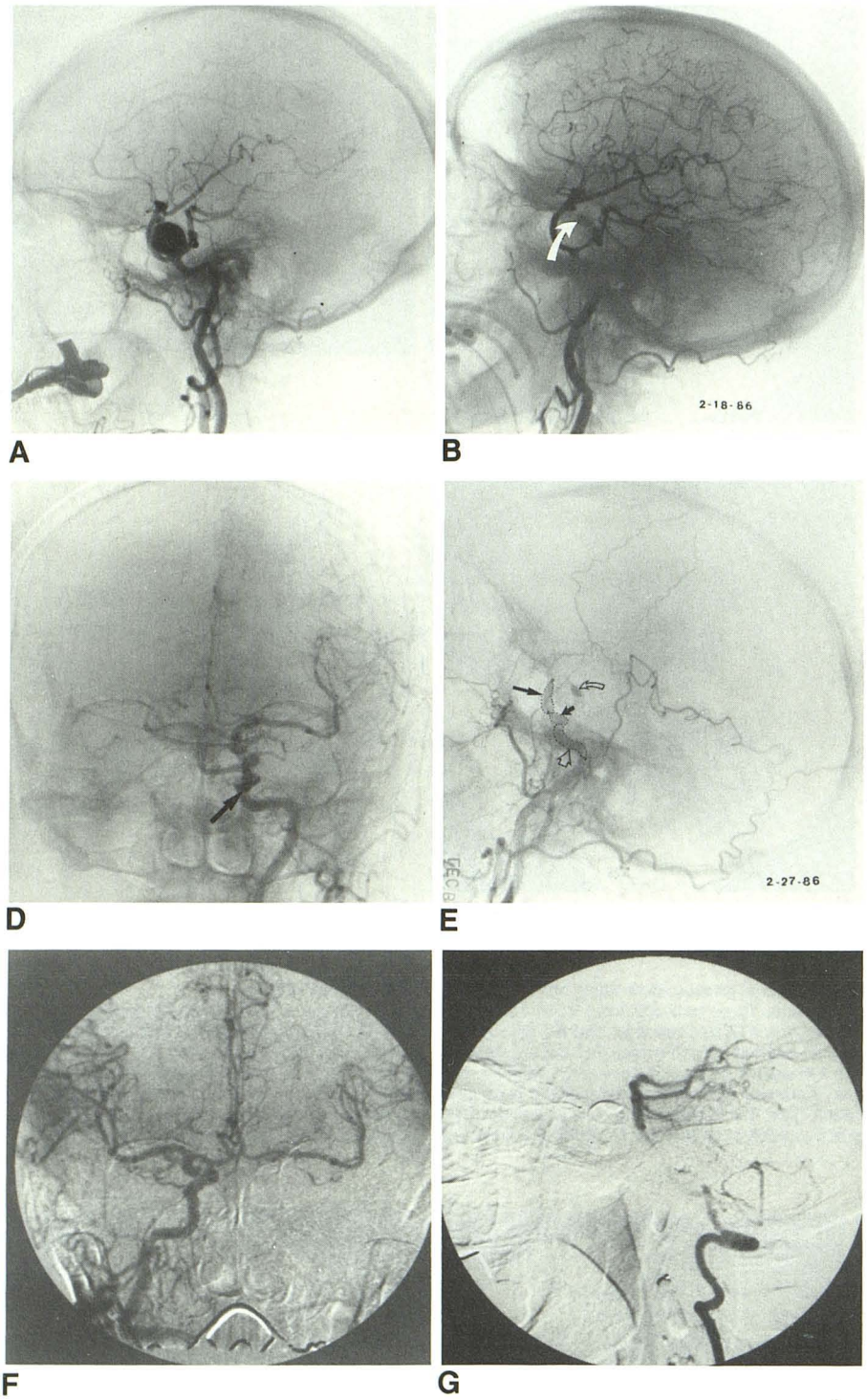

Fig. 3.—Case 3.

A, Left carotid angiogram. Neck of aneurysm comes off PTA at its junction with the internal carotid, which is distorted and elongated by the aneurysm. PTA fills distal basilar artery. Vertebral angiogram (Fig. 3G) shows that it is an adult type of PTA.

B and *C*, Left carotid angiogram after detachment of a latex, silicone-filled balloon into aneurysm. *B*, PTA is still patent but stenosed and internal carotid artery is patent. Silicone-filled balloon is not radiopaque but there is a crescent of iodine within it. *C*, Anteroposterior projection shows almost complete occlusion of sac; however, there is a small amount of contrast around balloon (*arrows*).

D and *E*, Left carotid angiogram 6 days after that in *B* and *C*. Ring of contrast around balloon has gone, but neck of aneurysm is larger (*arrow* in *D*). *E*, Internal carotid artery is occluded above PTA (*long black arrow*) at level of PTA that is occluded (*short black arrow*) and below PTA (*straight open arrow*). Crescent of iodine inside balloon is still present (*curved open arrow*). Minimal filling of one middle cerebral artery collateral through by-pass is seen.

F, Right carotid angiogram, anteroposterior projection, shows good cross flow after permanent occlusion of left internal carotid artery above PTA, proving that the external carotid to internal carotid by-pass done before treatment was not mandatory.

G, Vertebral angiogram after permanent occlusion of internal carotid artery and of PTA. Normal filling of basilar artery (adult type of PTA). No filling of PTA.

The neurosurgeon elected to make an external carotid to internal carotid (ECIC) by-pass. The next day, the patient underwent occlusion of her cavernous aneurysm with a detachable balloon (Figs. 3B and 3C). The balloon was partially filled with silicone and partially with iodine contrast material (Conray 60). The internal carotid artery and PTA remained patent. The PTA was narrowed, but the internal carotid blood flow was preserved with minimal filling of the aneurysmal pouch on the anteroposterior view. The patient tolerated the procedure well. However, on follow-up left carotid angiography 6 days later the neck of the aneurysm showed increased filling, indicating a failure to occlude the neck of the aneurysmal pouch with the limited balloon inflation that was required to preserve the internal carotid and PTA blood flow. There was also the risk of clot emboli into the internal carotid artery and the PTA from the nonepithelialized neck. Therefore, 3 days later, we permanently occluded the left internal carotid artery above the aneurysm after 10 min of a well-tolerated test occlusion.

A second balloon was then positioned to block the communication between the internal carotid artery and the PTA. A third balloon was detached for added security in the intrapetrous portion of the internal carotid artery. These three balloons were inflated with iodinated contrast material (Conray 60). The patient underwent an uneventful recovery and had a normal neurologic examination 3 months after treatment.

Discussion

It is commonly accepted that the persistence of carotid-basilar anastomosis is a rare coincidental finding during angiography or autopsy with little or no clinical significance. However, a review of the literature shows a high frequency of vascular malformations and complications associated with a persistent carotid-basilar anastomosis. An aneurysm arising from the PTA or at its junction with the internal carotid artery has been described in a number of cases [1–5]. Such aneurysms were associated with a CCF in two reported cases [1, 3]. The PTA was associated with aneurysms of the circle of Willis or other vascular malformations in up to 25% of the cases [6–13].

The vascular malformations associated with the PTA included Moya-Moya disease [14], aortic arch malformations [10], anomalies of origin of the cerebellar arteries [15], agenesis or occlusion of the internal carotid artery [8], aneurysms [6, 7, 9, 11–13, 16–18], and AVMs [11]. More importantly, the PTA was associated with a high frequency of transient ischemic attacks, infarctions, and hemorrhages in the vertebrobasilar territory [19, 20]. More precisely, internuclear ophthalmoplegia [19], bilateral cortical blindness [21, 22], recurrent pontine hemorrhages [23], vertebrobasilar insufficiency [18], recurrent infarctions of the brainstem [24, 25], and recurrent transient ischemic attacks [26, 20] were found to be associated with PTA.

The PTA was associated with a CCF in several published articles [1, 3, 27–29]. The fistula was always at the junction of the internal carotid artery and the PTA. In none of them, except the case reported by Kerber and Manke [29], could the internal carotid blood flow be preserved. We think that our case 1 is the first published report of CCF associated with a PTA in which the balloon could be detached in the PTA itself with preservation of the internal carotid and vertebrobasilar blood flow. It is expected that future similar cases will be successfully treated as a result of knowing that the PTA can and should be considered the best way to reach the fistula and preserve the internal carotid blood flow. Failure of endoarterial catheterization is probably an indication that an attempt should be made to surgically expose the PTA for intraoperative embolization under angiographic control. The presence of the PTA or of a hypoglossal artery [28] has been the reason why a fistula has persisted after a trapping procedure.

The treatment of a cavernous aneurysm associated with a PTA does not modify the treatment of the aneurysm itself. It seems that the easiest and safest way to permanently occlude the internal carotid artery is by using detachable balloons. The ideal would be to detach one balloon above and below the neck of the aneurysm. But it is not always possible to advance a balloon beyond the aneurysm because of tortuosities of the vessels. In this case it is perfectly sufficient to detach the first balloon immediately below the neck of the aneurysm.

There are several reasons for not detaching the balloon in the aneurysm itself, even though this precludes the advantage of preserving the carotid blood flow. First, these aneurysms are often giant with a broad neck, and the balloon inflated inside the pouch of the aneurysm bulges through the neck to stenose the internal carotid artery. Second, the aneurysm induces mass effect with compression of the adjacent cranial nerves (III, V, and VI). It is not logical to increase the risks of mass effect by inflating a balloon inside the aneurysm. Third, navigation inside an aneurysm partially thrombosed with mural clots can be dangerous, with a risk of distal emboli. When the neck of the aneurysm is relatively narrow or when the aneurysm seems to originate completely from the PTA (as in our case 3), however, it seems ideal to try to occlude the aneurysm with a balloon detached inside the pouch and to try to preserve the arterial blood flow. It has often been said that an aneurysm will completely thrombose if 90% of its volume is occluded. Our experience does not corroborate this statement. In case 3, while 99% of the aneurysm was originally occluded it increased in size 6 days after the balloon was inserted. Although we could have waited longer to see if it continued to grow, we preferred not to take the risk since the PTA was stenosed by the balloon and the aneurysm was incompletely occluded.

The presence of a PTA has a number of implications for the management of associated aneurysms. Test occlusion with the balloon inflated 10 min in the internal carotid artery before detachment is of value only if the balloon is inflated beyond the PTA. All other tests that are usually done to determine if an ECIC by-pass is necessary before occlusion of the carotid artery are of no value because of the existence of the PTA. Our case 3 illustrates this point. An ECIC by-pass was done in this case before occlusion of the internal carotid artery because the angiographic work-up had shown poor collateral circulation, which was expected to be inadequate. However, contralateral internal carotid angiography and the vertebral angiography showed a good collateral circulation after occlusion of the internal carotid artery *above* the PTA. The test occlusion during the diagnostic work-up had been done with compression of the carotid artery *below* the PTA. In fact, this test, although negative, did not prove that the carotid artery could be occluded above the PTA. In this case, the PTA ECIC by-pass could have been avoided. The high frequency of emboli, infarctions, and hemorrhages in the vertebrobasilar territory reported in the literature in association with a PTA has not yet been considered an indication to permanently occlude the PTA. However, when it is present in situations as described in this report, it can serve as a warning to occlude the PTA at the time of treatment of the associated CCF or cavernous aneurysm with detachable balloons. Particularly during the treatment of a cavernous aneurysm, which usually ends with permanent occlusion of the ICA, it seems useless and risky to maintain the patency of an adult type of

PTA. In the adult PTA, the basilar artery totally fills from one or both vertebral arteries, and therefore the PTA is not a mandatory collateral channel. In these cases, embolic material from the internal carotid artery will reach the basilar territory through the PTA (Fig. 2E) since the internal carotid has been occluded above it. The embryological anatomic studies [1, 15, 30–32] have emphasized the difference between the fetal and adult type of PTA. The persistence of a fetal type of PTA (Fig. 4) means that the PTA is a major vessel between the internal carotid and the basilar artery and therefore an important supply to the cerebellum and the brainstem and possibly the only vascular supply to the distal basilar artery and its branches if the posterior communicating arteries are not widely patent. The vertebral arteries fill only the lower part of the basilar artery in the fetal type. Therefore, the fetal type of PTA should not be occluded during the treatment. It is interesting that the three cases we are reporting here are all of the adult type. The basilar artery was normally filled by the two vertebral arteries, which is why the PTA could be and had to be occluded in our opinion.

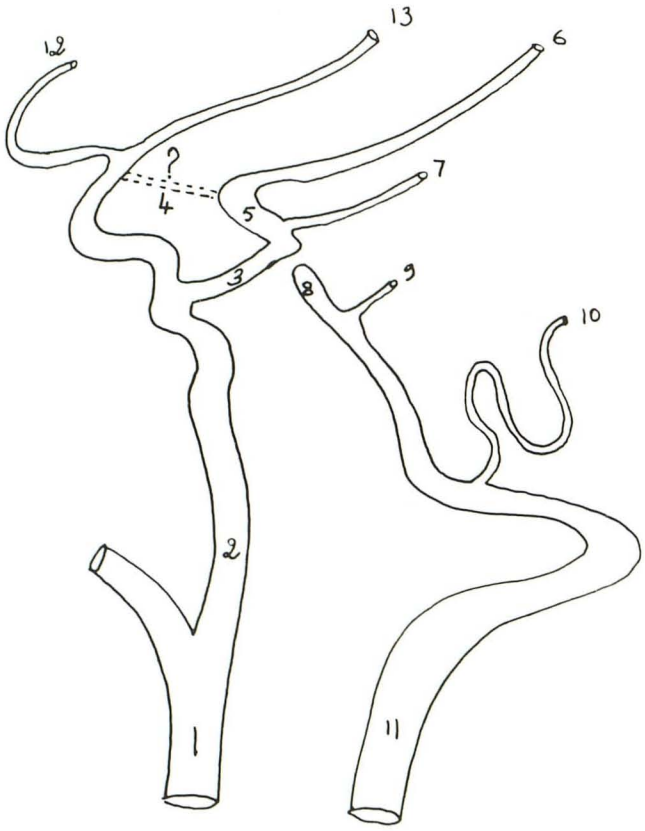

Fig. 4.—Fetal type of PTA with discontinuity of basilar artery. PTA is only blood supply to upper basilar artery, superior cerebellar arteries, and posterior cerebral arteries. This type of PTA cannot and should not be permanently occluded unless posterior communicating arteries are widely patent. 1 = common carotid artery, 2 = internal carotid artery, 3 = persistent trigeminal artery, 4 = posterior communicating artery (Is it patent or not?), 5 = distal basilar artery, 6 = posterior cerebral artery, 7 = superior cerebellar artery, 8 = lower basilar artery, 9 = anterior interior cerebellar artery, 10 = posterior inferior cerebral artery, 11 = vertebral artery, 12 = anterior cerebral artery, 13 = middle cerebral artery.

In conclusion, the rarity of a PTA explains the small number of cases reported in the literature. The high frequency of ischemic, embolic, or hemorrhagic complications in the vertebrobasilar territory associated with a PTA seems to indicate that the PTA should be occluded during the treatment of an associated cavernous aneurysm or CCF. The only contraindication is if the PTA is a functional and vital vessel of the fetal type. In the future, during the treatment of traumatic CCFs associated with a PTA, all efforts should be made to occlude the adult PTA with a detachable balloon introduced through endoarterial catheterization or at surgery.

REFERENCES

1. Charlin JF, Clavier E, Thiebot J, Brasseur G, Langlois J. Cavernous fistula caused by rupture of an aneurysm of the trigeminal artery. Case report. *Rev Otoneuroophthalmol* **1982**;54:249–254
2. Eggers FM, Tomsick TA, Chambers AA, Lukin RR. Aneurysms of persistent trigeminal arteries. Report of two cases. *Neuroradiology* **1982**;24:55–65
3. Enomoto T, Sato A, Maki Y. Carotid-cavernous sinus fistula caused by rupture of a primitive trigeminal artery aneurysm. Case report. *J Neurosurg* **1977**;46:373–376
4. Morrison G, Hegarty WM, Brauch CC, Castele TJ, White RJ. Bis. Direct surgical obliteration of a persistent trigeminal artery aneurysm. Case report. *J Neurosurg* **1974**;40:249–251
5. Tanaka Y, Hara H, Momose G, Kobayashi S, Sugita K. Proatlantal intersegmental artery and trigeminal artery associated with an aneurysm. Case report. *J Neurosurg* **1983**;59:520–523
6. Garza-Mercado R, Cavazos E. Persistent trigeminal artery associated with intracranial arterial aneurysm. *Neurosurgery* **1984**;14:604–607
7. Kosink EJ, Meagher JN, Taylor G. Bilateral intracranial arterial aneurysms with a persistent trigeminal artery. *Arch Neurol* **1977**;34:443–445
8. Lewis VL, Cail WS. Persistent trigeminal artery with internal carotid artery occlusion. *Neurosurgery* **1983**;13:314–315
9. Matsumura M, Wada H, Nojiri K. Persistent primitive trigeminal artery, cavum septi pellucidi, associated cerebral aneurysm in a patient with polycystic kidney disease. Case report. *Neurosurgery* **1985**;16:395–397
10. Moore TS, Morris JL. Aortic arch vessel anomalies associated with persistent trigeminal artery. *AJR* **1979**;133:309–311
11. Nakajima K, Ito Z, Hen R, Uemura K, Matsuoka S. Congenital anomalies of cerebral artery and intracranial aneurysm. *Brain Nerv* **1976**;28:481–496
12. Tomsick TA, Lukin RR, Chambers AA. Persistent trigeminal artery. Unusual associated abnormalities. *Neuroradiology* **1979**;5:253–257
13. Uda T, Goya T, Kinoshita K, Wakuta Y, Mihara K. Multiple anomalies of cerebral vessels. A case of multiple aneurysms associated with fenestration of the middle cerebral artery and persistent primitive trigeminal artery. *No Shinkei Geka* **1984**;12:531–536
14. Kwak R, Kadoya S. Moya-Moya disease associated with persistent primitive trigeminal artery. Report of two cases. *J Neurosurg* **1983**;59:166–171
15. Cobb SR, Hieshima GB, Mehringer CM, Grinnell VS, Pribram HW. Persistent trigeminal artery variant. Carotid-anterior inferior cerebellar artery anastomosis. *Surg Neurol* **1983**;19:263–266
16. Gelmers JH. On the clinical significance of a persistent trigeminal artery in patients with stroke. *Neurochirurgia (Stuttg)* **1981**;24:103–105
17. Moretti G, Manzoni GC, Terzano MG, Formentini E, Lechi A, Cusmano F. Persistent trigeminal artery and its association with ischemic cerebrovascular disease. Further observations. *Acta Neurol (Napoli)* **1981**;36:564–571
18. Palmer S, Gucer G. Vertebrobasilar insufficiency from carotid disease associated with a trigeminal artery. *Neurosurgery* **1981**;8:458–461
19. Cahill DW, Salcman M, Hirsch D, Rao CV. Unilateral internuclear ophthalmoplegia due to angiographic embolism through a primitive trigeminal artery. *Neurology* **1981**;31:751–753

20. Waller FT, Simons RL, Kerber C, Kiesel IO, Tanabe CT. Trigeminal artery and microemboli to the brain stem. Report of two cases. *J Neurosurg* **1977**;46:104–106
21. Heeney DJ, Koo AH. Bilateral cortical blindness associated with carotid stenosis in a patient with a persistent trigeminal artery. Case report. *J Neurosurg* **1980**;52:709–711
22. Quencer RM, Simon J. Transient bilateral occipital lobe ischemia: microembolization through a trigeminal artery. *Neuroradiology* **1979**;12:273–275
23. Miyahara S, Ohta H, Takaki T, Yonemasu Y, Yokota K. Recurrent routine hemorrhage associated with persistent primitive trigeminal artery and facial angioma (author's trans.). *No To Shinkei* **1977**;29:695–689
24. Rousseaux M, Combelle G, Krivosic Y, Petit H, Christiaens JL. Multifocal infarction of the basilar trunk region. Persistence of a trigeminal artery. *Rev Neurol (Paris)* **1985**;141:49–52
25. Salmonez JL, Nedelec C, Clarisse J, Petit H. Medullopontine infarction. Occlusion of the basilar trunk with trigeminal artery. *Rev Otoneurooph-thalmol* **1982**;54:223–229
26. Stern J, Correll JW, Bryan N. Persistent hypoglossal artery and persistent trigeminal artery persisting with posterior fossa transient ischemic attacks. Report of two cases. *J Neurosurg* **1978**;49:614–619
27. Berger MS, Hosobuchi Y. Cavernous sinus fistula caused by intracavernous rupture of a persistent primitive trigeminal artery. Case report. *J Neurosurg* **1983**;58:611–613
28. Debrun GM, Lacour P, Vinuela F, Fox A, Drake CG, Caron JP. Treatment of 54 traumatic carotid cavernous fistulas. *J Neurosurg* **1981**;55:678–692
29. Kerber W, Manke W. Trigeminal artery to cavernous sinus fistula treated by balloon occlusion. Case report. *J Neurosurg* **1983**;58:611–613
30. Binet EF, Young RF. Bilateral persistent trigeminal arteries. Case report. *J Neurosurg* **1977**;47:619–622
31. Khodadad G. Persistent trigeminal artery in the fetus. *Radiology* **1976**;12:653–656
32. Lasjaunias P, Moret J, Doyon D, Vignaud J. C5 collaterals of the internal carotid siphon: embryology, angiographic anatomical correlations, pathological radio-anatomy [author's translation]. *Neuroradiology* **1978**;16:304–305