

Are your **MRI contrast agents** cost-effective?

Learn more about generic **Gadolinium-Based Contrast Agents**.



FRESENIUS  
KABI

caring for life

**AJNR**

**Lymphocytic adenohypophysitis: autoimmune disorder of the pituitary gland.**

R M Quencer

*AJNR Am J Neuroradiol* 1980, 1 (4) 343-345

<http://www.ajnr.org/content/1/4/343.citation>

This information is current as  
of April 20, 2024.

# Lymphocytic Adenohypophysitis: Autoimmune Disorder of the Pituitary Gland

ROBERT M. QUENCER<sup>1</sup>

Autoimmune lymphocytic infiltration of the pituitary gland is rare. In the five previously reported cases [1–5], there was clinical evidence of hypopituitarism but the diagnosis of lymphocytic adenohypophysitis was made only by postmortem examination of the pituitary gland. I describe a case of lymphocytic adenohypophysitis in a young, multiparous woman who had clinical features of a prolactinoma, otherwise normal pituitary function, and radiologic findings compatible with a pituitary adenoma. The diagnosis was established on examination of tissue removed at transsphenoidal hypophysectomy. This is the first description of the radiographic features of this disorder.

## Case Report

A 25-year-old woman, gravida 5, para 5, was seen at 5 months postpartum with headaches, a 9 kg weight gain, amenorrhea, and galactorrhea. Her neurologic examination was normal. FSH, LH, T4, T3, TSH, and cortisol levels were normal; however, serum prolactin was 60 ng/ml (normal, 5–25) and her serum gamma globulins were elevated. Skull films and tomography showed an enlarged sella with erosion of the dorsum. Computed tomography (CT) (General Electric CT/T 7800 scanner) in the axial and coronal planes (fig. 1) showed an enhancing intrasellar mass with no suprasellar or parasellar extension. Because a pituitary adenoma was considered most likely, a transsphenoidal hypophysectomy was performed.

At surgery, a firm, purplish pituitary gland was encountered and a subtotal anterior pituitary resection was performed. Pathologic examination (fig. 2) showed a lymphocytic infiltration of the adenohypophysis characterized by lymphoid follicles, wide bands of fibrosis, and well differentiated lymphocytes. Parts of the surgical specimen containing fragments of the neurohypophysis showed that it was not involved. There was no evidence of giant cell infiltration or granulomatous involvement. These findings were interpreted as a chronic inflammation characteristic of an autoimmune response and a diagnosis of a lymphocytic adenohypophysitis was made.

Postoperatively the patient did well; her galactorrhea and headaches disappeared and her serum gamma globulin and prolactin levels returned to normal. Serum titers for antibodies to prolactin-secreting pituitary cells were not obtained either before or after the surgery. No antiinflammatory drugs were given. All other hormonal levels remained normal and, as a result, no replacement therapy was necessary.

## Discussion

Increased secretion of prolactin from the pituitary may result from a number of pathologic and physiologic conditions [6–8]. When neoplastic processes are considered, prolactin-secreting adenomas are the most common hypersecreting tumors of the pituitary [7–9]. This case represents the first report of an inflammatory process in the pituitary that resulted in increased serum prolactin levels.

Although the presence of lymphocytes within the pituitary gland was considered abnormal by original investigators [10], Shanklin [11] analyzed 100 pituitary glands and found that in nearly one-half, lymphocytes were normally found. These lymphocytes were most abundant in the pars intermedia with fewer in the pars nervosa, capsule, and stalk. The observation that lymphocytes are not normally found in the pars anterior allows a clear distinction between normal and a pathologic accumulation of lymphocytes within the hypophysis.

In 1962, Goudie and Pinkerton [1] described a lymphocytic infiltration of the pars anterior and of the pituitary of the thyroid in a young woman who died of gangrene of the appendix 6 months postpartum. They were the first to suggest that an autoimmune disorder could account for the pathologic process that occurred in both the pituitary and thyroid glands.

Since that report, four other cases have been reported [2–5], and in each a diagnosis of a lymphocytic hypophysitis was established, but only at autopsy. In none was there any mention of radiographic abnormalities. All of these patients were female and each had clinical evidence of hypopituitarism (table 1). In three cases, there was lymphocytic involvement of organs, as well as the pituitary (thyroid [1]; thyroid and gastric mucosa [2]; adrenal and parathyroids [4]), while in two [3, 5], only the pituitary was involved. Histologic characteristics similar to our case were seen in the five cases; interestingly, in none was the neurohypophysis involved in the inflammatory process. All authors agreed with the original observation of Goudie and Pinkerton [1] that these features were diagnostic of an autoimmune disorder. Using immunofluorescent staining techniques, Bottazzo et al. [12] discovered serum antibodies to prolactin cells of the anterior pituitary in a small percentage of patients with

Received September 28, 1979; accepted after revision December 19, 1979.

<sup>1</sup> Department of Radiology (R-130), University of Miami School of Medicine, P.O. Box 016960, Miami, FL 33101.

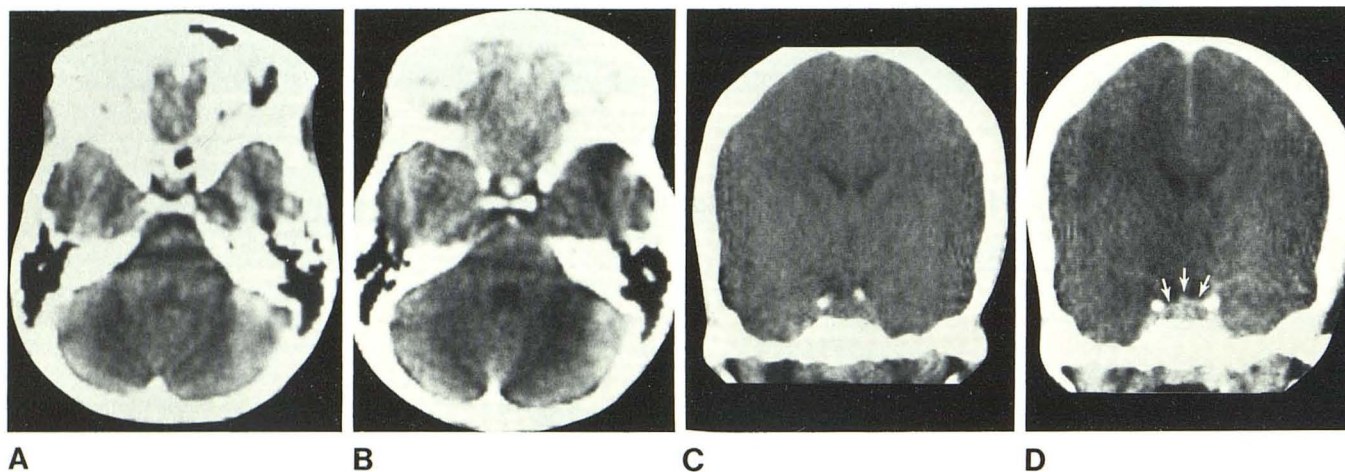


Fig. 1.—Axial (A and B) and coronal (C and D) sections before (A and C) and after (B and D) injection of 100 ml of Renografin-76. Marked enhancement within sella. Upward convexity of enhancing mass (D, arrows) was previously described in prolactinomas (see text).

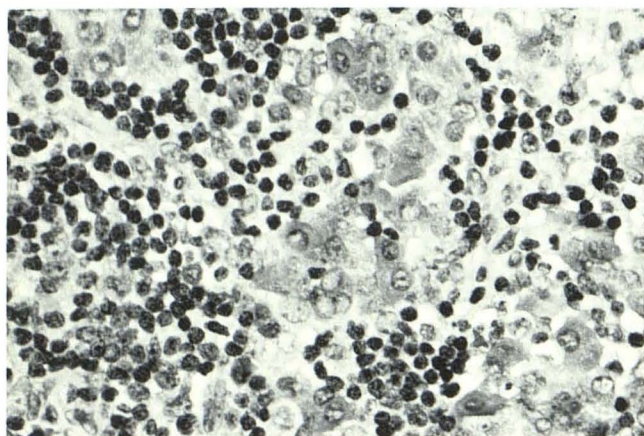


Fig. 2.—H and E medium power paraffin section. Extensive destruction of adenohypophyseal tissue by lymphocytic infiltration.

autoimmune endocrine diseases. On the basis of these findings, they suggested that an autoimmune process may cause a prolactin deficiency. The discrepancy between the postulated prolactin deficiency and our patient is discussed below. The clinical and pathologic findings of the known causes of lymphocytic adenohypophysitis are summarized in table 1.

An explanation for this type of pituitary disorder in female patients is found in a study by Engelberth and Jezkova [13]. They measured the levels of circulating pituitary antibodies in 128 patients 5–7 days postpartum and found that serum levels were elevated in 23. Four of these patients had clinical signs of decreased anterior hypophyseal function 6–12 months later. These findings indicate that a significant number (3%) of postpartum women could develop clinical hypopituitarism on the basis of an autoimmune disorder. This mechanism may account for the hypopituitarism in two cases [1, 3].

Contrary to those two cases and the three whose hypopituitarism was unrelated to pregnancy [2, 4, 5], our patient

did not have decreased pituitary function. Instead, she had elevated serum prolactin levels with secondary galactorrhea and amenorrhea. There are three possible explanations for this endocrinologic difference: (1) the autoimmune process caused the prolactin-secreting cells to become hypersecretory, (2) the autoimmune process caused those cells to be less responsive to the prolactin inhibitory factor, or (3) the inflamed and swollen anterior pituitary gland compressed the infundibulum, decreasing the release of the prolactin inhibitory factor. In any event, further inflammatory changes would probably have destroyed more of the adenohypophysis, which would have eventually resulted in a state of decreased pituitary function.

If a patient has decreased pituitary function, a focally eroded or large sella, and an enhancing intrasellar mass, it may be clinically and radiologically impossible to distinguish lymphocytic hypophysitis from chromophobe adenoma. When similar radiographic findings are associated with galactorrhea, amenorrhea, and high serum prolactin levels, differentiation between hypophysitis and prolactinoma may likewise be difficult. An enhancing intrasellar mass [14, 15], which has an upward convexity on coronal scanning [15], is one of the CT findings that has been described in prolactinomas, and resembles that seen in figure 1. If, as in our case, a normal delivery recently occurred, an autoimmune hypophysitis should be considered a diagnostic possibility. Under these circumstances, levels of serum antibodies to prolactin secreting cells [12] should be obtained. Although these antibodies may also be found in other patients with a variety of autoimmune endocrine disorders, including hypoparathyroidism, Addison disease, hypogonadism, diabetes mellitus, thyroid disease, and pernicious anemia [12], the clinical presentation of the patient should help distinguish these diseases from one primarily involving the prolactin-secreting cells of the pituitary. A combination of these radiologic, chemical, and clinical features will make the diagnosis of an autoimmune hypophysitis most likely, possibly averting surgery for what might otherwise have been considered a prolactinoma.

TABLE 1: Reported Cases of Lymphocytic Adenohypophysitis

Reference No.	Patient's Age (yrs)	Clinical Summary	Autopsy Findings		Other Autoimmune Changes
			Cause of Death	Pituitary (Adenohypophysis)	
[1]	22	6 months postpartum: developed amenorrhea, fatigue, enlarged thyroid	Gangrene of appendix	Atrophic; lymphocytic infiltration and a few plasma cells	Hashimoto thyroiditis
[2]	74	Nulliparous; 24 years postmenopausal; long history of fatigue and pallor; signs of hypothyroid and pernicious anemia	Thyroid and adrenal insufficiency	Atrophic; lymphocytic infiltration and fibrosis	Hashimoto thyroiditis; chronic atrophic lymphocytic gastritis
[3]	29	1 year amenorrhea post normal pregnancy; hypoglycemia, fatigue	Hypoglycemic shock	Enlarged; lymphocytic inflammation (chronic)	...
[4]	42	Anemia, weight loss, hypothyroidism, two spontaneous abortions 20 years earlier	Septicemia	Normal size; lymphocytic and plasma cell infiltration; lymphoid nodules; fibrosis	Lymphocytic infiltrates (mild) in parathyroid and adrenal gland
[5]	60	Nulliparous; 5 years postmenopausal; hypoglycemia, anemia, fatigue, arthralgia	Bronchopneumonia	Enlarged; lymphocytic inflammation characterized by lymph follicles, plasma cells, fibrosis	...
			Surgical Findings	Surgical Pathology	
This case	25	Gravida 5, para 5; 5 month history of galactorrhea, amenorrhea, and headaches after last delivery	Enlarged, firm, discolored pituitary gland	Lymphocytic infiltration with lymphoid follicles, well differentiated lymphocytes, and fibrotic bands. Extensive destruction of adenohypophyseal tissue	

ACKNOWLEDGMENT

I thank David Wolfe, Department of Pathology, University of Miami School of Medicine for figure 2 and its description.

REFERENCES

- Goudie RB, Pinkerton PH. Anterior hypophysitis and Hashimoto's disease in a young woman. *J Pathol* 1962;83:584-585
- Hume R, Roberts GH. Hypophysitis and hypopituitarism: report of a case. *Br Med J* 1967;2:548-550
- Egloff B, Fischbacher W, von Groumoens E. Lymphomatose Hypophysitis mit Hypophyseninsuffizienz. *Schweiz Med Wochenschr* 1969;99:1499-1502
- Lack EE. Lymphoid hypophysitis with end organ insufficiency. *Arch Pathol Lab Med* 1975;99:215-219
- Gleason TH, Stebbins PL, Shanahan MF. Lymphoid hypophysitis in a patient with hypoglycemic episodes. *Arch Pathol Lab Med* 1978;102:46-48
- Balagura S, Frantz AG, Housepian EM, Carmel PW. The specificity of serum prolactin as a diagnostic indicator of pituitary adenoma. *J Neurosurg* 1979;51:41-46
- Tindall GT, McLanahan CS, Christy JH. Transsphenoidal microsurgery for pituitary tumors associated with hyperprolactinemia. *J Neurosurg* 1978;48:849-860
- Kolodny HD, Sherman L. Laboratory aids in the diagnosis of pituitary tumors. *Ann Clin Lab Sci* 1979;4:67-86
- Jacobs HS. Prolactin and amenorrhea. *N Engl J Med* 1976;295:954-956
- Simonds JP, Brandes WW. The pathology of the hypophysis. II. Lymphocytic infiltration. *Am J Pathol* 1925;1:273-280
- Shanklin WM. Lymphocytes and lymphoid tissue in the human pituitary. *Anat Rec* 1951;111:177-185
- Bottazzo GF, Pouplard A, Florin-Christensen A, Doniach D. Autoantibodies to prolactin secreting cells of human pituitary. *Lancet* 1975;2:97-101
- Engelberth O, Jezkova Z. Autoantibodies in Sheehan's syndrome. *Lancet* 1965;1:1075
- Wolpert SM, Post KD, Biller BJ, Molitch ME. The value of computed tomography in evaluating patients with prolactinomas. *Radiology* 1979;131:117-119
- Syvrtsen A, Haughton VM, Williams AL, Cusick JF. The computed tomographic appearance of the normal pituitary gland and pituitary microadenomas. *Radiology* 1979;133:385-391