

Are your **MRI contrast agents** cost-effective?

Learn more about generic **Gadolinium-Based Contrast Agents**.



FRESENIUS  
KABI

caring for life

# AJNR

## **Brain Tumors in the First Two Years of Life: CT Diagnosis**

Rina Tadmor, Derek C. F. Harwood-Nash, Mario Savoiardo, Giuseppe Scotti, Mark Musgrave, Charles R. Fitz and Sylvester Chuang

This information is current as of April 19, 2024.

*AJNR Am J Neuroradiol* 1980, 1 (5) 411-417

<http://www.ajnr.org/content/1/5/411>

# Brain Tumors in the First Two Years of Life: CT Diagnosis

Rina Tadmor<sup>1,2</sup>  
 Derek C. F. Harwood-Nash<sup>1</sup>  
 Mario Savoiaro<sup>1,3</sup>  
 Giuseppe Scotti<sup>1</sup>  
 Mark Musgrave<sup>1</sup>  
 Charles R. Fitz<sup>1</sup>  
 Sylvester Chuang<sup>1</sup>

Of all the childhood cerebral neoplasms diagnosed by computed tomography (CT) at the Hospital for Sick Children during a 3-year period (203 cases), about 11% (23 cases) were detected in children under 2 years of age. This incidence is higher than previously reported. Astrocytoma, grades I and II, was the most common diagnosis and it was frequently shown as a very large, invasive lesion. Neoplasms occurred more frequently in boys and were more common in the supratentorial compartment than in older children. Clinical diagnosis of brain neoplasms in infancy is difficult and the child with an enlarging head and only minor clinical signs should be suspected of having a cerebral tumor until proved otherwise. CT, with its high diagnostic sensitivity and ease and safety of performance, has increased the clinical awareness and the diagnosis of these neoplasms in very small children, and may be responsible for the seeming increase of cerebral neoplasms within this age group.

Brain tumors in children of all ages are common and the incidence of neoplasms in the first 2 years of life is surprisingly high [1-4]. Most of these tumors are probably congenital and have frequently grown to involve several lobes by the time they are detected. Despite their large size, they are usually of low-grade malignancy and are amenable to surgical treatment [1-4].

The accurate clinical diagnosis of infant brain tumors may be difficult due to the meager neurologic signs in this young age group. Most of these tumors cause few and often atypical localizing signs. Usually their manifestations are an enlarging head with symptoms of increased intracranial pressure, vomiting, and convulsions. The latter signs may not become evident until many months after the abnormal head growth has been charted and followed clinically. This period of silent, unrecognized growth mediated by open sutures allows many cerebral neoplasms to attain large proportions before they are clinically detected. It is during the early, relatively asymptomatic period of tumor growth that diagnosis by computed tomography (CT) will be most beneficial to the patient. CT is a noninvasive method for diagnosing cerebral neoplasms, and in many instances obviates the need for other invasive neuroradiologic procedures [5-10].

Before CT, the absolute number of neuroradiologically detected brain tumors in patients under age 2 years at the Hospital for Sick Children in Toronto was less than in any other age group [1]. Since the acquisition of CT this absolute number is about equal throughout all age groups until age 14 years. We report the CT findings of brain tumors in children less than 2 years old and try to reestablish a more accurate, albeit altered, incidence of their occurrence and neuroradiologic detection, alterations due directly to the influence of the CT.

## Materials and Methods

All the CT studies were performed on an Ohio-Nuclear Delta 50 scanner with a 256 ×

Received January 14, 1980; accepted after revision May 13, 1980.

<sup>1</sup> Department of Radiology, Hospital for Sick Children, 555 University Ave., Toronto, Ontario M5G 1X8. Address reprint requests to D. C. F. Harwood-Nash.

<sup>2</sup> Presently on leave from Tel-Aviv University, Israel.

<sup>3</sup> Presently on leave from Instituto Neurologico, Milano, Italy.

*AJNR* 1:411-417, September/October 1980  
 0195-6108/80/0104-0411 \$00.00  
 © American Roentgen Ray Society

**TABLE 1: Location and Incidence of Intracranial Neoplasms in Patients Under Age 2 Years**

| Type of Neoplasm          | Location (no.) |                |
|---------------------------|----------------|----------------|
|                           | Supratentorial | Infratentorial |
| Astrocytoma*              | 8†             | 5              |
| Medulloblastoma           | 1              | 4              |
| Neuroglial tumor          | 1              | 0              |
| Teratoma (tuber cinereum) | 1              | 0              |
| Hamartoma                 | 1              | 0              |
| Choroid Plexus Papilloma  | 1              | 0              |
| Rhabdomyosarcoma          | 1              | 0              |
| Total                     | 14             | 9              |

\* Includes three cases of optic glioma.  
 † Includes two cases not verified by biopsy.

256 matrix using a 13 mm collimator and a small scan circle diameter. The x-ray generator was operated at 124 kV and 35 mA; The scanning time was 2 min and a pair of slices was obtained at the end of each scan. Sedation with intramuscular Nembutal (sodium pentobarbital) was used for most patients and general anesthesia was rarely required in this age group. A CT study consisted of a routine noncontrast scan followed by a repeat, enhanced scan after intravenous administration of 3 ml/kg of 60% meglumine diatrizoate. Scans were routinely obtained at about 25° to the orbitomeatal baseline and, whenever feasible, additional scans were obtained at +90°, +60°, and -30° to the baseline (coronal, Towne, and Water projections) by changing the head position and tilting the gantry [11]. Whenever the CT diagnosis of tumor was equivocal, additional investigations such as angiography, pneumoencephalography, or ventriculography were performed.

**TABLE 2: CT Findings and Histologic Diagnosis of Brain Tumors in Infants Under Age 2 Years**

| Histologic Diagnosis, Case No.   | Age (mo), Gender | Tumor Location                     | CT Findings   |   | Hydrocephalus* |
|----------------------------------|------------------|------------------------------------|---|---|----------------|
|                                  |                  |                                    | Precontrast   | Postcontrast                                |                |
| <b>Astrocytoma:†</b>             |                  |                                    |   |   |                |
| 1                                | 3, M             | L thalamus                         | Solid, isodense   | Rim enhancement                             | +              |
| 3                                | 4, F             | R parietooccipital                 | (1) Solid, hyperdense; (2) central, hypodense   | (1) Enhancement; (2) no enhancement         | ++             |
| 4                                | 4½, M            | Postfossa (vermis)                 | Diffuse hypodense   | No enhancement                              | +++            |
| 5                                | 5, F             | Chiasm, hypothalamus, frontal lobe | (1) Solid isodense; (2) cystic hypodense  | (1) Enhancement; (2) no enhancement         | -              |
| 7                                | 6, M             | Optic nerve, chiasm                | Solid, isodense   | Enhancement                                 | -              |
| 8                                | 6, M             | R cerebellum                       | Solid, hyperdense   | Enhancement                                 | ++             |
| 11                               | 10, M            | L optic nerve                      | Solid, isodense   | Enhancement                                 | -              |
| 12                               | 10, M            | R frontoparietal                   | (1) Solid, isodense; (2) cystic hypodense   | (1) Enhancement; (2) no enhancement         | ++             |
| 13                               | 11, M            | R thalamus                         | Solid, hyperdense   | No enhancement                              | ++             |
| 16                               | 16, M            | L temporal                         | Solid, hyperdense   | No enhancement                              | -              |
| 20                               | 18, M            | Postfossa                          | (1) Solid, isodense; (2) cystic, hypodense  | (1) Enhancement; (2) no enhancement         | +++            |
| 22                               | 23, M            | Brain stem, 4th ventricle          | Hypodense   | Enhancement                                 | +              |
| 23                               | 23, M            | Brain stem, 4th ventricle          | Solid, isodense   | ...   | ++             |
| <b>Medulloblastoma:‡</b>         |                  |                                    |   |   |                |
| 2                                | 3, F             | Pineal                             | (1) Solid, isodense; (2) solid, hyperdense  | Both: enhancement                           | +++            |
| 10                               | 9, M             | Cerebellum                         | Solid: hyperdense, isodense, hypodense  | Enhancement (irregular)                     | ++             |
| 14                               | 13, F            | Postfossa (vermis)                 | Solid, isodense   | Enhancement                                 | ++             |
| 19                               | 18, M            | Postfossa                          | (1) Solid, isodense; (2) cystic, hypodense  | (1) Enhancement; (2) no enhancement         | ++             |
| 21                               | 23, M            | Vermis, laminar quadrigemina       | Solid, hyperdense   | Enhancement                                 | ++             |
| <b>Neuroglial tumor:</b>         |                  |                                    |   |   |                |
| 6                                | 5, M             | R parietooccipito-temporal         | (1) Solid, isodense; (2) solid, hyperdense; (3) cystic hypodense.<br><i>CALCIFICATION</i> | (1) and (2) Enhancement; (3) no enhancement | ++             |
| <b>Choroid plexus papilloma:</b> |                  |                                    |   |   |                |
| 9                                | 7, F             | 3d ventricle                       | Solid, isodense   | ...   | +++            |
| <b>Teratoma:</b>                 |                  |                                    |   |   |                |
| 15                               | 14, M            | Suprasellar tuber cinereum         | Solid, isodense   | Enhancement                                 | -              |
| <b>Hamartoma:</b>                |                  |                                    |   |   |                |
| 17                               | 16, M            | L frontal                          | (1) Hypodense, (2) solid, hyperdense  | (1) Ring enhancement; (2) enhancement       | -              |
| <b>Rhabdomyosarcoma:</b>         |                  |                                    |   |   |                |
| 18                               | 18, F            | Temporal                           | Solid, hyperdense   | Enhancement                                 | -              |

\* - indicates that hydrocephalus was absent; +, ++, and +++ indicate increasing degrees of severity to which hydrocephalus was present.  
 † Astrocytomas in cases 7, 11, 16, and 23 were grade I; cases 4, 5, 8, and 20 were grade II; cases 3 and 12 were grade III. In case 1, the astrocytoma was suspect; in case 13, it was presumed, but not biopsied; in case 22 it was either grades I or II.  
 ‡ In case 14, the medulloblastoma was desmoplastic; in case 19 it was cystic.

Fig. 1.—Case 12. Astrocytoma grade III in 10-month-old girl with left hemiparesis and large head of several months. Enhanced axial (A and B) and coronal (C) scans. Large frontoparietal cystic low density lesion with enhancement of solid parasagittal component. Moderate ventricular dilatation. (A and C reprinted from [11].)

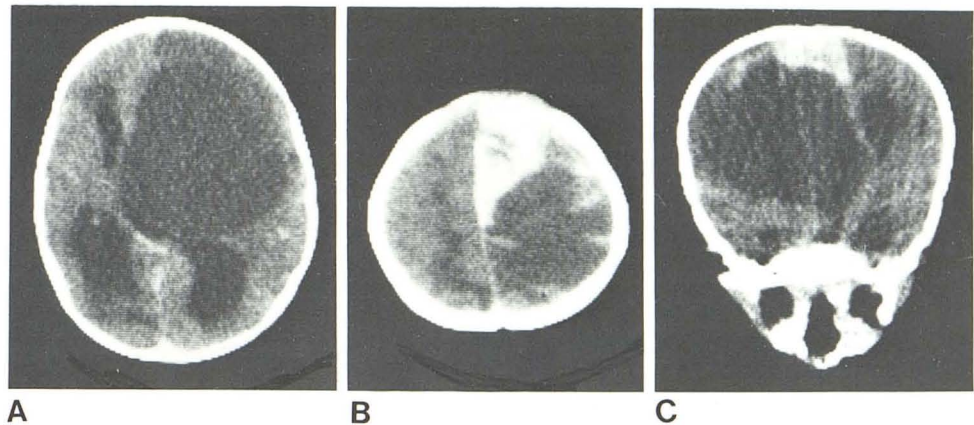
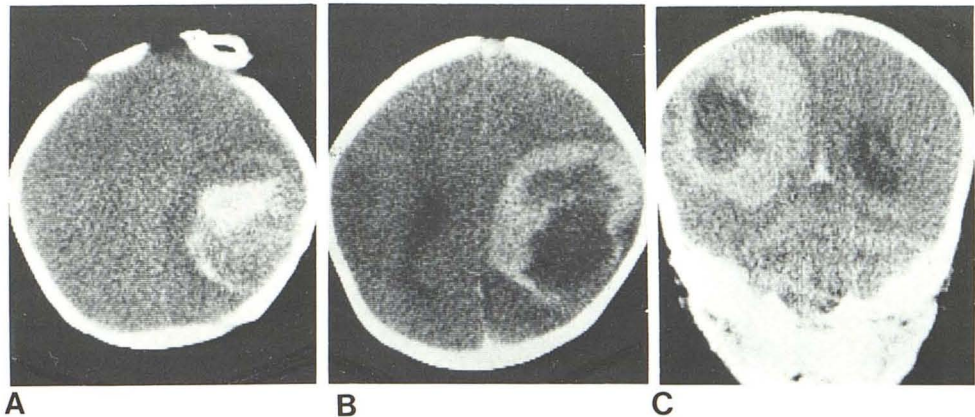


Fig. 2.—Case 3. Astrocytoma grade III in 4-month-old boy with left-sided convulsions and xanthochromic cerebrospinal fluid. A, Unenhanced scan. Non-homogeneous, high density parietal lesion with mild surrounding edema. Dense area is hemorrhage within tumor. No changes evident on enhanced scan (not shown). B, Enhanced scan 3 weeks later. Larger high density lesion with central low density compatible with hemorrhage or necrosis in expanding tumor. C, Coronal scan shows full dimensions of lesion.



During a 3-year period, 203 new cases of brain tumor were diagnosed by CT at the Hospital for Sick Children. This excludes previously diagnosed tumors followed by CT. Orbital tumors and cystic lesions such as arachnoid cysts or porencephalic cysts were also excluded. All cases were pathologically proven by surgical specimens or postmortem verification, except for one case of a thalamic tumor that was not operated on and another thalamic lesion visualized at surgery but not biopsied.

There were 23 (11.3%) patients under 2 years of age, and 13 (6.4%) were less than 1 year. There was a male predominance, with 17 boys and six girls. In 14 (61%) cases the tumors were supratentorial in location and in nine (39%) cases infratentorial (table 1).

## Results

While attenuation values were measured in all our cases both before and after contrast enhancement, we prefer to relate the CT appearances to the density of normal brain tissue, the lesions being described as either hypo-, iso-, or hyperdense. Descriptive terms for patterns of enhancement and for solid or cystic lesions are used in the text as in table 2.

Astrocytoma was the most frequently found tumor (13 cases). There were five cases of medulloblastoma, one of which was supratentorial in location. There was one each of the following: neuroglial tumor, teratoma, hamartoma, cho-

roid plexus papilloma, and rhabdomyosarcoma with intracranial extension.

Most of the tumors were extensive, involving more than one cerebral lobe. The CT findings and histologic diagnosis are presented in table 2. The general CT appearance of the *astrocytomas* (figs. 1–3) on an unenhanced scan was that of a solid, isodense, and/or hyperdense mass with an adjacent low density or cystic area. After intravenous administration of contrast material, marked enhancement of the solid component occurred. In some cases the solid component was limited to an enhancing mural nodule; in a few instances peripheral rim enhancement occurred. No enhancement of the low density, cystic lesion itself was ever seen.

*Medulloblastoma* appeared on precontrast study as a solid, isodense lesion occasionally associated with hyper- or even hypodense areas, while in one case the lesion was totally hyperdense. They were usually situated in the midline of the posterior fossa, with displacement or obliteration of the fourth ventricle. After intravenous contrast injection, patchy enhancement occurred and supratentorial extension from the vermis or involvement of the brain stem was sometimes appreciated (fig. 4). However, some lesions contained a cystic component in a predominantly solid mass (fig. 5).

Three tumors involved the *optic tract and chiasm*, two of which were huge (fig. 6.). On the precontrast scans they

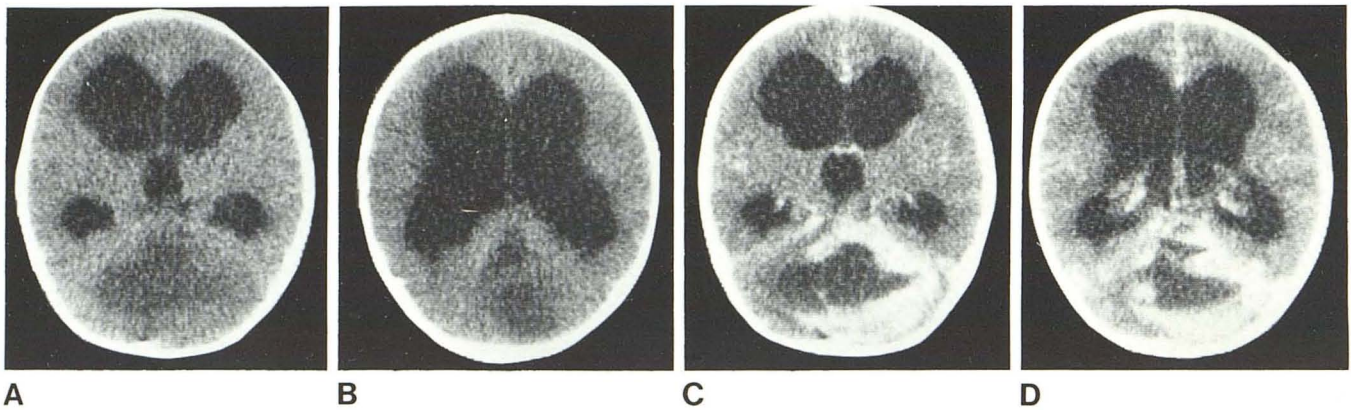


Fig. 3.—Case 20. Astrocytoma grade II in 18-month-old boy with enlarging head and ataxia. **A** and **B**, Unenhanced scans. Severe hydrocephalus with

diffuse hypodensity involves most of posterior fossa. **C** and **D**, Enhanced scans. Marked peripheral enhancement of posterior fossa lesion.

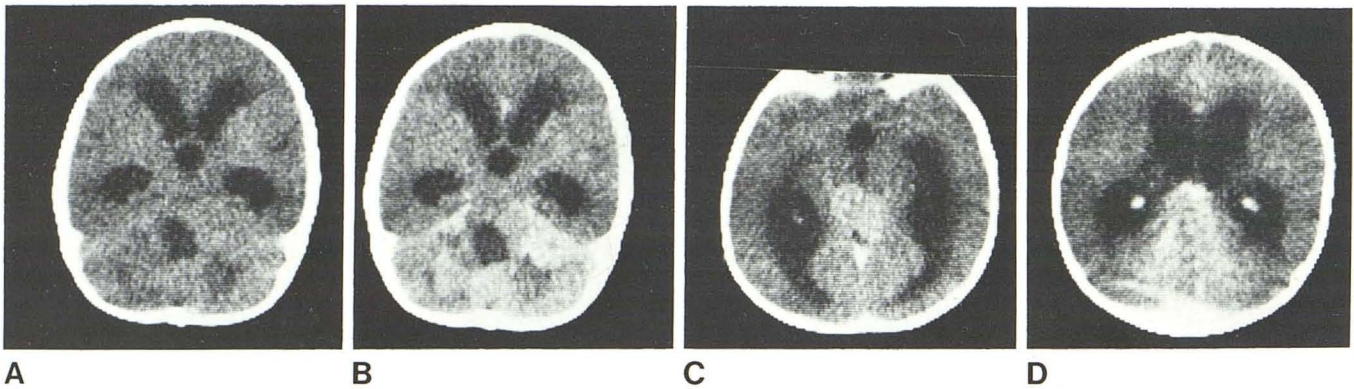


Fig. 4.—Case 10. Cerebellar medulloblastoma in 9-month-old infant with previous vomiting and poor head control. **A**, Unenhanced scan. Mixed hyper-, iso-, and hypodense posterior fossa lesion, moderate ventricular

enlargement, and tilting of fourth ventricle. **B-D**, Enhanced scans. Diffuse enhancement of iso- and hyperdense regions (**B**). On semiaxial cuts (**C** and **D**), supratentorial tumor extension to posterior part of third ventricle.

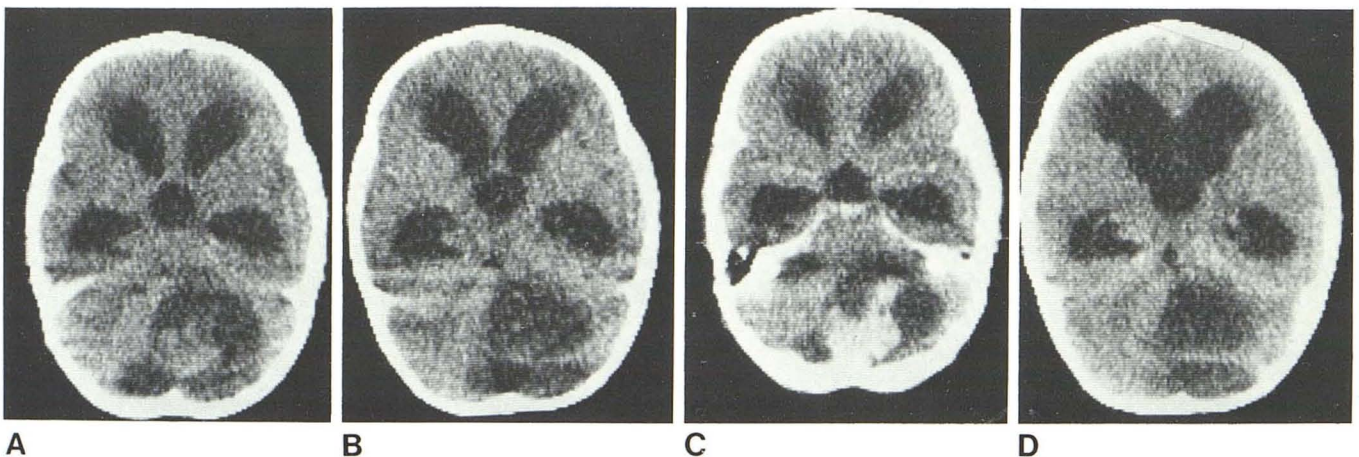


Fig. 5.—Case 19. Cystic medulloblastoma in 18-month-old boy with papilloedema and large head. **A** and **B**, Unenhanced scans. Hydrocephalus and isodense solid posterior fossa nodule with large cystic low density area

incorporating fourth ventricle. **C** and **D**, Enhanced scans. Only solid component enhanced. Preoperative diagnosis: cystic astrocytoma.

were solid, isodense lesions with considerable mass effect and they all showed marked enhancement with contrast injection. In one, the contrast enhancement occurred along the entire length of the visual pathway from optic nerve as

far back as the lateral geniculate body, thus demonstrating tumor infiltration along and around the optic pathways (fig. 7). Calcification was present only once, in a case of neuroglial tumor (fig. 8).

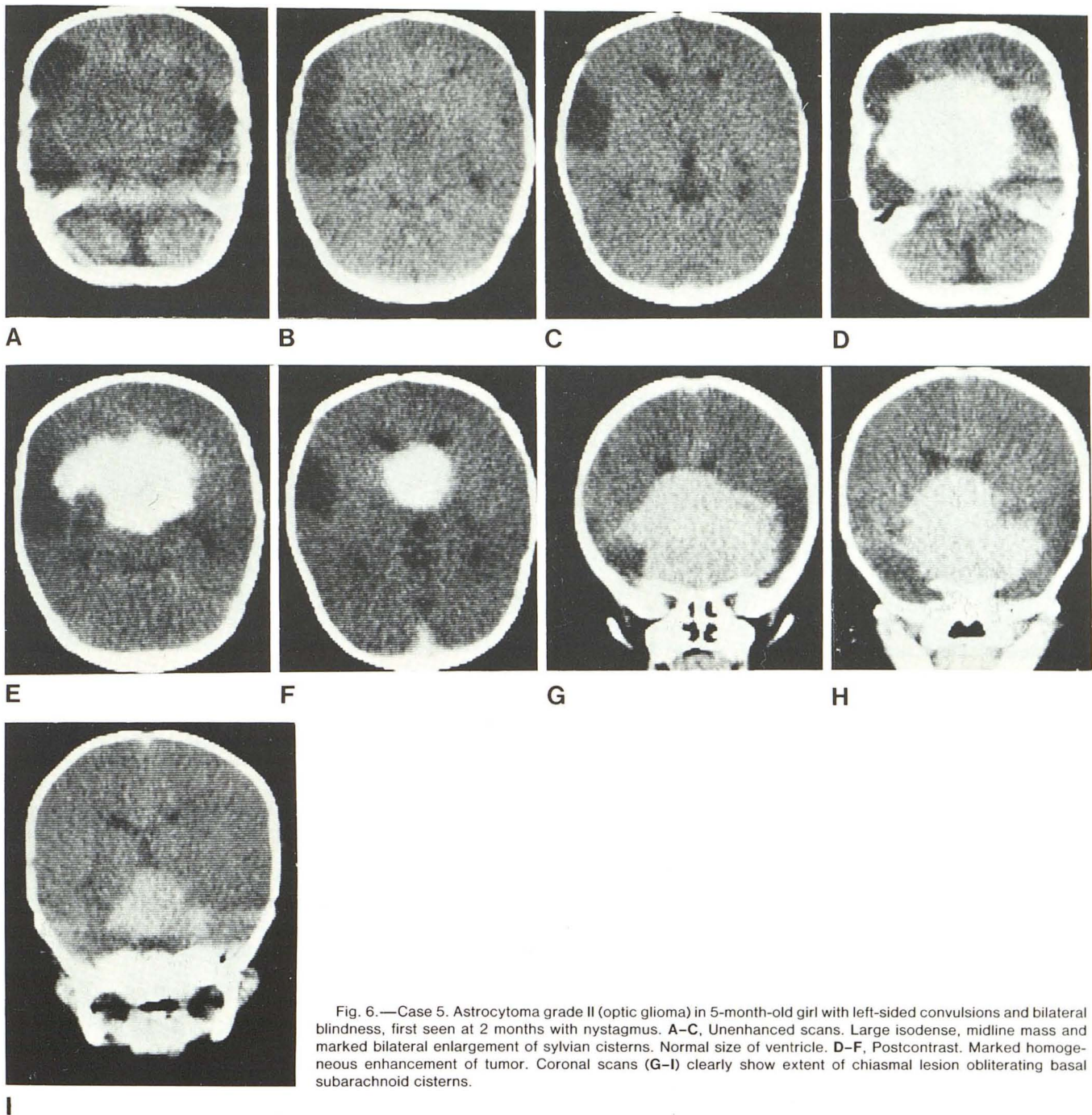


Fig. 6.—Case 5. Astrocytoma grade II (optic glioma) in 5-month-old girl with left-sided convulsions and bilateral blindness, first seen at 2 months with nystagmus. A–C, Unenhanced scans. Large isodense, midline mass and marked bilateral enlargement of sylvian cisterns. Normal size of ventricle. D–F, Postcontrast. Marked homogeneous enhancement of tumor. Coronal scans (G–I) clearly show extent of chiasmal lesion obliterating basal subarachnoid cisterns.

*Hydrocephalus* was a frequent finding although not constant. Increased head circumference was also encountered in the absence of hydrocephalus, caused by the tumor bulk itself. All tumors were detected by CT and, in addition, the presence of obstructive hydrocephalus and details of tumor spread could be accurately assessed on CT. In most instances additional neuroradiologic studies were performed and contributed to the diagnosis, particularly in two cases: (1) a teratoma of the tuber cinereum that was best visualized on pneumoencephalography and (2) a choroid plexus pap-

illoma of the lateral and third ventricles best demonstrated at angiography.

#### Discussion

We have shown that, of all childhood cerebral tumors diagnosed on CT at the Hospital for Sick Children during a 3-year period (203 cases), about 11% (23 cases) were detected in children under 2 years of age. A review of the

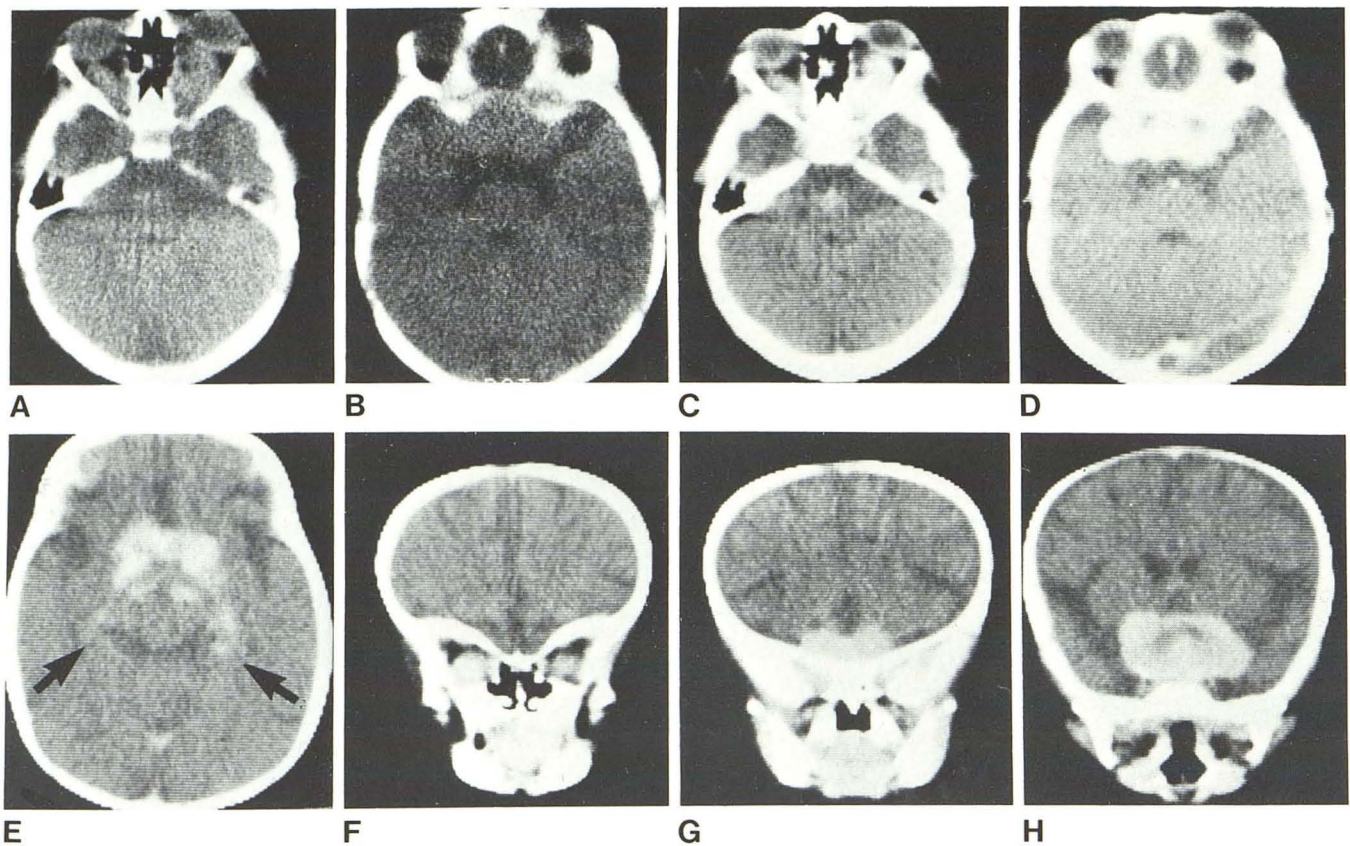


Fig. 7.—Case 7. Astrocytoma grade I (optic glioma) in 6-month-old boy with right proptosis, nystagmus, bilateral optic atrophy, and enlarging head. A and B, Unenhanced scans. Bilateral isodense optic nerve enlargement and large isodense tumor of chiasm. C–E, Enhanced scans. Marked enhancement

of tumor of optic nerves, chiasm, and optic tracts back to lateral geniculate bodies (arrows). F–H, Coronal scans delineate extent of tumor and bilateral entrapment of sylvian cisterns. Ventricular dilatation absent.

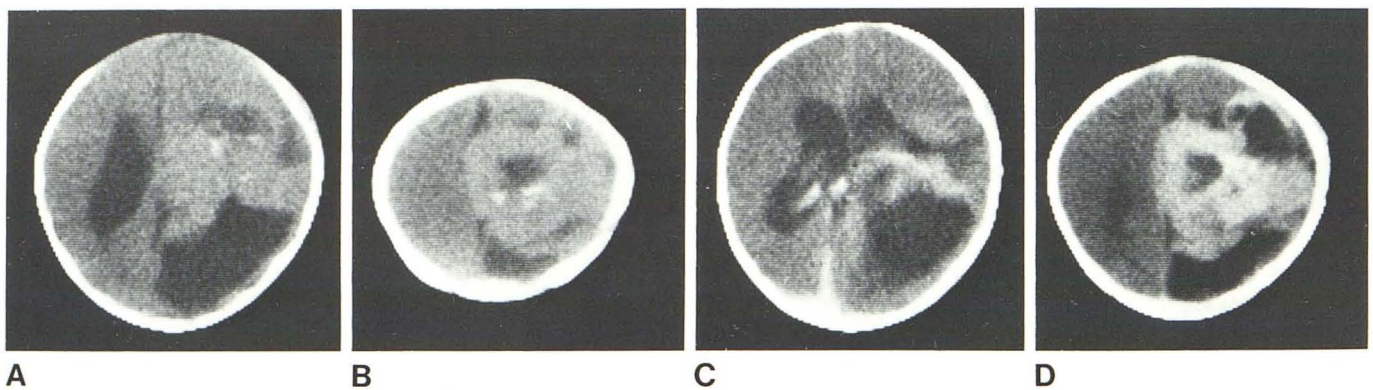


Fig. 8.—Case 6. Neuroglial tumor in 5-month-old boy with enlarged head after a fall, evaluated for possible subdural hematoma. A and B, Unenhanced scans. Scattered calcifications within combined cystic and solid parietal

lesion and hydrocephalus. C and D, Enhanced scans. Marked enhancement of solid component of lesion.

literature reveals that this is higher than previously reported [1–4].

This is also markedly different from our previous series of 575 children before the advent of CT [1], where the incidence of cerebral neoplasms under age 2 years was 8%, the incidence in ages 4–6 years was 20%, and in other age groups it was significantly higher. We believe the influence of the ease and accuracy of CT diagnosis in infants is

responsible for the increase in absolute numbers and relative incidence of neoplasms in the birth to 2 years age group.

Most cases revealed very bulky lesions, frequently associated with obstructive hydrocephalus. There were no false-negative CT examinations in this series, however repeat CT may better demonstrate a lesion only suspected on the initial scan [6] (case 3, fig. 2).

CT appearances of tumors in childhood are essentially the same as those in the adult and the same criteria apply regarding the use of contrast enhancement. Hemorrhage within, or associated with, a tumor is of course best diagnosed on a nonenhanced scan. Diffuse collections of fine punctate calcification creating a relatively homogeneous density is difficult to differentiate from an area of bleeding within the tumor. Pre- and postcontrast scans must be obtained for better appreciation of those isodense tumors that may enhance after intravenous injection of contrast material, and in those cases of very vascular lesions such as choroid plexus papillomas.

One of our cases had only an unenhanced scan due to machine failure. This revealed a solid, isodense mass within the third and lateral ventricles and associated hydrocephalus. A diagnosis of choroid plexus papilloma was suggested on the CT findings and sustained by angiography. While another of our cases of choroid plexus papilloma (not included in this series) was diagnosed by radionuclide brain scan and angiography due to unavailability of the CT scanner at that time, we believe that this diagnosis can be made with confidence on the basis of CT alone [12].

Astrocytomas, the most common tumors in this age group, were usually located in the supratentorial compartment [6, 13]. This supratentorial location influenced the overall distribution of the tumors (table 1) [2]. This preponderance of astrocytomas occurred again in the older 12–16 years age group, but not in the intervening years. In no other age group was the high incidence (61%) of supratentorial location of neoplasms (61% versus 39% infratentorial) equaled or exceeded. We believe this altered incidence is again due to the influence of CT.

The CT appearances of astrocytomas as outlined in our results are by no means pathognomonic. Among posterior fossa tumors, medulloblastomas may produce similar CT changes and we have not found CT density readings and patterns of enhancement useful, when considered on their own, in predicting the histology of any given lesion. Two astrocytomas of the optic pathways (figs. 6 and 7) were huge and had a very bulky chiasmatic component. There were associated entrapment and enlargement of the subarachnoid spaces around the lesion and in one case (fig. 6) the tumor seemed to reach the foramen of Monro, but despite this, there was no evidence at all of ventricular dilatation. It is interesting that in case 7 (fig. 7), the postcontrast scan demonstrated tumor spread along the optic pathways, a finding not previously reported. Calcification may be present in neuroglial tumors, as in case 6 (fig. 8), and occasionally may be seen in ependymomas and medulloblastomas [14, 15].

The histologic spectrum of cerebral neoplasms in this age

group is different in that ependymomas are rarely diagnosed and that the growth of astrocytomas and teratomas is much more rapid than observed in older children. This growth activity is also more clearly determined by the CT.

We believe that the clinically silent nature of intracranial neoplasms in infancy and their often unusually large size need to be emphasized. An enlarging head should not be assumed to merely indicate hydrocephalus. Early CT and a complete neuroradiologic workup must be performed to exclude the presence of a clinically silent tumor.

#### REFERENCES

1. Harwood-Nash DC, Fitz CR. *Neuroradiology in infants and children*, vol 2. St. Louis: Mosby, 1976:668
2. Matson DD. *Neurosurgery in infancy and childhood*. Springfield IL: Thomas, 1969:403
3. Matson DD. Intracranial tumors of the first two years of life. *West J Surg* 1964;72:117–122
4. Koos WT, Miller MH. *Intracranial tumors of infants and children*. St. Louis: Mosby, 1971
5. Berger PE, Kirks DR, Gilday DL, Fitz CR, Harwood-Nash DC. Computed tomography in infants and children. Intracranial neoplasms. *AJR* 1976;127:129–137
6. Kazner E, Meese W, Kretschmar K. The role of computed tomography in the diagnosis of brain tumors in infants and children. *Neuroradiology* 1978;16:10–12
7. Davis KR, Poletti CE, Roberson GH, Tadmor R, Kjellberg RN. Complementary role of computed tomography and other neuroradiologic procedures. *Surg Neurol* 1977;8:437–445
8. Epstein F, Naidich TP, Chase NE, Kricheff II, Linn JP, Ransohoff J. Role of computerized axial tomography in diagnosis and treatment of common neurosurgical problems of infancy and childhood. *Childs Brain* 1976;2:111–131
9. Rappaport ZH, Epstein F. Computerized axial tomography in the preoperative evaluation of posterior fossa tumors in children. *Childs Brain* 1978;4:170–179
10. Harwood-Nash DC, Breckbill DL. Computed tomography in children. A new diagnostic technique. *J Pediatr* 1976;89:343–357
11. Byrd SE, Harwood-Nash DC, Barry JF, Fitz CR, Boldt DW. Coronal computed tomography of the skull and brain in infants and children. *Radiology* 1977;124:705–709
12. Coin CG, Coin JW, Glover MB. Vascular tumors of the choroid plexus: diagnosis by computed tomography. *J Comput Assist Tomogr* 1977;1:146–148
13. Zimmerman RA, Bilaniuk LT, Bruno L, Rosenstock G. Computed tomography of cerebellar astrocytoma. *AJR* 1978;130:929–933
14. Zimmerman RA, Bilaniuk LT, Pahljajui H. Spectrum of medulloblastomas as demonstrated by computed tomography. *Radiology* 1978;126:137–141
15. Zimmerman RA, Bilaniuk LT. Computed tomography of intracerebral gangliogliomas. *CT* 1979;3:24–30