

Are your **MRI contrast agents** cost-effective?

Learn more about generic **Gadolinium-Based Contrast Agents**.



FRESENIUS  
KABI

caring for life

**AJNR**

## **$^{31}\text{P}$ Spectroscopy in Thrombolytic Treatment of Experimental Cerebral Infarct**

Benjamin C. P. Lee, John M. Brock, Teresa Fan, Anthony Seibert, Chrit Moonen, Phillip Kissel, Bahram Chehrazi and E. Morton Bradbury

This information is current as of April 19, 2024.

*AJNR Am J Neuroradiol* 1989, 10 (1) 47-52

<http://www.ajnr.org/content/10/1/47>

# <sup>31</sup>P Spectroscopy in Thrombolytic Treatment of Experimental Cerebral Infarct

Benjamin C. P. Lee<sup>1,2</sup>  
 John M. Brock<sup>3</sup>  
 Teresa Fan<sup>3</sup>  
 Anthony Seibert<sup>1</sup>  
 Chrit Moonen<sup>3</sup>  
 Phillip Kissel<sup>4</sup>  
 Bahram Chehrazi<sup>4</sup>  
 E. Morton Bradbury<sup>3</sup>

Ischemic changes produced by autogenous clot embolization of intracranial arteries were monitored by continuous surface-coil <sup>31</sup>P spectroscopy in 12 rabbits: six were used as controls and six were treated intravenously with tissue-type plasminogen activator. The animals were sacrificed and the brains were fixed with intravital stains.

The results indicate that spectral changes are reversible only when thrombolysis therapy is started within 30 min after ischemic changes are detected. The improvement of the <sup>31</sup>P spectrum correlated with postmortem changes.

Tissue-type plasminogen activator (tPA)\* is a thrombolytic agent recently approved by the FDA for the treatment of coronary occlusions [1, 2]. Since it is a naturally occurring agent that acts specifically on clots without inducing excessive bleeding in normal tissues, it may be potentially useful in the treatment of thrombotic disease of the cerebral arteries [3, 4]. It is known from experimental and clinical trials that thrombolysis is effective when tPA is administered intravenously within 3 hr of clot occlusion [5–7]. Arteries in the brain, unlike coronary vessels, are end arteries, unable to sustain prolonged ischemia because of the absence of collateral circulation [8–10]. Therefore, irreversible damage from arterial occlusions occurs much sooner in the brain than in the heart. Since conventional imaging techniques usually do not detect changes until several hours after they occur, other, nonimaging, methods must be used to monitor early ischemia [11–20]. The aim of this study is to develop an experimental model of cerebral ischemia in which the occlusions and effects of thrombolysis therapy may be evaluated by angiography, <sup>31</sup>P spectroscopy, and postmortem intravital stains.

## Materials and Methods

Twelve New Zealand white rabbits underwent carotid artery embolization with autogenous clots: six rabbits were used as controls and six were treated with tPA. <sup>31</sup>P spectroscopy was performed on a 20-cm-bore 1.9-T Oxford TMR with Larmor frequency of 32.5 MHz. Magnetic field inhomogeneities were reduced by maximizing the root mean square of the H<sup>1</sup> with shim coils. We used a single-loop, double-tuned surface coil that measured 1 × 1.5 cm. The coil was placed in the center of the magnet and the heads of the animals were manipulated so that the hemisphere under evaluation was directly underneath. Spectral changes to a depth corresponding to the radius of the coil were detected. In addition to brain changes, spectra from the scalp and some from the contralateral hemisphere were also recorded.

To ascertain that a surface coil placed on the scalp recorded true brain spectra, a series of comparison experiments was performed: spectra were obtained by placing the coil (1) on the scalp, (2) on the skull after surgical removal of muscles, and (3) directly on the brain surface after a craniectomy was performed. There were no detectable differences in the appearance of the spectra from these locations. To optimize the sequences, different pulse widths were tried. A pulse width of 20 μsec was found to have adequate penetration through the brain surface and produced a spectrum with optimal signal/noise ratio. A repetition time of 2000 msec was selected, as it produced the best spectrum [16–18, 21]. At least 10 min

This article appears in the January/February 1989 issue of *AJNR* and the March 1989 issue of *AJR*.

Received December 31, 1987; accepted after revision June 19, 1988.

This work was supported by an NIH Regional

<sup>1</sup> Department of Radiology, University of California, Davis Medical Center, Sacramento, CA 95817.

<sup>2</sup> Department of Radiology, University of Minnesota Hospital and Clinic, Box 292, 420 Delaware St., S.E., Minneapolis, MN 55455. Address reprint requests to B. C. P. Lee.

<sup>3</sup> Department of Biochemistry, University of California, Davis Medical Center, Sacramento, CA 95817.

<sup>4</sup> Department of Neurological Surgery, University of California, Davis Medical Center, Sacramento, CA 95817.

*AJNR* 10:47–52, January/February 1989

0195–6108/89/1001–0047

© American Society of Neuroradiology

\* Tissue-type plasminogen activator (tPA) supplied by Genentech, Inc., South San Francisco, CA.



was required for the accumulation of data to produce an adequate spectrum. Spectra were recorded continuously every 10 to 20 min throughout the experiments.

Digital angiograms were recorded with an ADAC DPS4100 unit, with one 0.6-mm focal spot, a 4.5- or 6-in. field of view, 4 $\times$  magnification, and 512  $\times$  512  $\times$  8-bit digitalization of the video signal produced by the TV camera. Selective angiography was performed by using transfemoral catheterization with 3-French catheters. Documentation of catheter placement was confirmed with digital subtraction imaging at three frames/sec using pre- and postiodinated contrast images.

Autogenous clots were prepared by injecting a 5-ml syringe of clotted blood through a 22-gauge needle into saline. The internal diameter of 0.394 mm resulted in clots of less than 400  $\mu$ m. The strings of clots were cut up into small fragments and washed several times with saline until the supernatant fluid was clear. Clots suspended in saline were placed in 2-ml syringes and injected in small fractions every 10–15 sec through the catheter.

We administered tPA with an IV bolus of 0.5 mg/kg followed by an infusion of 1 mg/kg/hr. We performed intravital tissue stainings with 2-3-5- triphenyl tetrazolium chloride (TTC) by in vivo infusion after cannulation of the right atrium [21]. Extensive craniectomies were then performed and the brains were fixed in buffered formalin. This stain was taken up by active mitochondria but not by ischemic tissue.

The  $^{31}$ P spectra were analyzed by using the following criteria: the amplitudes of the PCr, Pi, gamma, beta, and alpha peaks of adenosine triphosphate (ATP) were determined. The areas under these peaks were estimated by triangulation to determine the relative quantity of these compounds [22]. The pH in each study was calculated by the amount of chemical shift in parts per million (ppm) between the inorganic phosphate intensity (Pi) and phosphocreatine (PCr) peaks.

The surface of the cerebral hemispheres were inspected after intravital staining with TTC. Perfused regions took up the stain and appeared red, whereas unperfused ischemic areas did not stain and were pale.

#### Control Group (Six Animals)

Autogenous clots were injected directly into the internal carotid artery in three animals and into the common carotid artery in the remaining animals (Fig. 1). Repeat digital angiograms were obtained

after each injection of emboli to monitor the extent of the occlusions. Embolizations were considered successful when no vascularity was detected in the entire hemisphere or in the portion supplied by the middle cerebral artery. The animals were then transferred to the TMR and  $^{31}$ P spectroscopy was performed continuously 90–180 min after embolization. Spectroscopy was not possible earlier because of transportation and set-up time. Angiography was repeated before killing the animals to ensure that there was no recanalization of the embolized vessels. The brains were then stained with intravital TTC.

#### Thrombolysis Group (Six Animals)

*Group 1.*—In three animals the internal or common carotid arteries were catheterized. Emboli were injected and monitored the same way as in the controls until the hemispheres showed a lack of vascularity. The animals were transferred to the TMR, and continuous  $^{31}$ P spectra were obtained as soon as possible (usually 60–80 min after embolization). Thrombolysis was started as soon as the first spectrum was available and demonstrated ischemia. No baseline  $^{31}$ P was obtained in these animals. Treatment was continued for up to 240 min, when a repeat angiogram was performed prior to sacrifice.

*Group 2.*—Three animals were placed in the TMR scanner immediately after catheterization of the common carotid artery, and baseline and continuous spectra were obtained. The emboli were injected repeatedly, with the same amount and at the same rate as in the controls, every 10 min until an abnormal  $^{31}$ P spectrum was obtained, at which time the embolization was terminated. After the next sequential  $^{31}$ P spectrum confirmed ischemia, tPA infusion was started. This treatment was continued until  $^{31}$ P spectra returned partially or completely to normal. The animals were removed from the scanner and a repeat angiogram was performed to show the degree of recanalization achieved prior to sacrifice (Fig. 2).

## Results

#### Control Group ( $^{31}$ P Spectra)

There was progressive increase of Pi with time. Initially, the PCr was maintained relatively high but dropped dramatically after 120 min. There were corresponding changes in the Pi/PCr ratios.

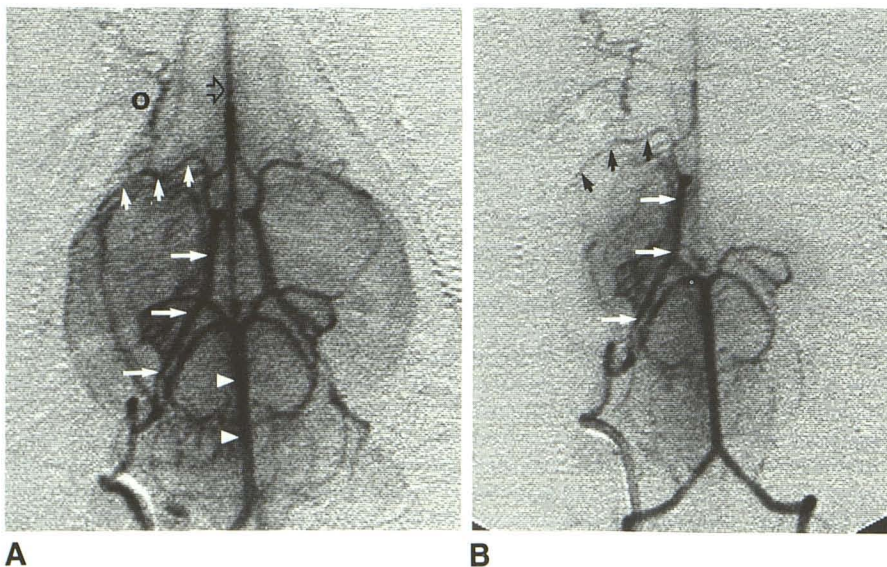


Fig. 1.—Anteroposterior view of internal carotid injection.

A, Normal internal carotid with cross filling of contralateral and vertebrobasilar circulations.

B, After embolization. Note occlusion of proximal middle cerebral artery (short arrows, A and B). Posterior circulation fills via posterior communicating artery. Internal carotid (long arrows, A and B); middle cerebral artery (short arrows, A and B); anterior cerebral artery (open arrow, A); basilar artery (arrowheads, A); O = ophthalmic artery.



The degree of ischemia, as shown by the lack of brain parenchyma staining with TTC, was extremely variable, involving the entire hemisphere in one case (Fig. 3) and multiple areas in the middle cerebral artery region in four cases (with additional involvement of the posterior circulation in one other case) (Fig. 4).

#### Thrombolysis Group (<sup>31</sup>P Spectra)

*Group 1.*—There was no reversal of the ischemic changes (Fig. 5). The ischemic areas shown in the TTC-stained tissue sections were very similar to those seen in the control group.

*Group 2.*—The baseline PCr/Pi was approximately 2 ( $\pm$  0.15). Total reversal of <sup>31</sup>P spectra was achieved in one animal (Fig. 6); in the other two animals, there was partial reversal of

<sup>31</sup>P spectra (Fig. 7). Ischemic areas were demonstrated in all three animals in the TTC-stained brains, and were less extensive in distribution than in the control group (Fig. 8).

#### Discussion

Brain storage of high-energy PCr is interchangeable with ATP, which is required for cerebral metabolism. During normal aerobic activity, ATP is produced within the mitochondria by oxidative phosphorylation. When oxygen is unavailable during anoxia or ischemia, anaerobic metabolism is necessary. This mechanism is, however, inefficient and the ATP required for net metabolism has to be supplemented by depletion of the PCr pool. Metabolic by-products of this activity are Pi and lactic acid, which result in metabolic acidosis (Fig. 9) [23]. <sup>31</sup>P

Fig. 2.—Anteroposterior view of common carotid injection.

*A,* After embolization there is occlusion of carotid bifurcation. Proximal portion of carotid artery is patent (arrowheads). Note occlusion of a number of external branches.

*B,* Right distal carotid (long arrow), middle (short arrows), and internal carotid (arrowheads) arteries have recanalized after tPA infusion.

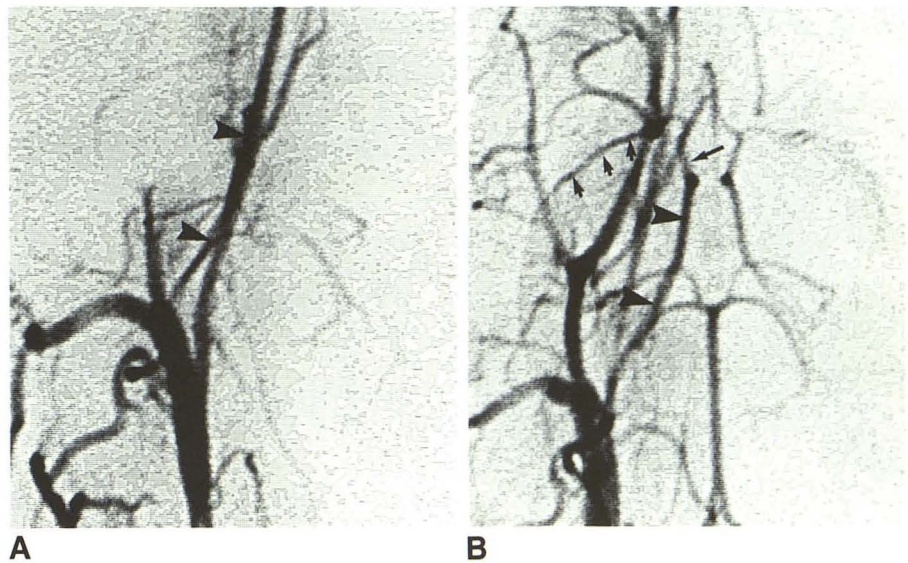


Fig. 3.—View of TTC-stained brain seen from top. Lack of staining of entire left hemisphere and portions of right hemisphere indicates infarcts in these regions (after embolization).

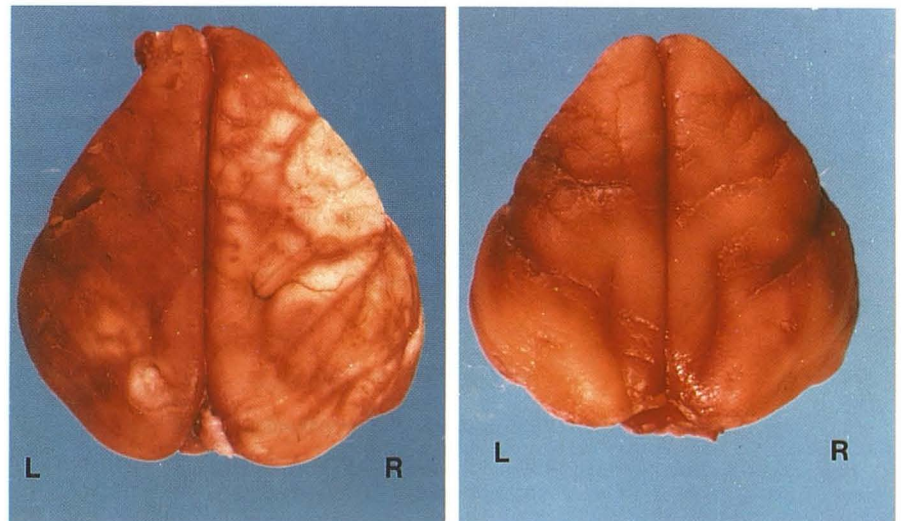


Fig. 4.—View of TTC-stained brain seen from top. Lack of staining of both hemispheres with some preservation at junctional regions (after embolization).





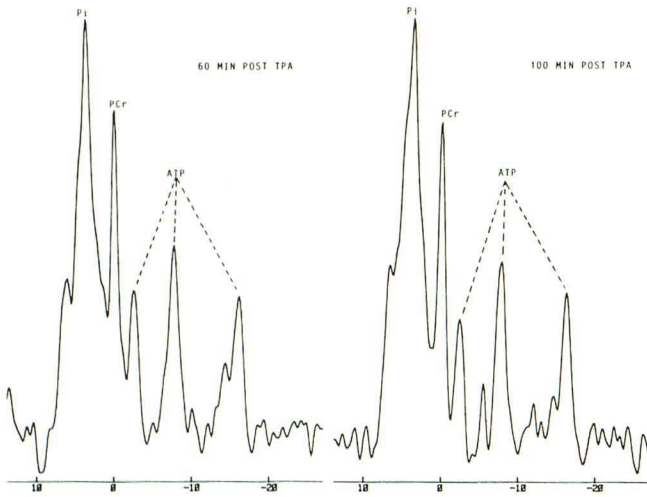


Fig. 5.—<sup>31</sup>P spectra. Severe ischemia caused by embolization is shown by increased Pi and decreased PCr (60 min after embolization). ATP levels are normal. These changes remain constant 60 and 100 min after tPA infusion. (tPA started 60 min after embolization. Thrombolysis, group 1.)

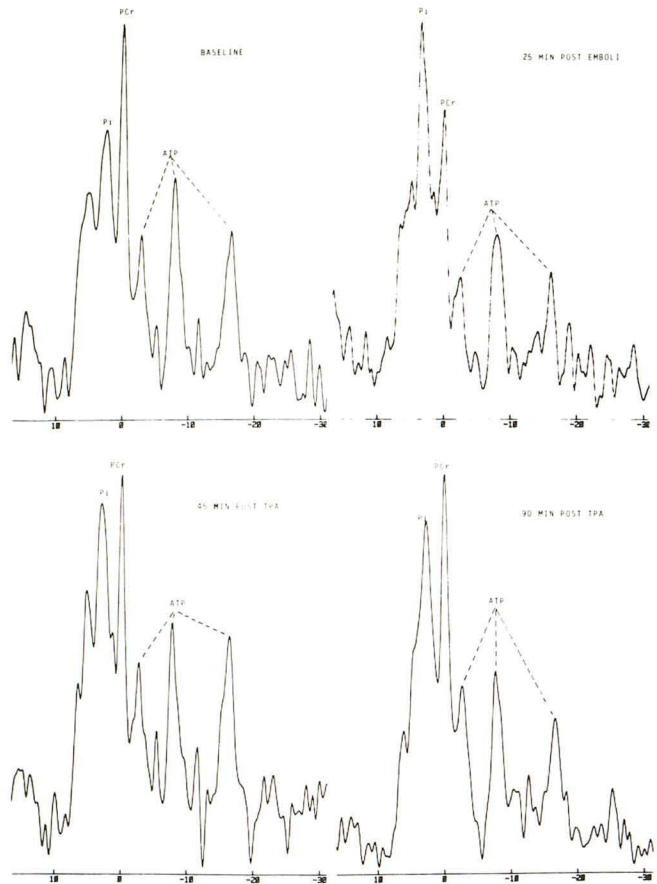


Fig. 7.—*Top*, Ischemic changes are shown 20 min after embolization with reversal of Pi/PCr ratio. ATP remains normal. *Bottom*, Partial reversal of Pi/PCr ratio, remains unchanged 90 min after tPA infusion. (tPA infusion started as soon as <sup>31</sup>P ischemia was detected. Thrombolysis, group 2.)

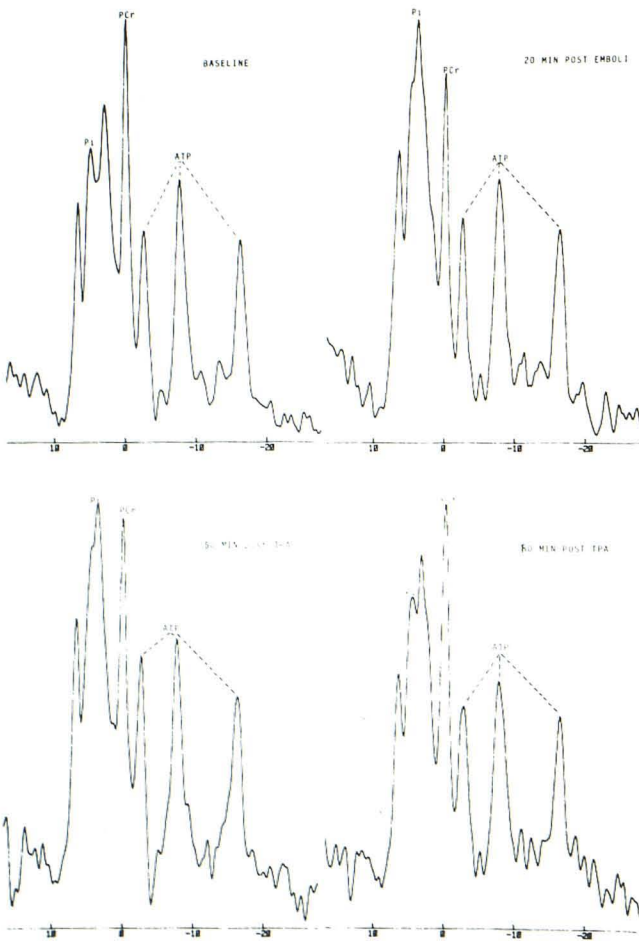


Fig. 6.—*Top*, Ischemic changes are shown 20 min after embolization with reversal of Pi/PCr ratio. ATP remains unchanged. *Bottom*, Reversal of Pi/PCr ratio 50 min after embolization, became normal 18 min after tPA infusion. (tPA infusion started as soon as <sup>31</sup>P ischemia was detected. Thrombolysis, group 2.)

spectroscopy monitors directly the PCr, Pi, and ATP, and, indirectly, the intracellular pH of the brain [15, 16, 22, 23].

The <sup>31</sup>P spectrum is formed by the relative precessional frequencies of the different energy phosphates detectable by MR imaging. The frequencies are determined by the electronic environment surrounding the individual nuclei. The Larmor frequency of phosphorus at 1.9 T is approximately 32.5 MHz. The frequency of Pi is approximately 9 ppm downfield from PCr, whereas ATP has three separate frequency peaks corresponding to the gamma, alpha, and beta phosphorus nuclei of ATP with chemical shift of -2.6, -7.7, and -16.5 ppm, respectively, relative (upfield) to PCr. The chemical shift or differences in resonance frequencies of Pi relative to PCr are related to the intracellular pH.

The area under the <sup>31</sup>P peaks is proportional to the quantity of phosphate compounds detectable by MR imaging and is estimated by the triangulated areas below these peaks [22]. Normally, in brain <sup>31</sup>P spectra, the quantity of Pi is less than half that of PCr (PCr/Pi < 2), which in turn is roughly twice the sum total of the three peaks of ATP (PCr/ATP = 1.93 ± 0.12) [24, 25]. During ischemia, when there is a rise of the Pi, there is initially a decrease of the PCr level. The ATP levels decrease

Fig. 8.—TTC-stained rabbit brain, top view (A) and left lateral view (B), shows only a small area of poor staining in distribution of middle cerebral artery. Right hemisphere is normal. (Thrombolysis, group 2.)

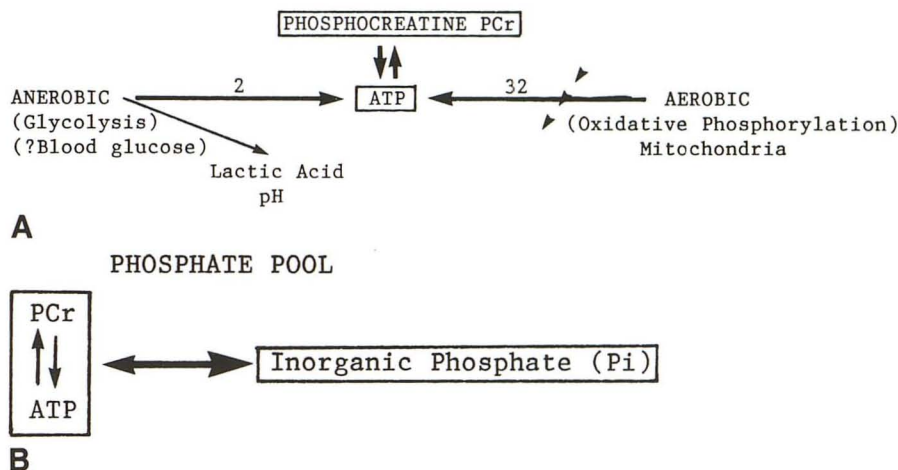
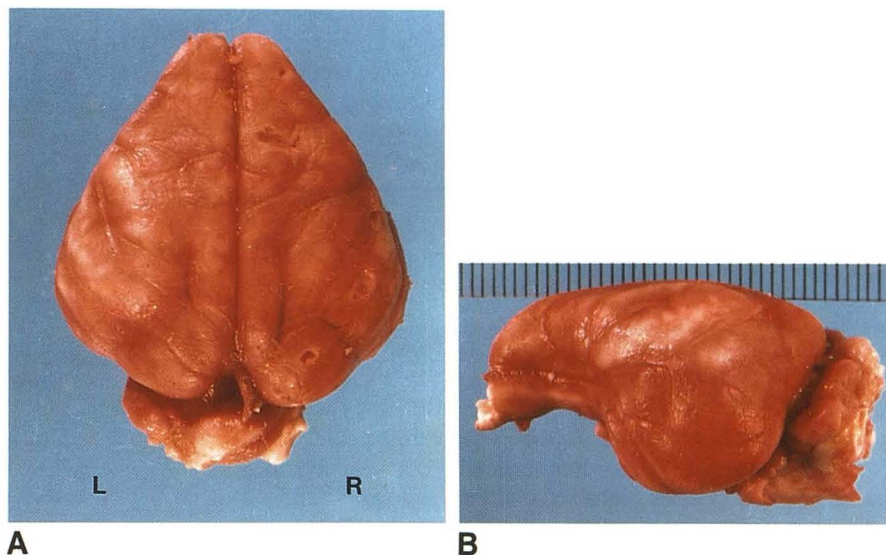


Fig. 9.—Metabolic pathway.  
 A, Normal aerobic metabolism produces 32 units of ATP, which is then stored as high-energy phosphocreatine. Anaerobic metabolism produces only 2 units of ATP but a considerable amount of lactic acid, causing acidosis.  
 B, During anaerobic metabolism, the phosphocreatine pool is depleted and inorganic phosphates (Pi) are produced.

only when the PCr pool begins to be depleted. At this stage, the changes are irreversible and death occurs.

**Embolization**

The rabbit was chosen because human tPA is 60% effective in this experimental animal [26]. The carotid circulation in the rabbit consists of an extensive network of external circulation and small internal carotid arteries [26–28]. The circle of Willis is prominent, however, and allows free communication between the carotid and vertebral basilar circulations. While a large embolus within the cervical portion of the internal carotid artery of a human patient often gives rise to severe infarcts of the cerebral hemispheres, a similarly located experimental embolus in the rabbit usually produces no detectable ischemic <sup>31</sup>P spectral changes because of the effective cross flow within the circle of Willis. The infarcts that are produced by such proximal occlusions tend to be small and inconsistent in size and distribution. Because of the unpredictable nature of the infarcts produced by this technique, we chose to deliver

small emboli more selectively. Clots less than 400 μm were injected through catheters selectively placed in the internal carotid arteries. Because of the small caliber of these vessels relative to the catheter, the arteries were invariably occluded and the air that accumulated within the catheter during the course of selective catheterization could not be purged prior to embolization, resulting in immediate death in several animals. This can be avoided by catheterization of the larger common carotid arteries and nonselective embolization. The cerebral flow carries the small emboli into the peripheral branches of the anterior and middle cerebral circulations and produces large infarcts, involving one or both hemispheres [29].

**Sensitivity**

The surface coil used in this study is designed so that it corresponds as closely as possible to the configuration and size of the cerebral hemispheres. In spite of this, a small amount of signal from the contralateral hemisphere is detect-



able. Unfortunately, since the coil covers a substantial portion of the underlying cerebral hemisphere, the technique is not very sensitive, and large areas of ischemia have to be present before  $^{31}\text{P}$  spectra changes are detected. Likewise, reversal of the  $^{31}\text{P}$  spectra to normal does not imply complete reversal of the pathologic changes, and substantial areas of ischemia may still be present. In general, the ischemic changes shown on TTC-stained brains correlate well with the degree of  $^{31}\text{P}$  spectral reversal after tPA treatment.

### Time

Our angiographic data confirm that tPA is effective in re-opening cerebral arteries at any time after embolization [29]. An increase in Pi is detected in the  $^{31}\text{P}$  spectra as early as 20 min after embolization (thrombolysis, group 2), followed shortly by a decrease in the PCr and an increase in the Pi/PCr ratio, which becomes most pronounced 1–2 hr later (control group). All untreated animals died within 2–3 hr, when the ATP pool was depleted. All treated animals survived. Reversal of  $^{31}\text{P}$  changes probably indicates a decrease in the volume of ischemia and, on the basis of three animal studies, only occurs when tPA is administered within 30 min after embolization. It should be realized, however, that these changes are merely a qualitative indication of the effectiveness of tPA treatment. It is not quantitative because of the relative insensitivity of the methodology and the inconstant degree of ischemia created initially. The exact dosage needed for thrombolysis is also unknown: the amount given is extrapolated from data available from human studies of coronary arteries and may not be optimal for cerebral thrombolysis.

If the animal data can be extrapolated to human cerebral arterial occlusions, tPA may potentially be used in treating iatrogenically produced emboli during angiography.

### REFERENCES

- Del Zoppo GJ, Zeumer H, Harker LA. Thrombolytic therapy in stroke: possibilities and hazards. *Stroke* **1986**;17(4):595–607
- The TIMI Study Group. Special report: the thrombolysis in myocardial infarction (TIMI) trial. Phase I findings. *N Engl J Med* **1985**;31:932–936
- Sloan MA. Thrombolysis and stroke: past and future. *Arch Neurol* **1987**;44:748–768
- Zivin JA, Fisher M, DeGirolami U, et al. Tissue plasminogen activator reduces neurological damage after cerebral embolism. *Science* **1985**;230:1289–1295
- Del Zoppo GJ, Copeland BR, Waltz TA, et al. The beneficial effect of intracarotid urokinase on acute stroke in a baboon model. *Stroke* **1986**;17:638–643
- Del Zoppo GJ, Zeumer H, Harker LA. Thrombolytic therapy in stroke: possibilities and hazards. *Stroke* **1986**;17(4):595–607
- Williams DO, Borer J, Braunwald E, et al. Intravenous recombinant tissue-type plasminogen activator in patients with acute myocardial infarction: a report from the NHLBI thrombolysis in myocardial infarction trial. *Circulation* **1986**;73(2):338–346
- Heiss WD, Rosner G. Functional recovery of cortical neurons as related to degree and duration of ischemia. *Ann Neurol* **1983**;14(3):294–301
- Crowell RM, Olsson Y, Klatzo I, et al. Temporary occlusion of the middle cerebral artery in the monkey: clinical and pathological observations. *Stroke* **1970**;1:439–448
- Diaz FG, Ausman JI, Pearce J. Acute carotid occlusion and related progressive stroke syndromes. In: Long DM, ed. *Current therapy in neurologic surgery, 1985–1986*. Philadelphia: Decker, **1985**:65–88
- Hayman LA, Sakai F, Meyer JS, et al. Iodine-enhanced CT pattern after cerebral arterial embolization in baboons. *AJNR* **1980**;1:233–238
- Inoue Y, Takemoto K, Miyamoto T, et al. Sequential computed tomography scans in acute cerebral infarction. *Radiology* **1980**;135:655–662
- Sipponen JT, Kaste M, Ketonen L, et al. Serial nuclear magnetic resonance (NMR) imaging in patients with cerebral infarcts. *J Comput Assist Tomogr* **1983**;7:585–589
- Gadian RG, Radda GK, Richards RE, et al.  $^{31}\text{P}$  NMR in living tissue: the road from a promising to an important tool in biology in biological applications of magnetic resonance. In: Schulman RG, ed. *Biological applications of magnetic resonance*. New York: Academic Press, **1979**:463–535
- Gordeon RE, Hanley PE, Shaw D, et al. Localization of metabolites in animals using  $^{31}\text{P}$  topical magnetic resonance. *Nature* **1980**;287:736–738
- Ackerman JHH, Grove TH, Wong GC, et al. Mapping of metabolites in whole animals by  $^{31}\text{P}$  NMR using surface coils. *Nature* **1980**;283:167–170
- Bottomley PA, Kozure K, Namon R, et al. Cerebral energy metabolism in rats studied by phosphorus nuclear magnetic resonance using surface coils. *Magn Reson Imaging* **1982**;1:81–85
- Naruse S, Takada S, Koisuka I, et al. In vivo  $^{31}\text{P}$  NMR studies on experimental cerebral infarction. *Jpn J Physiol* **1983**;33:19–28
- Bederson JB, Bartkowski HM, Moon K, et al. Nuclear magnetic resonance imaging and spectroscopy in experimental brain edema in a rat model. *J Neurosurg* **1986**;64:795–802
- Brant-Zawadzki M, Pereira B, Weinstein P, et al. MR imaging of acute experimental ischemia in cats. *AJNR* **1986**;7:7–11
- LaManna JC, McCracken KA. The use of neutral red as an intracellular pH indicator in rat brain cortex in vivo. *Anal Biochem* **1984**;142:117–125
- Gadian DG. *Nuclear magnetic resonance and its application to living systems*. Oxford: Clarendon Press, **1982**:23–70, 122–125
- Roth K. *NMR tomography and spectroscopy in medicine*. Berlin: Springer-Verlag, **1984**:29–47
- Ackerman JHH, Grove TH, Wong GG, Gadian DG, Radda GK. Mapping of metabolites in whole animals by  $^{31}\text{P}$  NMR using surface coils. *Nature* **1980**;283:167–170
- Delpy DT, Gordon PE, Hope PL, et al. Noninvasive investigation of cerebral ischemia by phosphorus nuclear magnetic resonance. *Pediatrics* **1982**;70:310–313
- Korninger C, Collen D. Studies on the specific fibrolytic effect of human extrinsic (tissue-type) plasminogen activator in human blood and in various animal species in vitro. *Thromb Haemost* **1981**;46:561–565
- Scremin OU, Sonnenschein RR, Rubinstein EH. Cerebrovascular anatomy and blood flow measurements in the rabbit. *J Cereb Blood Flow Metabol* **1982**;2(1):55–65
- Jeppsson PB, Olin T. Cerebral angiography in the rabbit: an investigation of vascular anatomy and variation in circulatory pattern with conditions of injection. *Lund Univ Arskkr NF Adv* **1960**;2(56):1–56
- Kissel P, Chehrizi N, Seibert JA, Wagner FC. Digital angiographic quantification of blood flow dynamics in embolic stroke treated with tissue-type plasminogen activator. *J Neurosurg* **1987**;67:399–405