AJNR

Brain abscess as a complication of halo traction: role of CT in diagnosing penetration of the skull.

J Hann and H M de Bakker

AJNR Am J Neuroradiol 1989, 10 (2) 446
http://www.ajnr.org/content/10/2/446.citation

Brain Abscess as a Complication of Halo Traction: Role of CT in Diagnosing Penetration of the Skull

Cerebral abscess is a well-known complication of cranial traction achieved by means of pins attached to the skull. Several reports have described abscesses caused by Crutchfield tongs or other kinds of skull calipers [1]. However, only five reports on cerebral abscesses caused by halo traction have appeared in the literature [2].

Case Report

A 62-year-old patient was admitted to our hospital because of a generalized tonic-clonic seizure. Approximately 3 weeks before, his family had observed lethargy and word-finding difficulty. One year before, he had had a laminectomy of C5, C6, and C7 and diskectomy at C5–C6. Two months after this operation, autologous bone from the iliac crest was placed anteriorly between C5 and C6 because of loss of height of these vertebrae. The cause of this complication could not be found. After this second operation, the patient was treated with halo immobilization. The halo pins were tightened on several occasions without replacement or repositioning. Two weeks before admission, the halo traction had been removed because the pins had become too loose.

On admission, the patient had a temperature of 37°C. Neurologic examination revealed aphasia of the mixed type and a moderate tetraparesis. Perception of vibration was reduced in both lower extremities. Plantar responses were extensor. Erythrocyte sedimentation rate and leukocyte and differential counts were normal. CT scan of the brain showed a left parietotemporal abscess (Fig. 1). Bone setting showed penetration of the inner table of the skull at the parietal pin site.

The patient was treated with phenytoin and antibiotics, and 1 day after admission the abscess was aspirated through the skull defect. Cultures of the apirated material grew no microorganisms. Further seizures did not occur. Disappearance of the abscess was documented on follow-up CT scans. The aphasia improved slowly. Nine months after aspiration of the abscess, the patient had only slight difficulty in finding the right words.

Discussion

Although only five cases of cerebral abscesses as a complication of halo traction have been described, the prevalence of this complication may be greater [3]. Penetration of the inner table at the pin sites is considered to be responsible for the development of the abscesses in most cases. One case without penetration of the skull has been described [4]. Early recognition of intracranial infection is important because treatment will be more effective in the cerebritis stage than in later stages when a firm capsule has already developed [5]. Penetration of the inner table of the skull undoubtedly increases the risk of development of brain abscess. In our case, CT scan of the brain clearly showed penetration at the pin site, which was responsible for abscess formation. To the best of our knowledge, this is the first report of CT documentation of penetration of the inner skull table by halo traction.

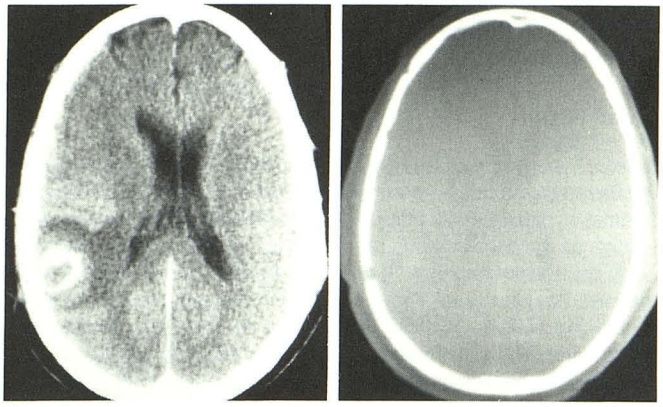

A B

Fig. 1.—Brain abscess as a complication of halo traction.
***A*, CT scan of brain shows a left parietotemporal abscess.**
***B*, Bone setting of scan in *A* shows penetration of inner skull table at pin site.**

CT scans are valuable not only in diagnosing and localizing cerebral abscesses but also in detecting skull penetration. We propose that CT scans in bone setting should be performed in patients shortly after removal of the cranial traction, especially if the pins frequently had to be tightened. CT scans performed when the halo traction is still in place will show many artifacts and are of no use.

J. Haan
H. M. de Bakker
University Hospital
Leiden, The Netherlands

REFERENCES

1. Celli P, Palatinsky E. Brain abscess as a complication of cranial traction. *Surg Neurol* **1985**;23:594–596
2. Goodman ML, Nelson PB. Brain abscess complicating the use of a halo orthosis. *Neurosurgery* **1987**;20:27–30
3. Seljeskog EL. Comment. *Neurosurgery* **1987**;20:30
4. Humbyrd DE, Latimer FR, Lonstein JE, Samberg LC. Brain abscess as a complication of halo traction. *Spine* **1981**;6:365–368
5. Weisberg LA. Nonsurgical management of focal intracranial infection. *Neurology* **1981**;31:575–580