

Are your **MRI contrast agents** cost-effective?

Learn more about generic **Gadolinium-Based Contrast Agents**.



FRESENIUS
KABI

caring for life

AJNR

Balloon Embolization of a Giant Vertebral-Basilar Aneurysm

Guido Guglielmi, Guilio Guidetti, Stefania Mori, Luigi Ferrante
and Pasquale Silipo

AJNR Am J Neuroradiol 1989, 10 (5 suppl) S28-S29
http://www.ajnr.org/content/10/5_suppl/S28.citation

This information is current as
of April 18, 2024.

Balloon Embolization of a Giant Vertebral-Basilar Aneurysm

Guido Guglielmi,¹ Guilio Guidetti, Stefania Mori, Luigi Ferrante, and Pasquale Silipo

Planning therapy is difficult for giant intracranial aneurysms, especially those of the vertebral-basilar circulation, which account for 8% of all giant intracranial aneurysms [1]. Using therapeutic neuroangiographic techniques, it is now possible to evaluate clinical tolerance of the occlusion of the afferent vessel to the aneurysm and to determine whether such an occlusion would effectively exclude the aneurysmal sac from the circulation. This evaluation, the presence or absence of a clippable neck, and the site of the aneurysmal sac are the fundamental elements in deciding whether to operate or to perform a balloon embolization. In this case of a giant aneurysm of the vertebral-basilar junction, balloon embolization was preferred because there was no angiographic evidence of a clippable neck.

Case Report

Four months before admission to our department, a 38-year-old woman presented with sudden neck stiffness after straining, immediately lost consciousness, and became comatose. She regained consciousness 4 days later. An angiogram performed in another hospital shortly after the episode revealed the presence of a giant vertebral-basilar aneurysm. On admission to our department, she complained of right tinnitus. The neurologic examination revealed a peripheral right deficit (cranial nerve VII), a weakened right corneal reflex, and a right trigeminal hypesthesia most pronounced in the first division. With the patient under systemic heparinization, bilateral internal carotid artery and vertebral artery angiograms were performed. Injection of the left vertebral artery showed a giant aneurysm (Fig. 1A) of the vertebral-basilar junction that was not evident after injection of the right vertebral artery. Since it was not possible to identify a clippable neck, we considered the possibility of occluding the left vertebral artery. Via the opposite femoral artery, a double-lumen temporary occlusion balloon catheter* was positioned into the left vertebral artery at C5 level and inflated while the right femoral catheter was maintained in the right vertebral artery. This was done to verify whether the occlusion could be neurologically tolerated by the patient and to assess the effective exclusion of the aneurysm from the circulation. The patient's clinical condition remained un-

changed; therefore, a right vertebral angiogram was carried out during occlusion of the left vertebral artery, and the aneurysm still was not visualized (Fig. 1B). Temporary occlusion of the left vertebral artery lasted 10 min. We decided to perform a definitive balloon occlusion of the left vertebral artery.

Six days later, two Latex balloons (18.5 × 7 mm),[†] filled with contrast material[‡] rendered isoosmotic, were detached into the left vertebral artery at C1 and C2 level. Four days after this, bilateral carotid, right vertebral, and left subclavian angiograms were done; the results were exclusion of the aneurysm from the circulation (Fig. 1C) and retrograde thrombosis of the left vertebral artery (Fig. 1D). Two months later the patient was able to return to work. Twelve months later, the patient had only slight paresis of the right facial nerve.

Discussion

Giant aneurysms are at least 2.5 cm in diameter, and it is thought that they derive from small saccular aneurysms that have gradually increased in size [2]; this is the reason that they often do not have a clippable neck. Many studies deal with closure of the parent artery to induce thrombosis of giant aneurysms of the anterior circulation, which account for 92% of giant intracranial aneurysms. As far as the posterior circulation is concerned, in 1975 Drake [3] reported his experience of ligation of one or both vertebral arteries or the basilar artery for treatment of 21 cases of large intracranial vertebral-basilar aneurysms. Before this, others had attempted this kind of treatment [4] and had studied how the vertebral artery tolerated ligation [5].

In recent years, several case reports have appeared in the literature concerning neuroangiographic treatment of giant vertebral-basilar aneurysms by means of detachable balloons. More precisely, Berenstein et al. [6] and Fox et al. [7] each reported one case of balloon embolization of vertebral artery aneurysms, whereas Debrun et al. [8], Hieshima and coworkers [9, 10], Serbinenko [11, 12], and Fox et al. [7] presented 1, 2, 4, and 5 cases, respectively, of balloon embolization of basilar artery aneurysms. The case reported here is the first

* Medi-tech, Watertown, MA.

[†] Laboratoires Ingenor, 70 rue Orfila, 75020 Paris, France.

[‡] Iopamiro 300, Bracco Industria Chimica, via Folli 50, 20134 Milano, Italy.

Received October 21, 1987; revision requested December 30, 1987; revision received February 23, 1988; accepted February 24, 1988.

¹ All authors: Department of Neurosciences, 2nd Neuroradiology Service, Rome University "La Sapienza," Rome, Italy. Address reprint requests to G. Guglielmi, Dept. Scienze Neurologiche, Servizio di Neuroradiologia Viale dell'Università, 30/a, 00185 Roma, Italy.

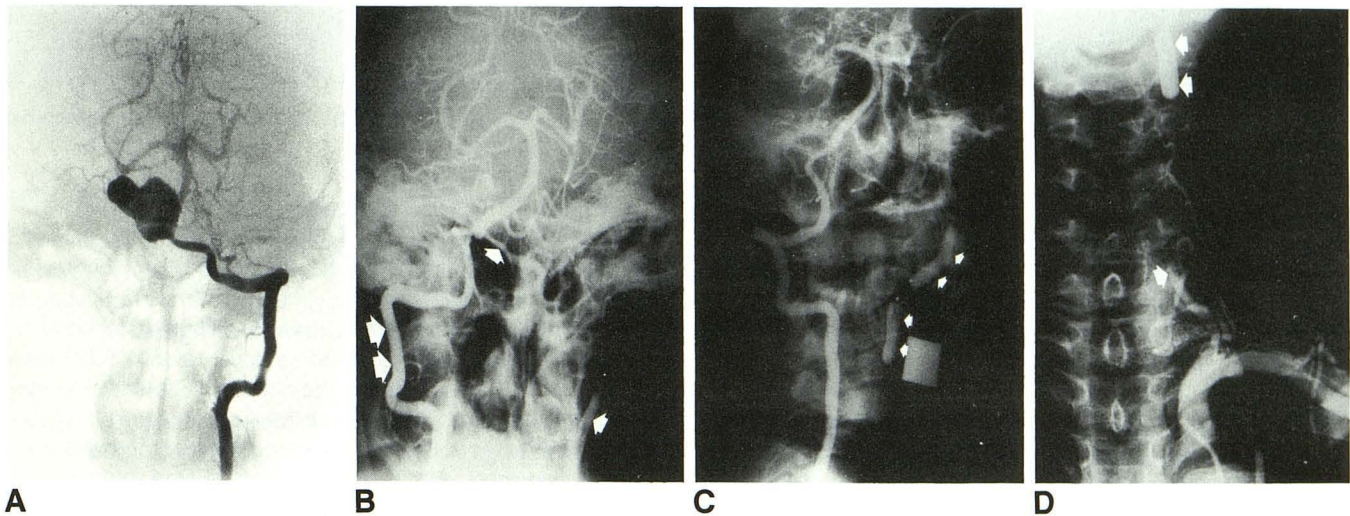


Fig. 1.—A, Left vertebral angiogram showing a giant aneurysm of vertebral-basilar junction. Despite multiple projections, a clippable neck could not be identified. The right vertebral artery did not fill aneurysm but did fill basilar artery and its branches.
 B, Right vertebral angiogram (double arrow) during temporary intravascular balloon occlusion of left vertebral artery. Under these hemodynamic conditions, aneurysm did not fill. Contrast material injected into left vertebral artery distal to occlusion (single arrows) remained inside artery.
 C, Right vertebral angiogram 4 days after detachment of two balloons (arrows) into left vertebral artery at C1 and C2 level. Aneurysm does not fill.
 D, Left subclavian angiogram 4 days after embolization. Retrograde thrombosis of left vertebral artery (arrow); balloon at C2 level (double arrow).

dealing with balloon embolization of a giant aneurysm of the vertebral-basilar junction.

In 1984, at our institute, we began using temporary intravascular arterial occlusion by balloon (functional angiography) and balloon embolization in cases of giant aneurysms. In our experience, whenever an aneurysm presents a surgically clippable neck, this represents the best treatment, because it does not require sacrifice of an artery. In the case of a giant aneurysm with no clippable neck, neuroangiographic treatment appears to be superior to surgical occlusion of the parent artery for the following reasons: (1) there is no need to anesthetize the patient; (2) temporary intravascular occlusion of the artery feeding the aneurysm may be performed to check whether such an occlusion would be neurologically tolerated (functional angiography); and (3) during functional angiography the vertebral artery or the contralateral carotid may be injected to verify whether the aneurysm has been effectively excluded from circulation. Aneurysms of the vertebral-basilar junction do not generally have a clippable neck [2] and are therefore ideally treated by balloon embolization. This case confirms that whenever the aneurysm is fed by only one vertebral artery and the other vertebral artery exists, balloon embolization may be efficacious.

To conclude, we believe that when permanent occlusion of a vertebral artery is necessary, the entire course of the contralateral vertebral artery should be studied, starting from the subclavian artery, in the same way as it is necessary to verify the neck bifurcation of the other carotid when occluding an internal carotid. In fact, if stenosis, atherosclerosis, atherosclerotic plaque, or other vessel alterations are present, the risks connected with balloon embolization are greatly in-

creased because of the potential for diminished flow through the unoccluded vessel.

REFERENCES

1. Pelz DM, Vinuela F, Fox AJ, Drake CG. Vertebrobasilar occlusion therapy of giant aneurysms. Significance of angiographic morphology of the posterior communicating arteries. *J Neurosurg* 1984;60:560-565
2. Drake CG. Giant intracranial aneurysms: experience with surgical treatment in 174 patients. *Clin Neurosurg* 1979;26:12-95
3. Drake CG. Ligation of the vertebral (unilateral or bilateral) or basilar artery in the treatment of large intracranial aneurysms. *J Neurosurg* 1975;43:255-274
4. Mount LA, Taveras JM. Ligation of the basilar artery in treatment of an aneurysm at the basilar artery bifurcation. *J Neurosurg* 1962;19:167-170
5. Shintani A, Zervas NT. Consequence of ligation of the vertebral artery. *J Neurosurg* 1972;36:447-450
6. Berenstein A, Ransohoff J, Kupersmith M, Flamm E, Graeb D. Transvascular treatment of giant aneurysms of the cavernous carotid and vertebral arteries. Functional investigation and embolization. *Surg Neurol* 1984;21:3-12
7. Fox AJ, Vinuela F, Pelz DM, et al. Use of detachable balloons for proximal artery occlusion in the treatment of unclippable cerebral aneurysms. *J Neurosurg* 1987;66:40-46
8. Debrun G, Fox AJ, Drake C, Peerless S, Girvin J, Ferguson G. Giant unclippable aneurysms: treatment with detachable balloons. *AJNR* 1981;2:167-173
9. Hieshima GB, Higashida RT, Wapenski J, Halbach VV, Cahan L, Bentson JR. Balloon embolization of a large distal basilar artery aneurysm. Case report. *J Neurosurg* 1986;65:413-416
10. Hieshima GB, Higashida RT, Wapenski J, Halbach VV, Bentson JR. Intravascular balloon embolization of a large mid-basilar artery aneurysm. Case report. *J Neurosurg* 1987;66:124-127
11. Serbinenko FA. Balloon catheterization and occlusion of major cerebral vessels. *J Neurosurg* 1974;41:125-145
12. Serbinenko FA. Fifteen years of endovascular neurosurgery. *Seara Med Neurocir* 1984;13:1-16