

Are your MRI contrast agents cost-effective?

Learn more about generic Gadolinium-Based Contrast Agents.



**FRESENIUS
KABI**

caring for life

AJNR

Diseases of the spinal canal in children: diagnosis with noncontrast CT scans.

B J Fredericks, D W Boldt, B M Tress and E Cattapan

AJNR Am J Neuroradiol 1989, 10 (6) 1233-1238

<http://www.ajnr.org/content/10/6/1233>

This information is current as
of April 10, 2024.

Diseases of the Spinal Canal in Children: Diagnosis with Noncontrast CT Scans

B. J. Fredericks¹
D. W. Boldt¹
B. M. Tress²
E. Cattapan¹

The spinal cord and its coverings were assessed in 131 CT studies performed without intrathecal contrast material in 108 patients ages newborn to 20 years old. The spinal cord, including the conus medullaris, and the theca can be readily identified in most patients, except in the upper thoracic region. Correlation with other radiologic studies and surgery showed few false-positive and false-negative results. Of particular importance, in no patient was unnecessary surgery performed nor was necessary surgery not performed as a result of the method. The technique was a useful screening test, often sufficient alone, for the assessment of congenital disease (proved lesions included 20 tethered spinal cords, 11 congenital mass lesions, five split cords, and 11 hydromyelic cysts or syrinxes). There were nine confirmed intraspinal neoplasms. The technique was good for identifying epidural lesions; however, we recommend myelography and/or CT myelography for suspected intradural tumors because of the greater anatomic definition required. Noncontrast CT requires careful attention to technique, and may be successful only with the use of late-model, high-resolution CT units.

Noncontrast CT is a rapid, cost-effective method of assessing suspected disease in the pediatric spinal canal, at least while access to MR is still limited.

AJNR 10:1233-1238, November/December 1989

For the past 10 years the standard methods of displaying the spinal cord and subarachnoid space in infants and children have been myelography, sometimes followed by CT, or CT myelography alone. The disadvantages of these methods include the need for lumbar puncture, the potential morbidity of contrast agents, and the need for either heavy sedation or general anesthesia for many children. With the arrival at our hospital of a high-resolution CT unit (General Electric 9800B), it became evident that with careful technique the spinal cord and theca frequently could be displayed well without the use of intrathecal or IV contrast material. We report the results of our initial experience with noncontrast CT, suggest when it should be used, and describe its limitations and the technique used.

Materials and Methods

Between March 1983 and July 1986, 131 noncontrast CT studies were performed in 108 patients ranging in age from newborn to 20 years old (mean, 9 years). Nine patients were less than 1 year old, 23 were 1-5, 26 were 6-10, 36 were 11-15, and 14 were 16-20. All were referred for investigation of suspected disease within the spinal canal. All examinations preceded subarachnoid contrast studies when performed. Twenty patients had proved mass lesions. Eleven of these lesions were developmental, namely, lipoma, and included lipomatous infiltration of the spinal cord (eight), hemangiolipoma (one), dermoid (one), and enterogenous cyst (one). The other nine lesions comprised ependymoma (two), Ewing sarcoma (two), histiocytosis X (one), neuroblastoma (two), ganglioneuroma (one), and aneurysmal bone cyst (one).

Received July 8, 1988; revision requested September 8, 1988; final revision received April 18, 1989; accepted April 25, 1989.

¹Department of Radiology, Royal Children's Hospital, Melbourne, Flemington Rd., Parkville, Victoria, 3052, Australia. Address reprint requests to D. W. Boldt.

²Department of Radiology, Royal Melbourne Hospital, Melbourne, Australia.

0195-6108/89/1006-1233
© American Society of Neuroradiology

Technique

Noncontrast CT is a relatively quick technique once the child is positioned in the CT unit. To achieve good diagnostic images, the scan thickness should be 5 mm or less. Three-mm-thick scans may be required in small infants to provide greater detail. Our standard protocol is to use a 5-mm scan thickness with a 10-mm table movement. When necessary, such as for the accurate localization of the conus, contiguous scans are obtained at selected anatomic levels.

The optimum technical factors are 120 kV, 400–700 mAs, and a 4-sec scan time. The primary scan field of view is chosen to give optimum detail. The standard algorithm is used, which allows photography at bone- and soft-tissue settings without image degradation [1]. The long scan time is preferred over shorter times to reduce aliasing [1]. However, with longer scanning times, movement artifacts may be a problem and require the use of heavy sedation or anesthesia.

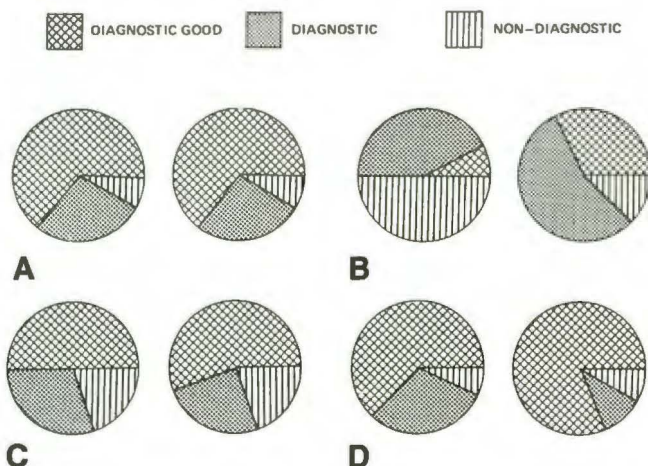


Fig. 1.—Technical adequacy of noncontrast CT in assessing spinal canal disease.

A, Cervical region ($n = 76$).

B, Six rostral thoracic segments ($n = 50$).

C, Six caudal thoracic segments ($n = 36$).

D, Lumbosacral region ($n = 60$).

Left and right circles represent reviewers 1 and 2, respectively.

The quality of the photography is important; on the GE 9800 unit the optimum technique for the spinal cord is window level of 35 and window width of 350; for bone, the window level is 35 and the window width is 3000. For the scout view the window width and level are chosen to permit clear identification of bony landmarks to which scan levels can be related.

Methods

Each study was reviewed without knowledge of the clinical diagnosis and outcome by two pediatric radiologists working together (reviewer 1) and separately by a neuroradiologist in an adult general hospital working alone (reviewer 2). The prospective interpretation of each study was also reviewed and entered in the study. (Note.—One of the pediatric observers had been involved in the reporting of some of the studies at presentation. Therefore, all prospective reports were interpreted by the second pediatric radiologist, who had no prior knowledge of the result.) The results were correlated with the findings of other imaging investigations (myelography and/or CT myelography), surgery, and pathology, or with the subsequent clinical course when there was no other corroborative evidence. MR was not available during the study.

In addition, each study was assessed for technical adequacy (Fig. 1). Four spinal regions were defined: cervical, six rostral thoracic segments, six caudal thoracic segments, and lumbosacral. A transitional zone of two vertebral segments between regions was permitted without judging that a study extended into two regions; for example, a lumbosacral study that extended up to but not above the 11th thoracic vertebral segment was judged to be a study of a single region. Each region in each study was judged to be either diagnostic good (clear definition of spinal cord, subarachnoid space, and theca on the majority of images), diagnostic (some loss of anatomic definition but nevertheless the majority of images permitted diagnosis), or nondiagnostic (unable to sufficiently define spinal cord from subarachnoid space and theca on the majority of images) (Figs. 2 and 3B). In addition to assessment by regions, the technical parameters of each study were reviewed.

Results

There was good correlation between the reviewers' assessments of the technical adequacy of the examinations,

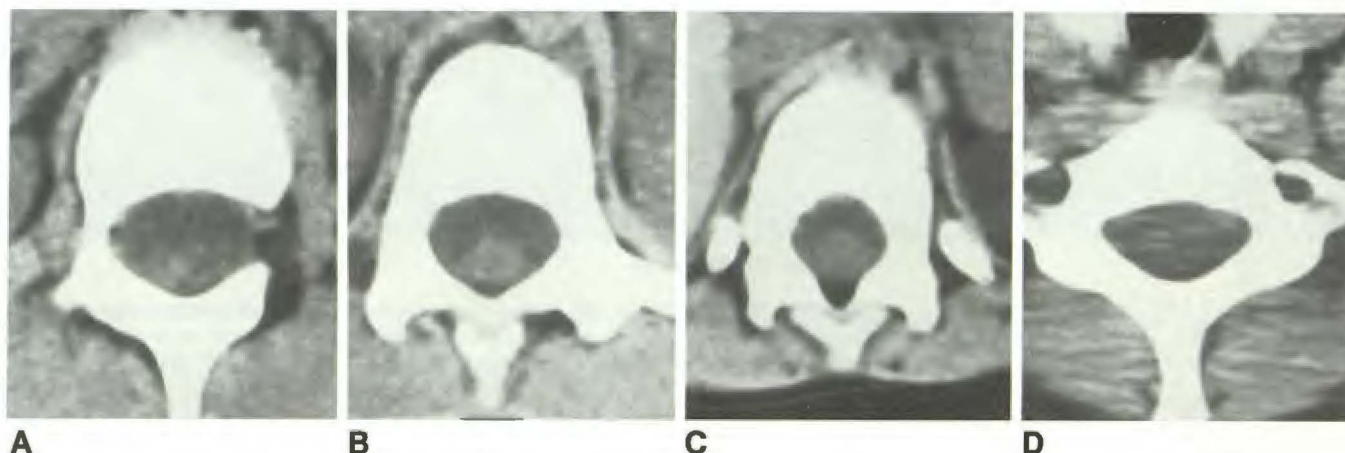


Fig. 2.—Examples of technical adequacy of noncontrast CT scans.

A and B, *Diagnostic good*. A shows normally situated conus medullaris; B shows normal lumbar expansion.

C, *Diagnostic*. Cord is visible but poorly defined.

D, *Nondiagnostic*. Cord is not visible. Note typical artifact at cervicothoracic junction.

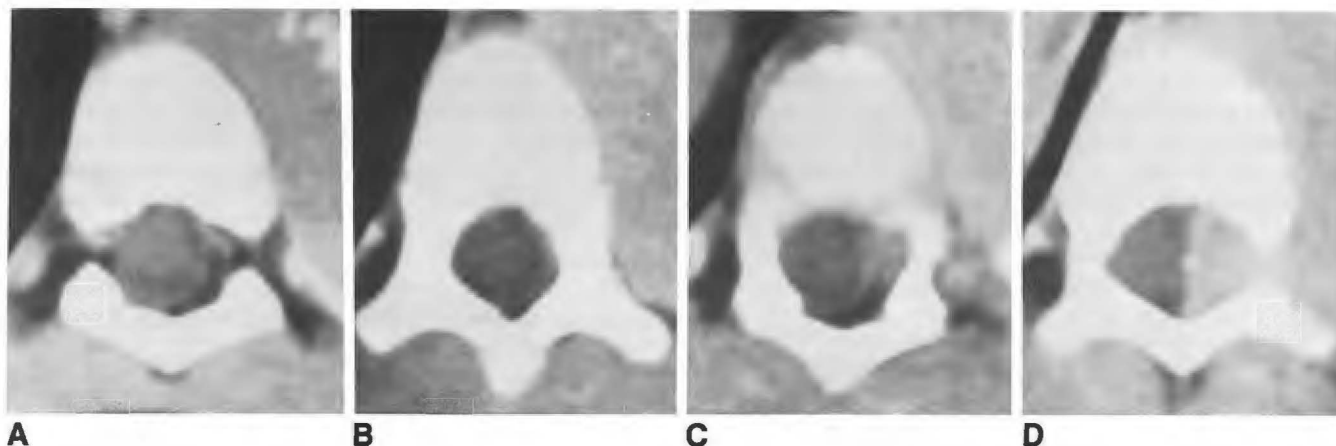


Fig. 3.—Epidural neuroblastoma.

A, Dura and contents are deviated rostral to tumor.

B, Nondiagnostic.

C and D, Tumor extends through expanded neural foramen and compresses cord.

particularly in the cervical and lumbosacral regions (Fig. 1). At other levels the external reviewer was less critical in the assessment of adequacy. The technique is less successful in the lower half of the thoracic spine and least successful in the upper half of the thoracic spine, but still yields diagnostic information in most cases. Most of the pathology in this study was in the cervical and lumbosacral regions, and the review showed very few nondiagnostic studies in these areas.

The prospective report was compared with the reviewers' retrospective diagnoses, since, when definite confirmation was available, it was shown to be valid in all but very minor details. When there was no other confirmation, the prospective report was assumed to represent the correct result, since review of clinical records never disproved this report.

Table 1 summarizes the final results and confirmation rate. Repeat examinations were excluded in order to show the true distribution of disease. Low confirmation rates do not necessarily indicate that the noncontrast CT diagnosis was disproved, but often that the clinical situation did not warrant further tests or surgery. The most common indication for noncontrast CT was suspected congenital disease (low cord, which was sometimes associated with split cord, with or without a diastematomyelic spur, and/or a congenital mass) (Figs. 4 and 5). Frequently there was more than one pathologic finding. The miscellaneous group includes lesions such as hematoma (Fig. 6), extruded disk, and arachnoiditis. Atrophy was not included in the results because it was never reported by reviewer 2 and adequate diagnostic criteria could not be defined. Presumed low cerebellar tonsils lying in the cervical canal were included in the congenital mass lesion category, and later separated to show the true prevalence of the latter.

There was good correlation between the findings of the reviewers and the prospective report for most diseases (Table 2). The only major error in the prospective reports was the failure to detect an isolated split cord without a bony spur or other associated congenital lesion. This was also missed by both retrospective reviewers. The other three prospective

TABLE 1: Final Results and Confirmation in 108 Patients Investigated for Disease of the Spinal Canal

Final Diagnosis	No. of Patients (%)	No. (%) Confirmed		
		Radiology	Pathology/Surgery	Total
Normal	43 (40)	4	0	4 (9)
Low cord	22 (20)	6	20	20 (91)
Split cord ^a	6 (6)	2	5	6 (100)
Congenital mass				
Other than tonsils	11 (10)	3	11	11 (100)
Tonsils ^b	14 (13)	7	1	7 (50)
Neoplastic mass	9 (8)	3	9	9 (100)
Syrinx or hydromyelia	13 (12)	8	10	11 (85)
Miscellaneous	5 (5)	1	1	2 (40)

^a One split cord was diagnosed on CT myelography only.

^b Upper cervical masses presumed to be low cerebellar tonsils.

errors did not affect treatment. Important errors in retrospective reports included the failure of reviewer 2 to recognize three tumors. Interpretive errors are listed. The technical standard of the misdiagnosed examinations was reviewed. All were considered at least diagnostically adequate.

Discussion

The noncontrast CT appearance of normal intraspinal soft tissues has been described [2-4]. This study shows that in children it is frequently possible to make accurate diagnoses without the use of intrathecal contrast material, particularly in cervical and lumbar regions. The higher proportion of technically poor studies in the thoracic region (Fig. 1) presumably is related to motion artifacts and to the increased and variable thickness of surrounding soft tissue and bone, particularly at the shoulder level, where artifact is a problem (Fig. 2D) [1, 4].

Noncontrast CT is particularly useful in congenital lesions, including low cords, split cords, and associated mass lesions

(Table 2). The 22 low cords were never missed in the prospective report or by the pediatric reviewers. It is essential that there be an adequate frontal scout view, extending from lower ribs to mid sacrum, to allow accurate localization of the scan level that best displays the conus. In addition, a frontal thoracic scout view, or radiograph, may be necessary to accurately identify vertebral segments when there is a marginal low conus [5]. In five of six proved cases, it was possible to identify split cords (with and without bony spurs) without the use of subarachnoid contrast material. In two additional

patients, conjoined and adherent nerve roots were falsely called split cords. However, noncontrast CT correctly recognized low cords requiring surgery in both, and, therefore, these errors neither jeopardized the surgical procedure nor the subsequent outcome. Proven adherent nerve roots probably accounted for the fact that a small lipoma was missed in one case of low cord, but this did not affect surgery or the clinical result. At this hospital, surgery for congenital lesions is now performed mostly on the basis of noncontrast CT findings alone, since in most cases the neurosurgeons do not require a detailed display of nerve roots and associated intrathecal anatomy.

Noncontrast CT also appears to be a good screening method for syrinx and hydromyelia (Fig. 4A). For these lesions, the confirmation rate was not as high as in other congenital conditions (Table 1), often owing to the lack of clinical necessity for further confirmation. Fat infiltrating a low spinal cord, confirmed by surgery, was called a syrinx in one case. Failure to locate a hydromyelic cyst by needling in another case of low cord, or to confirm the appearance on repeat noncontrast CT in others, may reflect the dynamic nature of these fluid cavities [6, 7].

The pediatric radiologists accurately detected all neoplastic and similar mass lesions prospectively and retrospectively. Two ependymomas and an epidural neuroblastoma were not

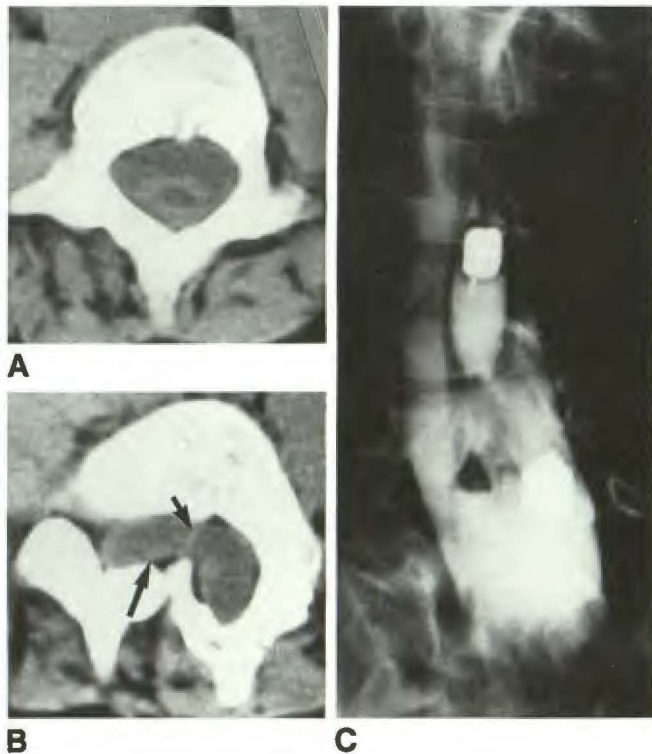


Fig. 4.—Low cord with diastematomyelia and syrinx.
A, Syrinx above split cord.
B, Split cord (long arrow points to right half) at level of spur, which is part bone and part fibrous septum (short arrow).
C, Subsequent myelogram after initial injection of contrast material into syrinx. Note hemicords on either side of triangular bony spur.

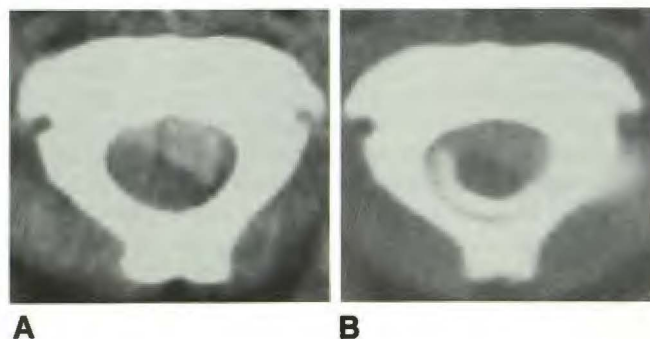


Fig. 6.—Posttrauma hematoma.
A, Noncontrast CT scan. Higher-attenuation hematoma anteriorly appears to be compressing lower-attenuation spinal cord against neural arch.
B, CT myelogram. Contrast material posterior to and to the right of spinal cord shows cord is not tightly compressed.

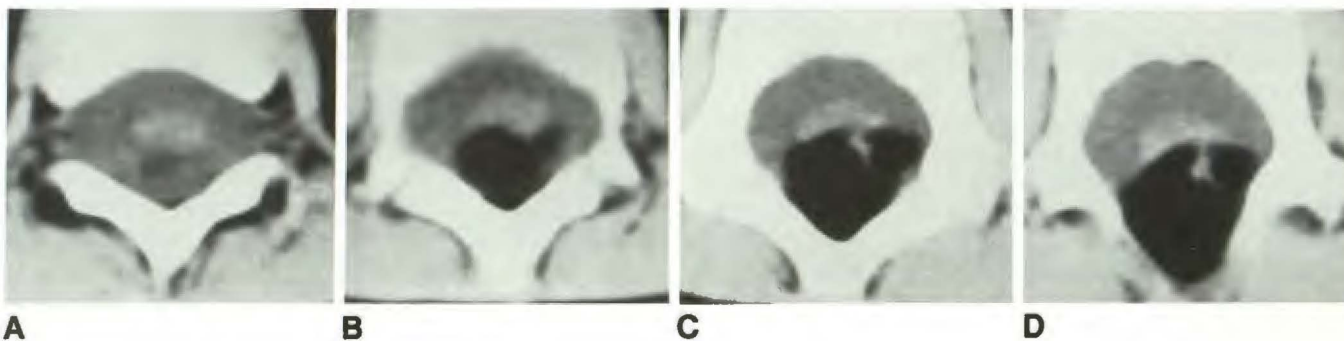


Fig. 5.—Low cord with congenital lipomatous mass.
A-D, Images from thoracolumbar junction to midlumbar spine show large fatty mass posteriorly that extends through neural arch defect caudally, with spinal cord intimately attached anteriorly.

TABLE 2: Comparison of Retrospective Review and Prospective Report in 108 Patients Investigated for Disease of the Spinal Canal

	No.						
	Normal	Low Cord	Split Cord	Congenital Mass	Neoplastic Mass	Syrinx or Hydromyelia	Miscellaneous
Total proved	43	22	6	11	9	13	5
Prospective report	44 ^a	22	5 ^a	12 ^b	9	15 (2 ^c)	5
Reviewer 1							
"True"	39	22	5	10	9	12	5
False positive							
Proved	1 ^a	0	0	1 ^b	1 ^d	1 ^c	0
Unproved	1	2 ^e	1 ^e	0	0	1	0
False negative							
Proved	0	0	1 ^a	1 ^e	0	0	0
Unproved	4	0	0	0	0	1	0
Reviewer 2							
"True"	38	20	5	11	6	13	3
False positive							
Proved	3 (1 ^a)	1	5 (3 ^e)	0	2 (1 ^d)	3 (2 ^c)	0
Unproved	0	0	0	2	0	0	4
False negative							
Proved	2	2 ^e	1 ^a	0	3	0	1
Unproved	3	0	0	0	0	0	1

Note.—Findings were considered proved or unproved on the basis of contrast radiologic or pathologic/surgical results.

^a One split cord was diagnosed on CT myelography only.

^b Adherent nerve roots misread as a small mass.

^c False-positive interpretation due to fat infiltration or cystic change in tumor.

^d Early postoperative study; repeat noncontrast CT study was normal.

^e Important associated anomalies were diagnosed.

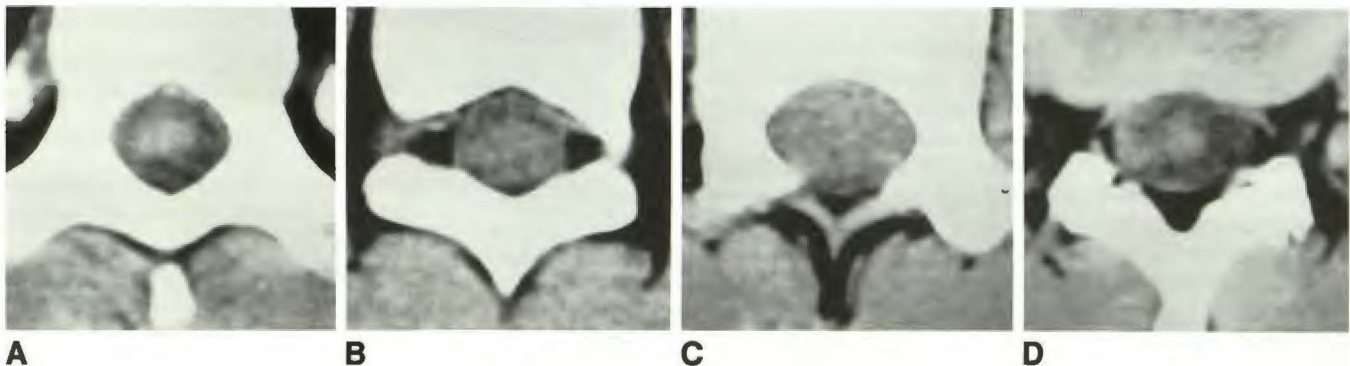


Fig. 7.—Conus ependymoma.

A, Normal cord rostrally.

B, Cord enlarged.

C, CSF cuff obliterated by expanded cord and tumor.

D, Conus below tumor.

recognized by the external reviewer. The signs of mass lesions are loss of definition, or distortion, of theca and epidural fat, and/or loss of the normal low-density CSF cuff around the spinal cord. The CSF cuff allows the surface of the spinal cord to be seen directly above and below the level of pathology (Fig. 7). The loss of the fluid cuff results in a homogeneous appearance of the intradural contents.

Epidural masses are well displayed on noncontrast CT (Fig. 3); it enables neurosurgeons at our hospital to operate successfully without further imaging investigations. However, we recognize that the anatomic definition provided by noncontrast CT is such that smaller lesions within the cord, or in an extramedullary intradural location, may not be evident, partic-

ularly in the thoracic region. Because the detection of these intradural lesions and subsequent resection of extramedullary tumors require detailed display of the spinal cord and nerve roots, a subarachnoid contrast study is always required. Therefore, to achieve economy of investigations, we recommend that patients with suspected intradural neoplasms be studied directly with myelography or CT myelography [8–11].

Early postoperative noncontrast CT is difficult to interpret because of residual hematoma and other postoperative changes obscuring the normal anatomic landmarks, and, in particular, it may be unable to exclude the presence of residual tumor. Repeat noncontrast CT, after allowing at least 4 weeks

for some resolution of postoperative changes, was found to be more definitive.

The miscellaneous group (Tables 1 and 2) included traumatic hematoma (two patients), extruded disks (two), and arachnoiditis (one). Three were unproved and the numbers were insufficient to draw any meaningful conclusions.

The management of spinal trauma requires special discussion. Noncontrast CT may be used primarily to investigate the intraspinal soft tissues when cord trauma or intraspinal hematoma is suspected, or the images obtained to assess vertebral trauma may be secondarily adjusted to display soft tissues. We recommend that in this situation, scans should be contiguous through the area of interest. An unequivocally normal noncontrast CT result would not usually require further investigation, since treatment is unlikely to be changed. However, an abnormal or technically inadequate noncontrast CT study should be followed immediately by myelography or CT myelography; our experience with two patients suggests an abnormal noncontrast CT result may be misleading. Figure 6 shows a patient who was seen after our study was completed. CT myelography altered management by showing that the noncontrast CT impression of cord compression by hematoma was erroneous; thereby, unwarranted surgery in a quadriplegic patient was avoided. Later MR confirmed an intramedullary lesion.

Diagnostic errors were made on noncontrast CT, but no adverse outcome resulted from an incorrect prospective report. In most instances the erroneous report initiated a myelogram and/or CT myelogram. The same was true for most of the errors in the retrospective reviews. We postulate that the slightly lower diagnostic success rate in the retrospective reviews compared with the prospective reports may reflect the lack of clinical information available to the reviewers; in addition, the reviewers' diagnoses were made from hard-copy images alone, whereas prospective diagnoses were almost always assisted by viewing images at varied settings on the diagnostic console.

In conclusion, this study shows that noncontrast CT is a good screening technique and often adequate alone to display congenital disease and epidural mass lesions. The surgeons at our hospital now seldom require a subarachnoid contrast study before treating these lesions. However, because of the

extra anatomic detail required for the resection of intradural extramedullary tumors, and the possibility that subtle intramedullary tumors could be missed by noncontrast CT alone, we recommend that myelography and/or CT myelography be performed in place of noncontrast CT when these lesions are clinically suspected. Whereas a normal noncontrast CT study alone is sufficient in trauma, any abnormality of the intraspinal soft tissues should be confirmed by an immediate subarachnoid contrast study. Noncontrast CT is useful in children, obviating intrathecal contrast material and the associated lumbar puncture in selected clinical situations. It is a relevant technique at a time when high-resolution CT is more widely available than MR.

ACKNOWLEDGMENT

We thank Kim Alloway for typing the manuscript.

REFERENCES

1. Joseph PM. Artifacts in CT. In: Newton TH, Potts DG, eds. *Radiology of the skull and brain*, vol 5. *Technical aspects of CT*. St. Louis: Mosby, 1981:3988-3989
2. Ethier R, King DG, Melancon D, Belanger G, Taylor S, Thompson C. Development of high resolution computed tomography of the spinal cord. *J Comput Assist Tomogr* 1979;3:433-438
3. Haughton VM, Syvertson A, Williams AL. Soft-tissue anatomy within the spinal canal as seen on computed tomography. *Radiology* 1980;134:649-655
4. Taylor AJ, Haughton VM, Doust BD. CT imaging of the thoracic spinal cord without intrathecal contrast medium. *J Comput Assist Tomogr* 1980;4:223-224
5. Fitz CR, Harwood-Nash DC. The tethered conus. *AJR* 1975;125:515-523
6. Aubin ML, Vignaud J, Jardin C, Bar D. CT in 75 clinical cases of syringomyelia. *AJNR* 1981;2:199-204
7. Pettersson H, Harwood-Nash DC. *CT and myelography of the spine and cord*. Heidelberg: Springer-Verlag, 1982:43-47
8. Resjo IM, Harwood-Nash DC, Fitz CR, Chuang SH. CT metrizamide myelography (CTMM) in intraspinal and paraspinal neoplasms in infants and children. *AJR* 1979;132:367-372
9. Raininko R, Sonninen P. CT examination of spinal tumors. *Eur J Radiol* 1985;5:52-56
10. Tadmor R, Cacayorin ED, Keiffer SA. Advantages of supplementary CT in myelography of intraspinal masses. *AJNR* 1983;4:618-621
11. Dublin AB, McGahan JP, Reid MH. The value of CT metrizamide myelography in the neuroradiological evaluation of the spine. *Radiology* 1983;146:79-86