

Are your **MRI contrast agents** cost-effective?

Learn more about generic **Gadolinium-Based Contrast Agents**.



FRESENIUS
KABI

caring for life

AJNR

CT and MR findings in patients with chordomas of the petrous apex.

R V Brown, M R Sage and B P Brophy

AJNR Am J Neuroradiol 1990, 11 (1) 121-124

<http://www.ajnr.org/content/11/1/121>

This information is current as of April 19, 2024.

CT and MR Findings in Patients with Chordomas of the Petrous Apex

Randell V. Brown¹
 Michael R. Sage¹
 Brian P. Brophy²

Chordomas are rare neoplasms arising from remnants of the embryologic notochord. Although typically midline in site, intracranial tumors may arise off the midline, and a significant proportion of these arise unilaterally in the petrous bone. Three examples of this entity are presented, all demonstrating typical radiologic features. Dendritic branches of the cranial end of the notochord ramifying in the skull base are thought to provide the embryologic basis for this tumor. The CT and MR features demonstrated are similar to those of the more common midline chordomas. CT demonstrates a well-defined extraaxial soft-tissue mass associated with foci of calcification and bone destruction and occurring at a site corresponding with the embryologic distribution of notochordal material. On MR, prolonged T1 and T2 relaxation times result in hypointensity on T1-weighted images and marked hyperintensity on T2-weighted images. Signal voids result from the foci of calcification while hemorrhage may also lead to inhomogeneity.

AJNR 11:121-124, January/February 1990

Chordomas are rare, slowly growing neoplasms arising from notochordal remnants. Approximately 35-40% of these tumors occur intracranially, accounting for less than 1% of all intracranial tumors [1]. Intracranial chordomas most frequently originate from the clivus near the sphenoccipital synchondrosis and close to the midline [2]. Occasionally, chordomas may arise unilaterally in the base of the skull [3] or, very rarely, in the paranasal sinuses [4]. We describe the imaging findings in three cases of chordoma arising primarily in the region of the petrous apex.

Case Reports

Case 1

A 46-year-old man presented after a suicide attempt in the setting of a depressive illness. He also described a recent onset of dysphagia for fluids and nasal speech. Examination revealed a weakness of the palate on the right and deviation of the protruded tongue to the right side. Indirect laryngoscopy revealed a right vocal cord palsy.

CT examination (Figs. 1A and 1B) revealed erosion of the right petrous apex and a 2-cm-diameter mass extending into the middle cranial fossa. The mass contained some foci of calcification but was otherwise nearly isodense with the adjacent temporal lobe on the postcontrast images. The clivus and dorsum sellae were intact.

MR imaging confirmed a mass at the right petrous apex that was of low signal intensity on T1-weighted images and very hyperintense on T2-weighted images (Fig. 1C). Subsequent angiography did not reveal any significant abnormality.

A right lateral craniotomy was performed and the tumor radically decompressed. Histopathology of the tumor confirmed the diagnosis of a chordoma. The patient's postoperative course was uncomplicated and he underwent a course of radiotherapy. His cranial nerve palsies resolved and he has remained asymptomatic for 7 months postoperatively.

Received March 7, 1989; revision requested April 19, 1989; revision received May 17, 1989; accepted May 31, 1989.

¹ Department of Radiology, Flinders Medical Centre, Bedford Park, South Australia, 5042. Address reprint requests to M. R. Sage.

² Department of Neurosurgery, Flinders Medical Centre, Bedford Park, South Australia, 5042.

0195-6108/90/1101-0121
 © American Society of Neuroradiology

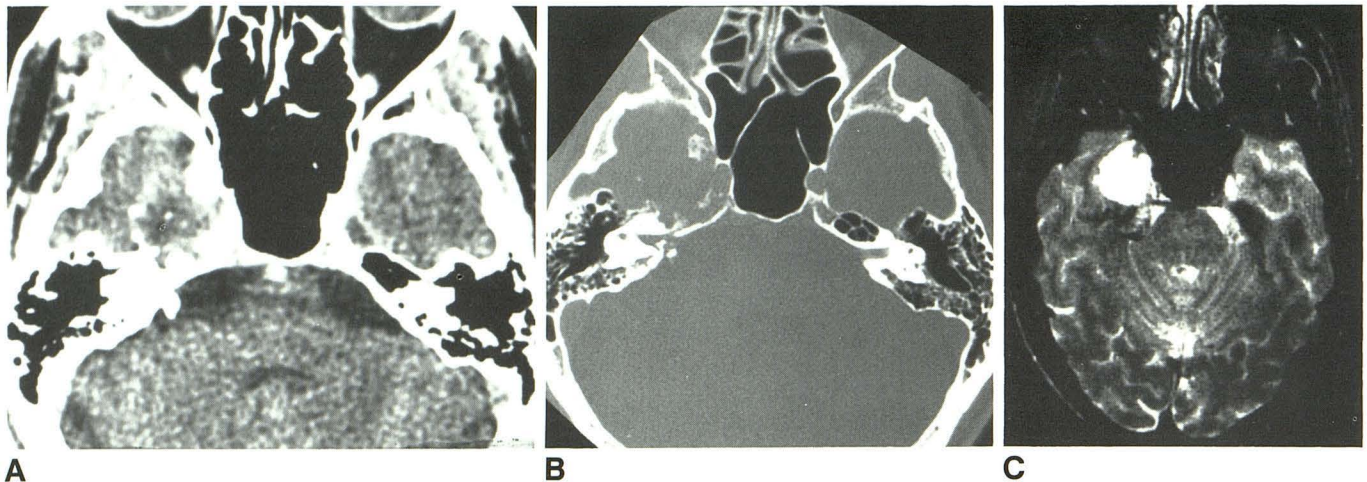


Fig. 1.—Case 1: 46-year-old man with right petrous apex chordoma.

A, CT scan of skull base after IV contrast shows a mass arising from right petrous apex and containing several foci of calcification.

B, CT scan of skull base photographed at bone windows shows bone destruction in region of right petrous apex.

C, T2-weighted axial MR image shows a high signal intensity mass arising medially in right middle cranial fossa.

Case 2

A 27-year-old woman presented with a history of several months of intermittent double vision causing a compensatory head rotation to the left. On examination there was a right sixth nerve palsy and no other neurologic signs. CT (Fig. 2A) revealed a 2.5-cm-diameter slightly hypodense lesion on postcontrast images, destroying the right petrous apex and the most lateral aspect of the right side of the clivus. Some small foci of calcification were evident in the lesion.

MR imaging (Figs. 2B and 2C) confirmed a lesion in the right petrous apex that was strongly hyperintense on T2-weighted images and hypointense on T1-weighted images. A small excrescence of the tumor was seen extending into the sphenoid sinus.

A temporal craniotomy was subsequently performed and an extensive decompression of the tumor achieved. The patient made a good postoperative recovery although the sixth nerve palsy persisted. Histopathology revealed a diagnosis of chordoma.

Case 3

A 47-year-old man presented with a 1-month history of unsteadiness of gait and a short history of slurred speech. On examination there was nystagmus on lateral gaze and an absent right corneal reflex. There was right-sided limb ataxia and moderate truncal ataxia. CT revealed extensive destruction of the right petrous apex with a large slightly hypodense nonenhancing lesion in the right cerebello-pontine angle (Fig. 3). Some small foci of calcification were evident within it. Angiography revealed only slight stretching of the anterior inferior cerebellar artery.

The patient subsequently underwent a right suboccipital craniectomy, which revealed a gelatinous and relatively avascular tumor that was confirmed histologically to be a chordoma. This was clearly seen arising from the petrous bone near the apex and extending down to the jugular bulb. Postoperatively, he developed right sixth and seventh nerve palsies. The former resolved promptly while the latter persisted.

Discussion

Chordomas are recognized as tumors arising from notochordal remnants. This relationship was initially demonstrated by Ribbert [5] in 1984 when he produced a similar lesion by

herniating a nucleus pulposus of the vertebral column in a rabbit.

These tumors may thus arise anywhere in the position of the primitive notochord, although the two ends of this structure are by far the most common sites. As the notochord is widely accepted to be a midline structure, some understanding of embryology is required to account for the occurrence of chordomas arising off the midline and, in these cases, unilaterally in the petrous apex.

In early embryonic life the notochord is a column of cells that traverses the embryo in its long axis between the neural tube and the primitive gut. During the fifth week of intrauterine life mesenchyme condenses around the cephalic end of the notochord to form the parachordal and prechordal plates of the chondrocranium [6]. These extend from the foramen magnum to the pituitary fossa, giving rise to the sphenoccipital plate, and are flanked on each side by the cartilagenous auditory capsule, which gives rise to the petrous temporal bones.

The continued multiplication of the cells of the notochord results in a number of branches that penetrate the base of the skull in different directions [7] and that, in fact, may ramify under the mucous membrane of the nasopharynx into the parapharyngeal spaces and thus into the developing paranasal sinuses. Remnants of these notochordal branches that have penetrated into the developing petrous bones presumably provide the seed from which a subsequent chordoma may grow.

Thus, although typically considered midline tumors, the embryologic basis for unilateral chordomas is understood and, in fact, they constitute a significant number of intracranial chordomas [1]. In a previous series, nearly a third of cases demonstrated unilateral bone erosion and seven of 44 cases showed petrous bone erosion without clival or sellar erosion [1].

In other respects the three cases presented here demonstrate the typical characteristics of cranial chordomas. They

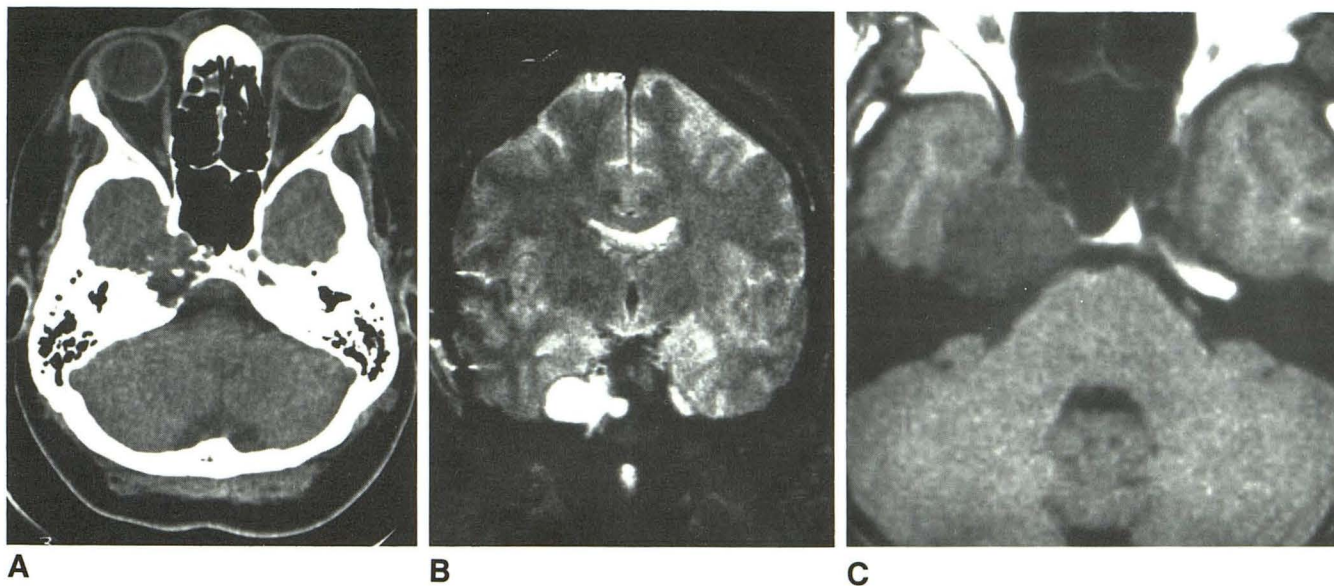


Fig. 2.—Case 2: 27-year-old woman with right sixth nerve palsy.
A, Axial plain CT scan of skull base shows destruction of right petrous apex by a soft-tissue mass.
B, Coronal T2-weighted MR image confirms presence of extraaxial mass lying medially in right middle cranial fossa with a nubbin of tissue breaking into the sphenoid sinus.
C, Axial T1-weighted MR image demonstrates a low-intensity lesion at right petrous apex.

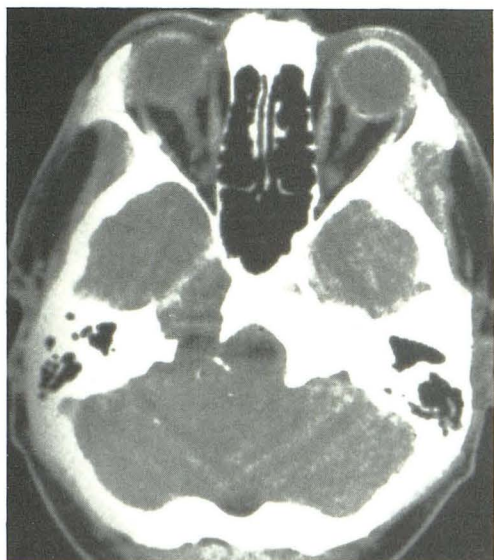

Fig. 3.—Case 3: Axial CT scan of skull base at bone window settings demonstrates a lytic lesion in right petrous apex with foci of calcification in associated soft-tissue mass extending into posterior cranial fossa.

occur over a wide age range but most commonly in the fourth or fifth decade and are approximately twice as common in males as females [8]. Macroscopically, a chordoma is usually a lobulated soft gelatinous tumor that destroys bone. It commonly calcifies and may show areas of hemorrhage and necrosis. Microscopically, there are cords of cells that have a syncytial appearance. Some cells may have a large vacuolated cytoplasm and are called physaliphorous cells. There is usually extensive stroma containing mainly mucin. The intra-

cranial chordoma is slowly growing and usually kills by local effects, although approximately 10% of cases have blood-borne metastases to liver and lungs [9, 10].

The typical CT appearance [2] of an intracranial chordoma as demonstrated by the three cases in this report is of a well-defined extraaxial soft-tissue mass associated with bone destruction and occurring at a site, as outlined earlier, corresponding with the embryologic distribution of notochordal material. There are typically foci of calcification within the tumor, which were evident in all three cases in this report, but were presented in only 47% of the series reported by Meyer et al. [2]. Some of this calcification may reflect the presence of sequestra from the destroyed bone into which the tumor is eroding. The bulk of the tumor is usually of increased density, relative to the adjacent neural axis [11], but significant areas of low attenuation are a common feature on CT and probably represent the myxoid and gelatinous material found on gross pathologic examination [2]. Comparable contrast scans were not available in the three cases in this report, but other reports indicate that at least some contrast enhancement occurs in nearly all cases [2, 11].

Two of our cases also demonstrated the MR features of intracranial chordomas. There is usually a well-defined extraaxial tumor, the bulk of which typically has prolonged T1 and T2 relaxation times [11, 12]. The marked hyperintensity of the tumor on the T2-weighted images in our series enabled easy demarcation from the adjacent neural axis. This was further facilitated by the multiplanar facility of the MR scanner. Major vessels, in particular the internal carotid artery and jugular bulb, could be seen as flow voids and the relationship of the tumor to these vessels thus assessed. Reports indicate that in approximately 30% of cases foci of calcification may be seen in the tumor as signal voids [11]. Inhomogeneity

within the tumor, although not demonstrated in our series, may also be due to areas of hemorrhage with a resultant shortening of T1 relaxation time [11].

In addition to chordoma, the differential diagnosis of a petrous apex tumor includes metastasis, epidermoid meningioma, glomus jugulare tumor chondrosarcoma, and schwannoma. Assessment of all the radiologic features on both CT and MR will enable this differential diagnosis to be narrowed, but it is doubtful that the information obtained will ever preclude the necessity of surgical biopsy.

REFERENCES

1. Kendall BE, Lee BCP. Cranial chordomas. *Br J Radiol* **1977**;50:687-698
2. Meyer J, Oot RF, Lindfors K. CT appearance of clival chordomas. *J Comput Assist Tomogr* **1986**;10,1:34-38
3. Lipper MH. Chordoma of the petrous bone (Abstr). *AJNR* **1988**;9:1020
4. Shugar JMA, Som PM, Kirespi YP, Arnold LM, Som ML. Primary chordoma of the maxillary sinus. *Laryngoscope* **1980**;90:1825-1835
5. Ribbert H. Über die Eochondrosis physalifora sphenoccipitalis. *Zentralbl Allg Pathol* **1894**;5:457-461
6. Frazer JE. The skull: general account. In: Breathnach AS, ed. *Frazer's anatomy of the human skeleton*, 6th ed. London: Churchill, **1965**:172-174
7. Omerod R. A case of chordoma presenting in the nasopharynx. *J Laryngol Otol* **1960**;74:245-254
8. Larson TC, Houser OW, Laws ER. Imaging of cranial chordomas. *Mayo Clin Proc* **1987**;62:886-893
9. Dahlin DC, Unni KK. *Bone tumors*, 4th ed. Springfield, IL: Thomas, **1986**
10. Sassin JF, Chutorian AM. Intracranial chordoma in children. *Arch Neurol* **1967**;17:89-93
11. Oot RF, Melville GE, New PFJ, et al. The role of MR and CT in evaluating clival chordomas and chondrosarcomas. *AJNR* **1988**;9:715-723
12. Sze G, Uichanco LS, Brant-Zawadzki M, et al. Chordomas: MR imaging. *Radiology* **1988**;166:187-191