

Are your **MRI contrast agents** cost-effective?

Learn more about generic **Gadolinium-Based Contrast Agents**.



FRESENIUS
KABI

caring for life

AJNR

**Cerebral necrosis simulating an
intraparenchymal tumor.**

D R Nelson, W T Yuh, B C Wen, T J Ryals and S H Cornell

AJNR Am J Neuroradiol 1990, 11 (1) 211-212

<http://www.ajnr.org/content/11/1/211.citation>

This information is current as
of April 18, 2024.

Cerebral Necrosis Simulating an Intraparenchymal Tumor

Cerebral necrosis after radiation therapy of extracranial neoplasms is an infrequent but well-documented complication [1-5]. CT and MR findings associated with changes caused by radiation therapy have been reported; however, differentiating changes caused by irradiation from postoperative changes and recurrent tumor may not always be possible because the CT and MR findings are nonspecific [6-8]. We report CT and MR (with Gd-DTPA) findings that mimicked those associated with recurrent tumor in a patient who had received radiation for an extracranial neoplasm.

Case Report

Left maxillary squamous cell carcinoma was diagnosed in a 46-year old woman. Preoperative MR imaging showed no evidence of intracranial extension. The patient had maxillary and orbital exenteration followed by postoperative irradiation (total dose, 6000 cGy in 6 weeks). A year later she had left retroorbital pain and sudden onset of left partial complex seizure. Contrast-enhanced CT showed mass effect, edema, and ill-defined enhancement of the left temporal lobe (Fig. 1). MR imaging showed mass effect of the left temporal lobe and abnormal signal in the white matter, extending from the temporal lobe to the parietal lobe. After IV administration of Gd-DTPA, a rounded enhancing mass was seen in the anterior left temporal lobe, with adjacent meningeal and dural enhancement near the previous surgical site. This was thought to indicate intracranial extension of tumor. The patient had a left temporal lobectomy for possible intracranial involvement of recurrent tumor. The findings of a pathologic examination were radiation necrosis without evidence of tumor.

Discussion

The normal brain appears to tolerate doses of radiation less than 1700 rets, but doses more than 1760 rets (approximately 6000 cGy over 6 weeks) may result in cerebral radiation necrosis [3, 4]. Onset

of signs and symptoms 3 months to 19 years after treatment has been reported [4]. These include seizures, headache, personality changes, and focal neurologic deficits.

Recent reports of MR findings associated with radiation therapy to the brain include cerebral atrophy; asymmetric white-matter edema in the periventricular areas; diffuse white-matter signal; and focal areas of white-matter edema, occasionally with gray-matter involvement [1, 2, 9]. CT findings include atrophy, areas of decreased attenuation in the white matter, and focal enhancing lesions. The MR and CT findings are nonspecific with regard to differentiating among recurrent tumor, primary brain tumor, and focal radiation necrosis.

The pathologic findings associated with delayed changes after irradiation include delayed capillary endothelial damage and thickening, hyalinization, and necrosis of the arteriolar walls, which may lead to thrombosis and infarction [10]. Formation of new vessels with thin-walled channels also has been reported [4]. Parenchymal changes more commonly affect the white matter, as seen in our case. Vacuolization, coagulation necrosis, and astrogliosis surrounding the area of necrosis and patchy demyelination without marked hyalinization of the blood vessels also can occur. However, the most necrotic and cavitated areas usually are associated with the most prominent vascular damage.

Gd-DTPA enhancement in tumor is thought to be associated with breakdown of the blood-brain barrier. In cerebral necrosis, delayed capillary endothelial damage and hyalinization and necrosis of the arteriolar wall result in breakdown of the barrier. It is not surprising that Gd-DTPA may not be helpful in differentiating delayed radiation necrosis from recurrent or primary brain tumors. Therefore, radiation-induced changes should be considered a possible cause in patients who have vasogenic edema and a mass that shows enhancement after administration of Gd-DTPA. In our case, the necrotic mass had only a mildly increased signal compared with the signal of other areas on T2-weighted images. Relatively low amounts of proteinaceous material within the necrotic mass may be the reason for this relatively low signal. Enhancement in the area of radiation necrosis was better with MR than with CT. This probably occurs because contrast-

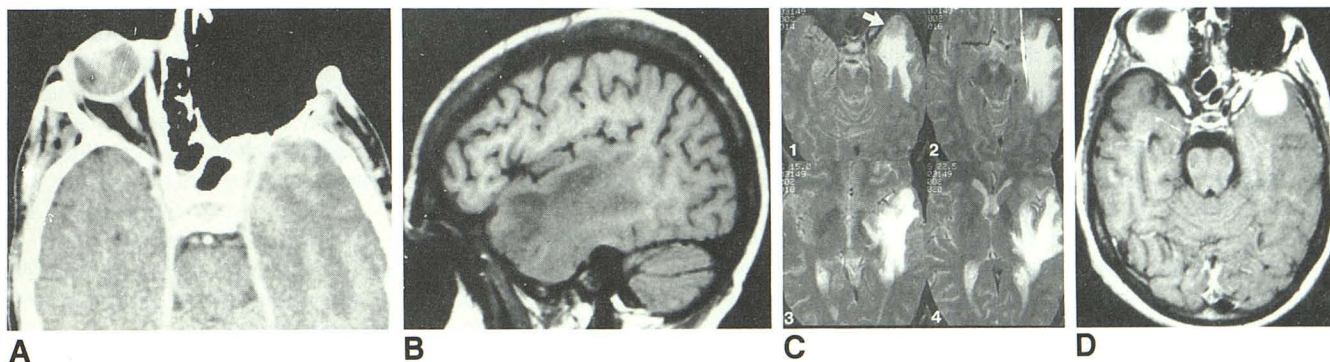


Fig. 1.—Cerebral necrosis simulating an intraparenchymal tumor.

- A, Contrast-enhanced CT scan shows mass effect, edema, and ill-defined enhancement of left temporal lobe.
 B, Parasagittal T1-weighted image (SE 500/20) shows mass effect of left temporal lobe with abnormal signal.
 C, Axial T2-weighted images (SE 2000/90), caudal to cranial (1-4), show abnormal high signal in white matter of temporal and parietal lobes. Note rounded mass with moderate high signal (arrow) near temporal tip.
 D, Axial T1-weighted image (SE 500/20) with Gd-DTPA proved a rounded enhancing mass and adjacent dural enhancement near previous surgical site, which was proved to be radiation necrosis only by surgery.

enhanced MR is better than contrast-enhanced CT in detecting the breakdown of the blood-brain barrier, as is seen frequently in tumor.

David R. Nelson
William T. C. Yuh
B-Chen Wen
Tony J. Ryals
Steven H. Cornell

*University of Iowa Hospitals and Clinics
Iowa City, IA 52242*

REFERENCES

1. Curnes JT, Laster DW, Ball MR, Moody DM, Witcofski RL. MRI of radiation injury to the brain. *AJNR* **1986**;7:389-394
2. Doms GC, Hecht S, Brant-Zawadzki M, Berthiaume Y, Norman D, Newton TH. Brain radiation lesions: MR imaging. *Radiology* **1986**;158:149-155
3. Dwyer J, Gilbert JJ, Heeneman H. Lethal delayed radiation necrosis of the brain as a complication of radiotherapy for cancer in the head and neck. *J Otolaryngol* **1985**;14:301-304
4. Rottenberg DA, Chernik NL, Deck MDF, Ellis F, Posner JB. Cerebral necrosis following radiotherapy of extracranial neoplasms. *Ann Neurol* **1977**;1:339-357
5. Araoz C, Weems AM. Posttherapeutic cerebral radionecrosis: a complication of head and neck tumor therapy. *South Med J* **1981**;74:1485-1488
6. Graif M, Bydder GM, Steiner RE, et al. Contrast-enhanced MR imaging of malignant brain tumors. *AJNR* **1985**;6:855-862
7. Runge VM, Clanton JA, Price AC, et al. The use of Gd-DTPA as a perfusion agent and marker of blood-brain barrier disruption. *Magn Reson Imaging* **1985**;3:43-55
8. Healy ME, Hesselink JR, Press GA, Middleton MS. Increased detection of intracranial metastases with intravenous Gd-DTPA. *Radiology* **1987**;165:619-624
9. Tsuruda JS, Kortman KE, Bradley WG, Wheeler DC, Van Dalsem WI, Bradley TP. Radiation effects on cerebral white matter: MR evaluation. *AJNR* **1987**;8:431-437
10. Cavenis WF. Experimental observations: delayed necrosis in normal monkey brain. In: Gilbert HA, Korgan AR, eds. *Radiation damage to the nervous system*. New York: Raven, **1980**:1-38