

## Herpes Trigeminal Neuritis and Rhombencephalitis on Gd-DTPA-Enhanced MR Imaging

Trigeminal neuritis usually is caused by an inflammatory reaction to herpes simplex virus, which often resides within the gasserian ganglion of the trigeminal nerve. Transaxonal movement of the virus between the ganglion and peripheral nerves within the oral cavity has been documented [1, 2]. The virus can be isolated from the painful aphthous ulcers within the oral cavity and the typical cold sore lesion often seen at the border of the lips. Herpes simplex virus type 1 occasionally involves the brain by retrograde spread from the gasserian ganglion along the preganglionic segment of the fifth nerve to the brainstem. This has been referred to as rhombencephalitis [3, 4]. We describe the MR findings in a patient with brainstem encephalitis and the typical clinical features of herpes simplex trigeminal neuritis in whom enhancing trigeminal nerve lesions returned to normal appearance 6 weeks after initial study without any form of treatment.

### Case Report

A 33-year-old previously healthy man had an acute onset of left-sided facial numbness. Complete anesthesia of the face in the distribution of the fifth cranial nerve was present, accompanied by typical herpes simplex ulcers of the oral cavity and circumoral region. The rest of the physical examination and chest radiograph showed no other abnormalities. MR of the brain performed 1 week after onset of the symptoms showed an ill-defined area of high signal intensity involving the left pons and middle cerebellar peduncle without significant mass effect on a long TR/TE sequence (Fig. 1). After administration of Gd-DTPA, the preganglionic (cisternal) portion of the left fifth nerve enhanced intensely on a short TR/TE sequence. Analysis of CSF showed no abnormalities, and culture of the CSF was negative

for bacteria, including mycobacteria. The patient was not treated and gradually improved, with complete resolution of symptoms 6 weeks after the onset of the process. Follow-up MR performed 7 weeks after the onset showed marked resolution of the abnormal high signal intensity in the pons and left middle cerebellar peduncle on the long TR/TE sequence. After administration of Gd-DTPA, T1-weighted images showed a normal, nonenhancing left fifth cranial nerve. During the 7 weeks, the patient had continuous episodes of oral ulcers around the left side of the lip. However, 9 weeks after the initial onset, the oral ulcers and facial numbness had resolved completely.

### Discussion

Viral neuritis due to herpes simplex type I has been well documented [1, 5, 6]. The virus lies dormant within the gasserian ganglion of the trigeminal nerve. Antegrade spread of the virus, via the distal branches of the sensory division of the trigeminal nerve, results in painful aphthous ulcers of the oral mucosa. Retrograde spread into the brainstem is rare. This has been referred to as rhombencephalitis. In our case, encephalitis of the brainstem localized at the root entry zone at the pontomedullary junction, as presumed from the MR features of transient increased signal on the T2-weighted sequence and enhancement of the preganglionic segment of the fifth cranial nerve. Autopsy specimens of this entity have been described [3, 4]. The histologic changes in one patient who died at the height of his disability were remarkable for their paucity. In the cerebral hemisphere, frontal lobe arterioles showed lymphocytic perivascular cuffing. In the brainstem, no neuronal death was apparent, but edema with swelling and thinning of astrocytic nuclei was observed.

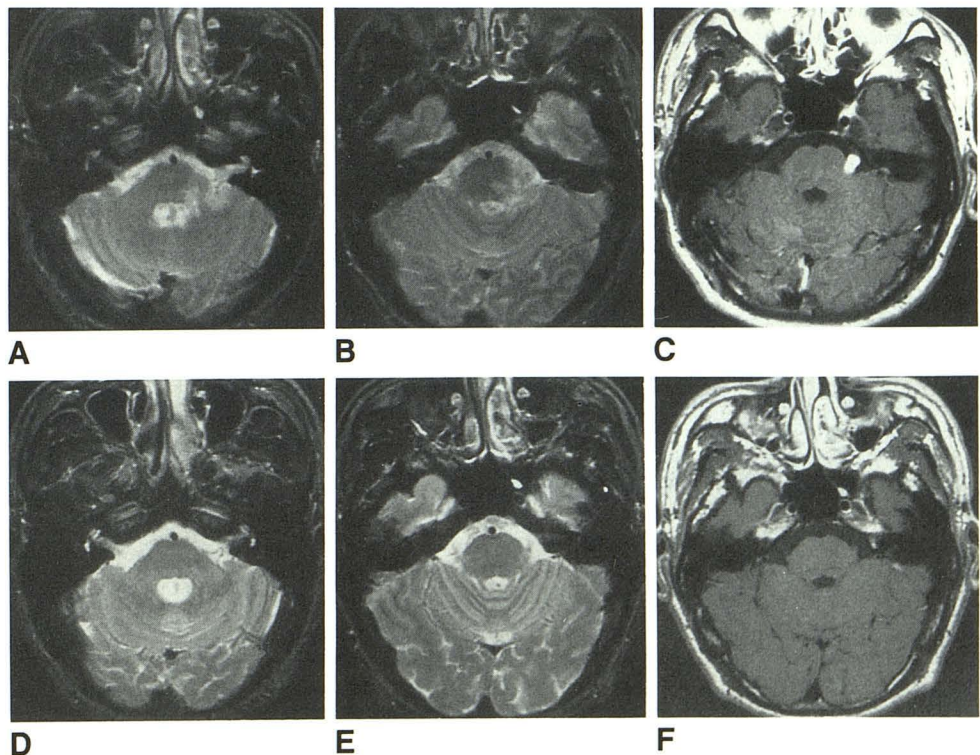
Fig. 1.—Herpes simplex trigeminal neuritis and rhombencephalitis.

A and B, Axial T2-weighted (2000/80) MR images obtained at onset of trigeminal neuritis show an ill-defined area of high signal intensity involving left middle cerebellar peduncle and pons without significant mass effect.

C, Axial Gd-DTPA-enhanced T1-weighted (600/20) MR images show enhancement of cisternal portion (preganglionic segment) of left fifth cranial nerve.

D and E, Axial T2-weighted (2000/80) MR images obtained 6 weeks after A and B when patient's symptoms had resolved completely show marked resolution of abnormal signal in middle cerebellar peduncle and left pons.

F, Axial Gd-DTPA-enhanced T1-weighted (600/20) MR images obtained at same time as D and E show no enhancement of left fifth nerve.



This case is similar to those we have seen of retrograde spread of neoplasm from the upper aerodigestive tract tumors. The differentiation of rhombencephalitis from neoplastic involvement of the fifth cranial nerve is based primarily on the clinical history, the absence of a neoplasm in the head and neck, and resolution over a short time. Our patient had trigeminal neuropathy that resolved within 2 months. Follow-up MR performed within 2 months of the clinical onset showed resolution of cranial nerve enhancement and the high signal intensity in the pons that would be distinctly uncommon with perineural tumor.

Our patient's MR images were unusual because they showed the reversible edematous change in the pons associated with herpes simplex encephalitis. We think this is the first case of viral rhombencephalitis detected by MR. Gd-DTPA-enhanced MR also showed a reversible change in the inflamed cranial nerve. Enhancement most likely is due to disruption of the blood-peripheral nerve barrier. Trypan blue, a marker of the blood-brain barrier, does not stain the peripheral cranial nerves, indicating the presence of a blood-peripheral nerve barrier. This agent does not stain the perineural and epineural tissues that will enhance after administration of Gd-DTPA [7]. We recently have seen several examples of enhancement of the intratemporal facial nerve in 12 patients with Bell palsy, as well as undocumented enhancement of the eighth cranial nerve in one patient with acute vestibular symptoms and presumed viral labyrinthitis. In the last patient, the vestibule and cochlea also enhanced with Gd-DTPA. The

present case suggests a role for gadolinium-enhanced MR in the detection and follow-up of inflammatory cranial neuropathy.

Robert D. Tien

University of California, San Diego, Medical Center  
San Diego, CA 92103

William P. Dillon

University of California, San Francisco, Medical Center  
San Francisco, CA 94143

#### REFERENCES

1. Croen KD, Ostrove JM, Dragovic LJ, Smialek JE, Straus SE. Latent herpes simplex virus in human trigeminal ganglia. *N Engl J Med* **1987**;317:1427-1432
2. Vafai A, Murray RS, Wellish M, Devlin M, Gilden DH. Expression of varicella-zoster virus and herpes simplex virus in normal human trigeminal ganglia. *Proc Natl Acad Sci USA* **1988**;85:2362-2366
3. Bickerstaff ER, Cloake PCP. Mesencephalitis and rhombencephalitis. *Br Med J* **1951**;2:77-81
4. Bickerstaff ER. Brain stem encephalitis. *Br Med J* **1957**;1:1384-1387
5. Adous KK, Bell DN, Hilsinger RL. Herpes simplex virus in idiopathic facial paralysis (Bell's palsy). *JAMA* **1975**;233:527-530
6. Vahline A, Estrom S, Arstila P, et al. Bell's palsy and herpes simplex virus. *Arch Otolaryngol* **1981**;107:79-81
7. Bradbury M. *The concept of the blood-brain barrier*. New York: Wiley & Sons, **1979**:122-137