

Are your **MRI contrast agents** cost-effective?

Learn more about generic **Gadolinium-Based Contrast Agents**.



FRESENIUS
KABI

caring for life

AJNR

Recurrent medulloblastoma: frequency of tumor enhancement on Gd-DTPA MR imaging.

N Rollins, D Mendelsohn, A Mulne, R Barton, J Diehl, N Reyes and F Sklar

AJNR Am J Neuroradiol 1990, 11 (3) 583-587

<http://www.ajnr.org/content/11/3/583>

This information is current as of April 18, 2024.

Recurrent Medulloblastoma: Frequency of Tumor Enhancement on Gd-DTPA MR Imaging

N. Rollins¹
D. Mendelsohn²
A. Mulne³
R. Barton^{1,4}
J. Diehl¹
N. Reyes³
F. Sklar⁵

Thirty-two children with medulloblastoma were evaluated postoperatively with conventional and gadolinium-enhanced MR imaging. Eleven patients had abnormal cranial MR studies; nine of these had recurrent tumor. In six patients recurrent tumor enhanced with Gd, while in the other three patients recurrent tumor did not enhance. The remaining two patients had areas of abnormal Gd enhancement that were caused by radiation-induced breakdown of the blood-brain barrier rather than by recurrent tumor.

This study shows that not all recurrent medulloblastoma enhances and that the absence of Gd enhancement does not necessarily indicate the absence of recurrent tumor.

AJNR 11:583-587, May/June 1990; *AJR* 155: July 1990

Initial reports describing the use of MR imaging in children with brain tumors have suggested that the use of gadolinium (Gd) improved the accuracy of MR in the diagnosis of recurrent or residual tumor [1, 2]. We undertook a study with Gd-enhanced MR imaging in children with recurrent medulloblastoma to examine the enhancement pattern of this tumor and to determine if the use of Gd would have a significant effect on MR results in this clinical setting.

Materials and Methods

Between July 1988 and June 1989 we examined 32 children, 18 months to 16 years old, who had been treated for medulloblastoma. All tumors were initially located in the fourth ventricle. All patients had undergone previous surgical resection followed by radiotherapy and/or chemotherapy; 28 patients were undergoing routine follow-up examinations and four patients had progressive neurologic complaints that suggested tumor recurrence.

MR was performed on a 0.35-T superconducting magnet (Diasonics MT/S, Milpitas, CA). Precontrast studies included T1-weighted spin-echo images, 500/30/2 (TR/TE/excitations), in the sagittal and axial planes and T2-weighted images (2500/40,80/2) in the axial and/or coronal planes with a pixel size of 0.95 mm and an image matrix of 256 × 256. Informed consent for the use of Gd was obtained under the guidelines of the Institutional Review Board of the University of Texas Southwestern Medical Center. Following slow IV administration of Gd-DTPA (Berlex Laboratories, Cedar Knolls, NJ) in a dose of 0.1 mm/kg body weight, T1-weighted sagittal, axial, and/or coronal images were acquired.

Twenty-seven patients also had head CT scans within 72 hr of MR imaging. The usual CT examination consisted of 10-mm nonenhanced axial images. After bolus administration of iodinated contrast material in a dose of 2 ml/kg body weight, 5-mm contiguous axial sections were taken.

Results

Eleven of the 32 patients evaluated had abnormal cranial MR studies (Table 1). Nine patients had recurrent medulloblastoma; of these, six recurrent tumors

Received August 18, 1989; revision requested October 11, 1989; revision received November 1, 1989; accepted November 9, 1989.

¹ Department of Radiology, Children's Medical Center, 1935 Motor St., Dallas, TX 75235. Address reprint requests to N. Rollins.

² NMR Imaging Center, University of Texas Southwestern Medical Center, Dallas, TX 75215.

³ Department of Pediatrics, University of Texas Southwestern Medical Center, Dallas, TX 75215.

⁴ Present address: Department of Radiology, University of Alabama, Birmingham, AL 35233.

⁵ Neurosurgeons for Children, Dallas, TX 75225.

0195-6108/90/1103-0583

© American Society of Neuroradiology

TABLE 1: Recurrent Medulloblastoma: Patterns of Enhancement

Case No.	Site of Recurrence	Enhancement on Gd-Enhanced MR Imaging	Enhancement on CT	Comment
1	4th ventricle	No	No	Routine follow-up; on chemotherapy; biopsy proved
2	Right frontal lobe	No	No	Routine follow-up; off chemotherapy; biopsy proved
3	4th and lateral ventricles	No	No	Routine follow-up; on chemotherapy
4	4th, 3rd, and lateral ventricles	Moderate enhancement in 4th ventricle, nonenhancing tumor in lateral and 3rd ventricles	No	Routine follow-up; on chemotherapy
5	4th ventricle and leptomeninges	Yes	N/A	Symptomatic recurrence; off chemotherapy
6	4th ventricle and leptomeninges	Yes	Yes	Tumor progression; on chemotherapy; positive CSF cytology
7	4th ventricle and leptomeninges	Yes	Yes	Tumor progression; on chemotherapy; positive myelogram
8	Suprasellar cistern	Yes	No	Routine follow-up; chemotherapy; positive myelogram
9	Right frontal horn	Yes	No	Biopsy proved
10	Abnormal enhancement in occipital white matter	Yes	N/A	Resolved 3 months later without therapy
11	Abnormal enhancement in occipital white matter	Yes	Minimal	Radiation necrosis

Note.—N/A = not available.

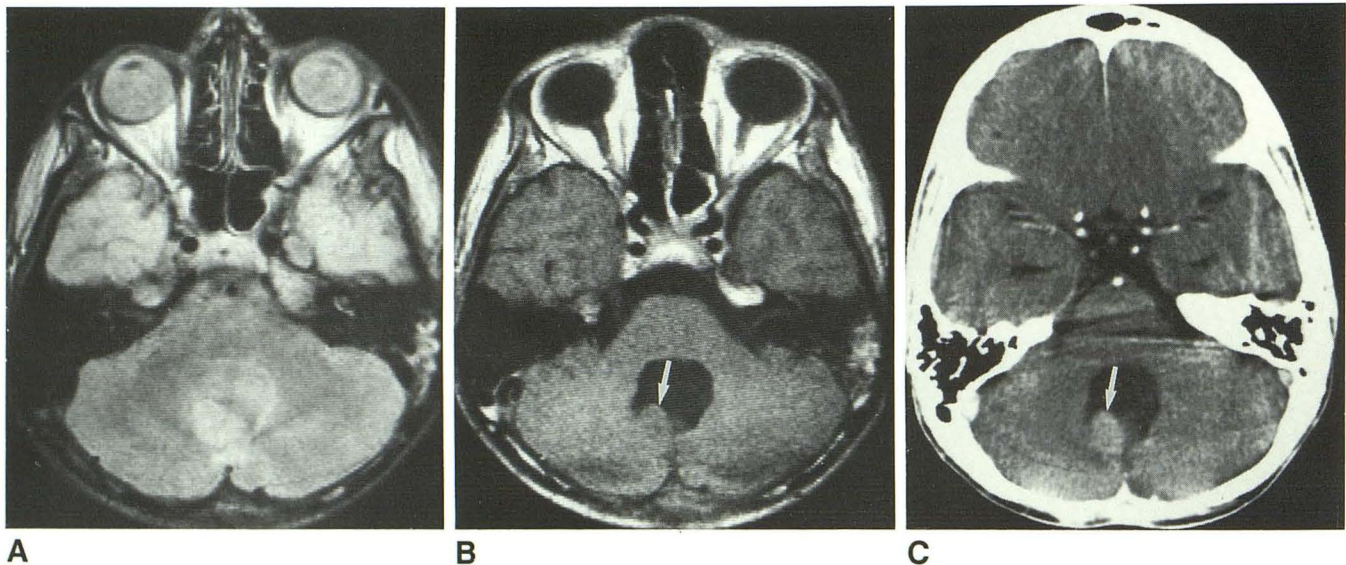


Fig. 1.—Case 1.

A, Spin-density MR image (2500/40) shows nodule projecting into fourth ventricle, which had shown no change over 2 years. Biopsy-proved recurrence. B and C, The nodule (arrow) failed to enhance with either Gd-enhanced MR (B) or CT (C).

enhanced and three showed no enhancement with Gd. Two patients had areas of abnormal Gd enhancement that subsequently resolved and were attributed to radiation-induced breakdown of the blood-brain barrier. There were no cases in which tumor enhanced by CT and not with Gd-enhanced imaging. Five of the six patients with enhancing tumors were receiving chemotherapy at the time of the examination. Two of the three patients with nonenhancing recurrent medullo-

blastoma on Gd-enhanced MR imaging were on chemotherapy. No patients were receiving exogenous steroids.

In case 1, recurrent tumor in the posterior fossa had been present unchanged for the preceding two years. No enhancement occurred with Gd-enhanced MR imaging or CT. The T2-weighted images were most suggestive of recurrent medulloblastoma (Fig. 1). Recurrent medulloblastoma in the right frontal horn in case 2 had shown slow growth over a 3-year

interval, failed to enhance with either CT or MR imaging, and was best demonstrated with T2-weighted images (Fig. 2).

In case 3 (Fig. 3) there was subtle irregularity of the ependymal surface of the lateral ventricles, which could be appreciated both with CT and Gd-enhanced MR imaging. The tumor nodules failed to enhance with either technique and the diagnosis of tumor recurrence was best made with the T2-weighted images. Within a given patient, some tumor nodules enhanced and others did not, as illustrated in case 4 (Fig. 4).

Case 6 (Fig. 5A) demonstrates typical beam-hardening and metallic artifact in the posterior fossa on CT, exacerbated by the radioactive seeds that had been surgically implanted as treatment for recurrent fourth ventricular medulloblastoma. The lack of beam-hardening and metallic artifact with MR and the intense Gd enhancement demonstrated by this recurrent tumor made Gd-enhanced MR imaging more sensitive than CT (Fig. 5B). In addition, the sagittal images allowed graphic depiction of tumor within the suprasellar cistern and along the

leptomeninges of the anterior interhemispheric region (Fig. 5C).

Two patients (cases 10 and 11) had abnormal enhancement in the occipital white matter that was presumed to represent radiation-induced disruption of the blood-brain barrier. Radiation-induced necrosis demonstrated more enhancement with Gd than it did with contrast-enhanced CT (Fig. 6).

Discussion

There are no large series describing the enhancement pattern or clinical utility of Gd-enhanced MR imaging in children with recurrent medulloblastoma. Powers et al. [2] described two cases of medulloblastoma, both of which showed intense Gd enhancement, but commented that although the use of Gd allowed identification of additional lesions, lesions could apparently be identified in the nonenhanced studies. Bird et al. [1] described two patients with medulloblastoma

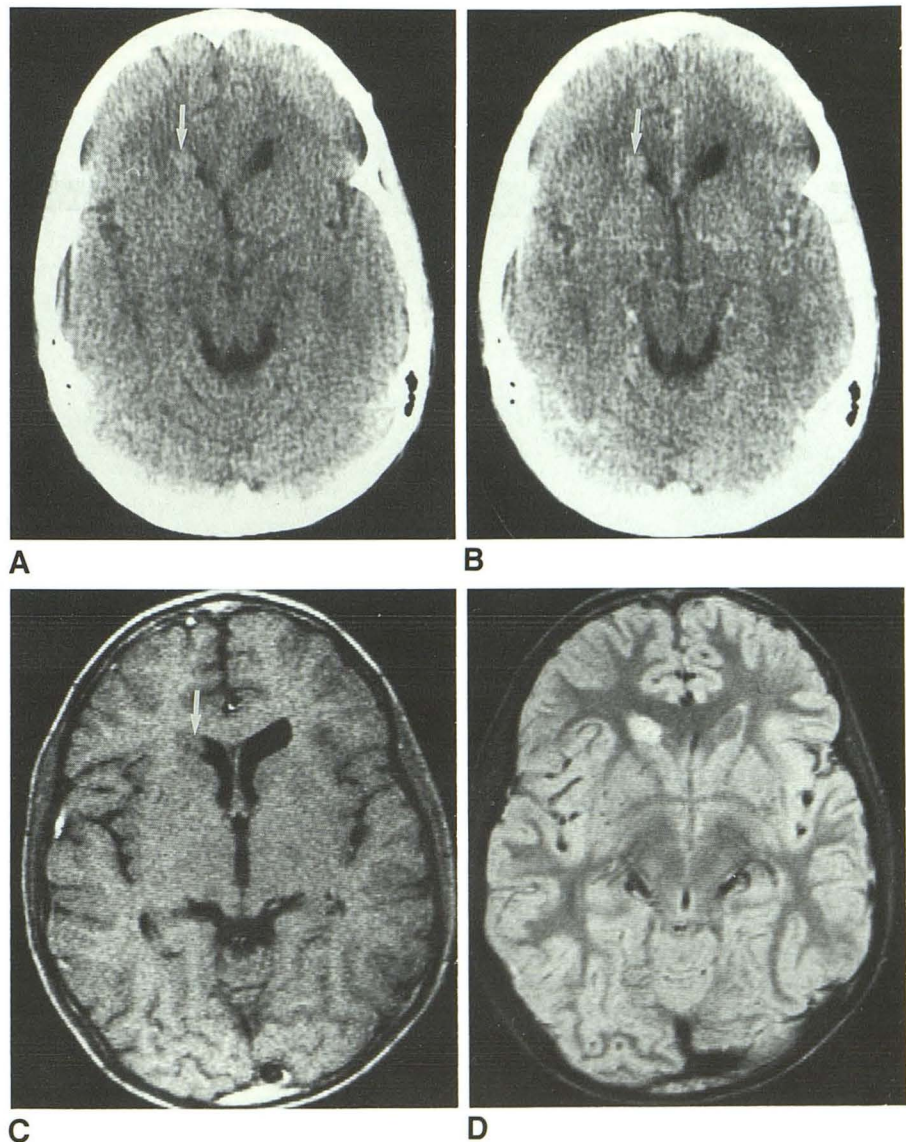


Fig. 2.—Case 2.
 A, Nonenhanced CT scan shows slightly hyperdense nodule (arrow).
 B, Contrast-enhanced CT scan shows no enhancement.
 C, The nodule (arrow) did not enhance with Gd-enhanced MR.
 D, Discrete hyperintense nodule was seen best on spin-density MR image (2500/40). Biopsy proved recurrence.

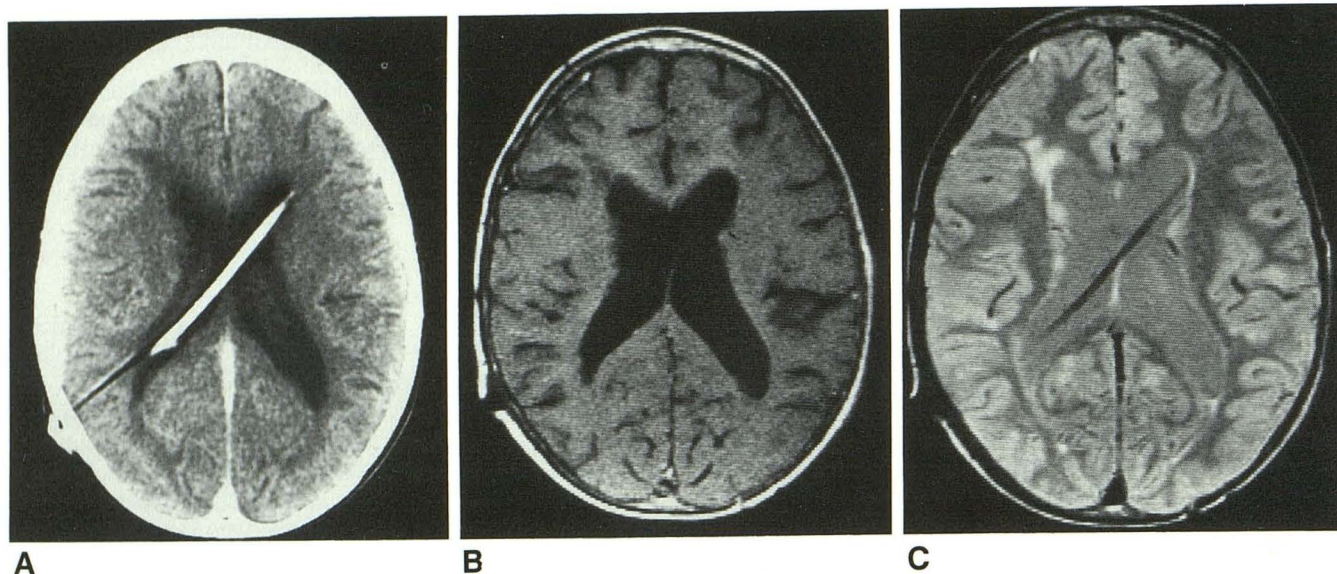


Fig. 3.—Case 3.

A, Contrast-enhanced CT scan shows subtle irregularity of lateral ventricles with no abnormal enhancement.

B, Small ependymal nodules failed to enhance with Gd-enhanced MR.

C, Metastases are shown well on spin-density image (2500/40).

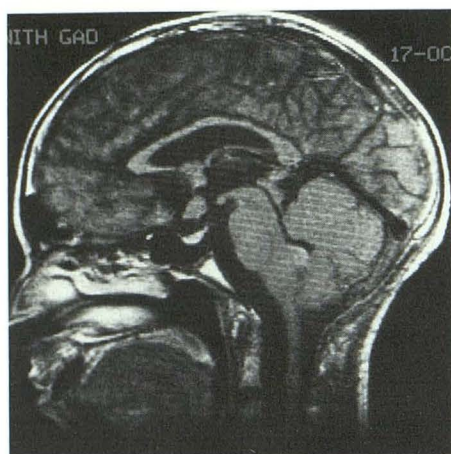


Fig. 4.—Case 4. Gd-enhanced MR image shows moderate enhancement of recurrent tumor in fourth ventricle, while metastases in the region of third ventricle fail to enhance.

who had abnormal nonenhancing MR studies. The first case showed local Gd enhancement that was presumed to represent tumor recurrence although biopsy was not performed and no follow-up was provided. The second case showed no abnormal enhancement. The authors suggested incorrectly that the absence of enhancement indicated the absence of tumor.

Our material shows that not all recurrent tumor enhances and that the absence of Gd enhancement does not necessarily exclude residual or recurrent tumor. For these reasons, T2-weighted MR images should be obtained in all patients. Conversely, the presence of Gd enhancement does not necessarily indicate the presence of tumor, since abnormal Gd enhancement may be due to disruption of the blood-brain barrier induced by radiotherapy.

By CT, the typical medulloblastoma is a well-defined slightly hyperdense, relatively homogeneous mass filling the fourth

ventricle [3]. Although most medulloblastomas demonstrate moderately intense enhancement with iodinated contrast material, up to 7% of primary tumors do not enhance [4]. The primary tumors in all our patients did enhance by CT at presentation and the reason for the failure of some of the recurrent tumors to enhance with Gd is unclear; no patients were receiving exogenous steroids that might have altered the blood-brain barrier or tumor vascularity. It is not clear why fourth ventricular recurrence enhanced in one patient while other recurrent intracranial disease elsewhere in the same patient demonstrated no appreciable enhancement.

Two of the patients with nonenhancing medulloblastoma recurrence underwent diagnostic craniotomies. Histologic review of the tumors showed them to be well differentiated with numerous Homer-Wright rosettes, low mitotic rates, and no large areas of necrosis. Histologic review of the recurrent tumors that displayed intense Gd enhancement showed them to have large pleomorphic cells with a high mitotic rate and large areas of necrosis. Although our series is too small to draw any conclusions, it appears that the enhancement pattern may parallel the histologic pattern and may have some prognostic significance. The four patients who had nonenhancing recurrent tumor had a fairly prolonged clinical course and slow growth of tumor on subsequent scans, while the patients who showed intense Gd enhancement of recurrent tumor tended to have a more rapid demise, generally after a few months.

Although the intent of this study was not to compare the sensitivity of MR with that of CT, it appears that the addition of Gd did render MR a more sensitive imaging method than nonenhancing MR or enhanced CT. However, as some recurrent tumors do not enhance, Gd-enhanced images should not replace T2-weighted images; rather, they should be used as an adjunct.

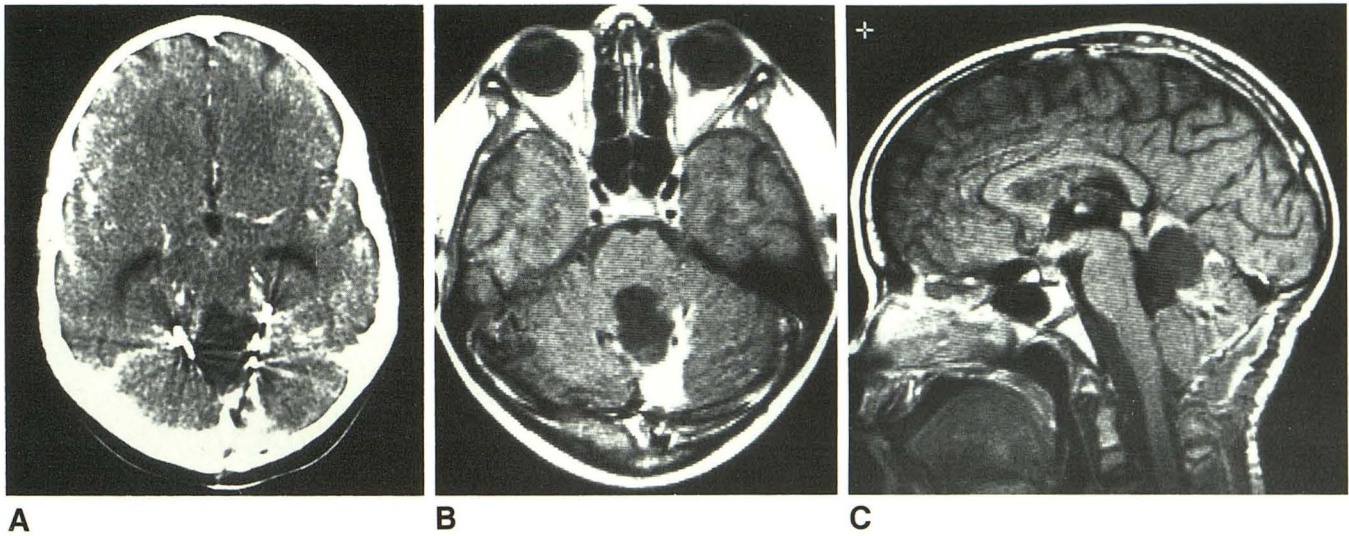


Fig. 5.—Case 6.

A, Beam-hardening and metallic artifact mask tumor on CT scan.

B, Intense enhancement in residual tumor is unobscured with Gd-enhanced MR image.

C, Leptomeningeal spread of tumor is best seen on enhanced sagittal MR images.

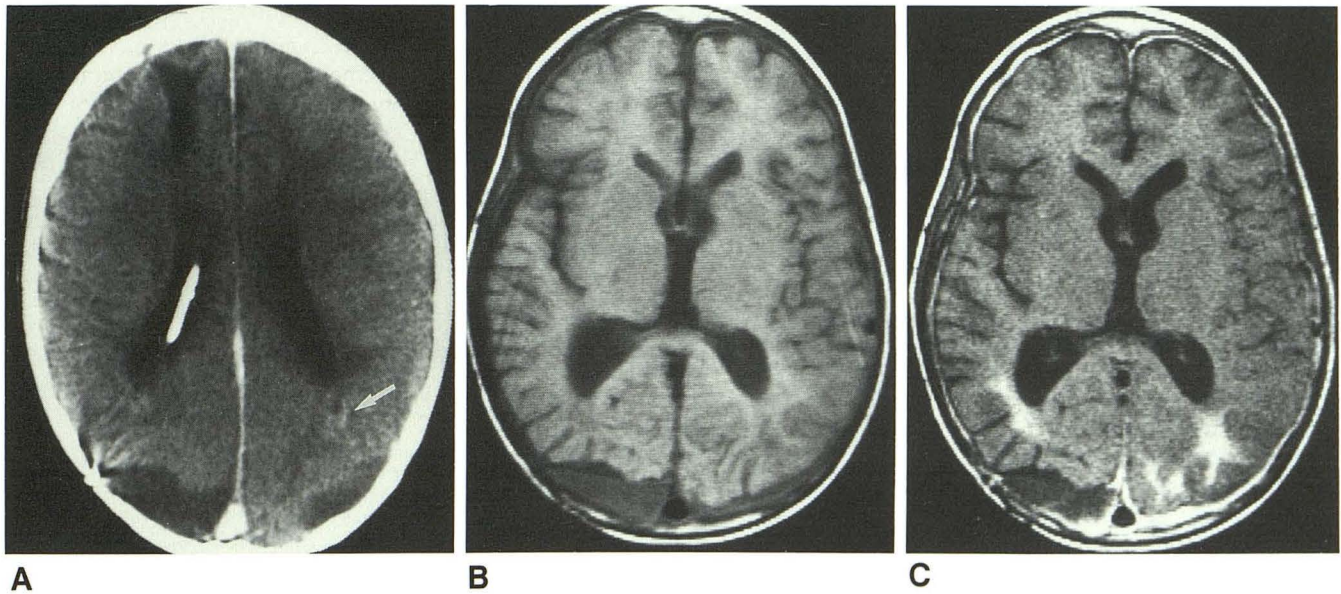


Fig. 6.—Case 9.

A, CT scan shows minimal enhancement of occipital white matter (arrow), presumed to represent radiation necrosis. No regions of abnormal enhancement were present on any other images.

B, No hyperintense areas are seen on nonenhanced T1-weighted MR image.

C, Marked enhancement is seen in occipital white matter bilaterally on Gd-enhanced MR image.

REFERENCES

- Bird CR, Drayer BP, Medina M, et al. Gd-DTPA-enhanced MR imaging in pediatric patients after brain tumor resection. *Radiology* 1988; 169:123-126
- Powers TA, Partain CL, Kessler RM, et al. Central nervous system lesions in pediatric patients: Gd-DTPA-enhanced MR imaging. *Radiology* 1988; 169:723-726
- Sandhu A, Kendall B. Computed tomography in management of medulloblastomas. *Neuroradiology* 1987; 29:444-452
- Zee CS, Segall HD, Miller C, et al. Less common CT features of medulloblastoma. *Radiology* 1982; 144:97-102