

Demonstration of the Area Postrema with Contrast-Enhanced MR

Contrast media that distribute in the extracellular space, such as iodinated compounds used in cerebral CT and paramagnetic chelates used in MR imaging, do not enter areas of the CNS that have an intact blood-brain barrier. Studies of the barrier suggest that its location is the capillary endothelial cells, which differ from those outside the CNS because of the presence of zona occludens (tight junctions), narrow intercellular gaps, nonfenestrated endothelial basement membranes, and absence of pinocytosis [1]. Several brain sites do not possess these unique capillary endothelial cells, thus permitting intravascular contrast medium to cross into the brain (i.e., enhancement). These sites include the circumventricular organs, posterior pituitary gland, infundibulum, and choroid plexus [1, 2]. Increased density in both arteries and veins is seen on enhanced CT, whereas only areas of nonturbulent venous flow will show increased signal intensity after injection of paramagnetic contrast medium in MR imaging. This report describes visualization of enhancement in a circumventricular organ, the area postrema, with MR.

Case Report

A 32-year-old woman had type I neurofibromatosis. Previous CT studies showed bilateral enlargement of the optic nerves. Examination of a biopsy specimen of the right optic nerve showed astrocytic proliferation consistent with a low-grade optic glioma. A follow-up enhanced MR examination was requested.

MR at 1.5 T was performed before and after IV injection of 0.1 mmol/kg gadopentatate dimeglumine (Magnevist, Berlex Laboratories Inc., Wayne, NJ). T1-weighted sagittal images, 600/20/2 (TR/TE/excitations), with a 256 × 192 matrix, 3-mm thickness, and 1-mm gap were obtained. The images showed enlargement of the optic chiasm with subtle enhancement. A discrete focus of enhancement in the medulla just dorsal to the obex was noted on the enhanced series (Fig. 1). This location corresponds to the position of the area postrema (Fig. 2).

Discussion

The circumventricular organs are located along the midline of the brain on the surface of the ventricular system. These structures include the area postrema, subfornical organ, organum vasculosum of the lamina terminalis, median eminence, pineal body, and neurohypophysis [3–5]. These small structures do not have the typical capillary endothelial cell morphology seen in other parts of the brain. The circumventricular organs are highly vascular with large perivascular spaces into which neuronal processes extend. These structures are central receptor sites for circulating factors in the blood [4].

In rodents, the area postrema is a central structure in the dorsal medulla at the junction of the fourth ventricle and central canal of the spinal cord. In most other species, it is a paired structure that extends along the caudal margins of the fourth ventricle [4]. The 3-mm slice thickness used in our case volume averages the paired area postrema at the level of the obex. The choroid plexus attaches to the area postrema and shares vascular connections. Enhancement of the choroid plexus may be seen near the area postrema; however, the choroid plexus of the fourth ventricle usually lies just ventral to the inferior medullary velum (Fig. 3).

Afferent projections to the area postrema are from peripheral sensory fibers, mostly vagal, and from the hypothalamus. Its efferent projections are to major relay nuclei for ascending visceral sensory information, especially the adjacent nucleus of the solitary tract and the lateral parabrachial nucleus of the pons. Motor outflow of the dorsal motor nucleus and nucleus ambiguus also is affected [4, 6]. The area postrema serves as a modulator of interoceptive information reaching it via visceral sensory neurons or humorally through its porous capillary endothelial cells [4]. It thus can elicit vomiting in response to circulating emetic substances, such as iodinated contrast medium [3, 7, 8].

The improved ability of MR to detect contrast enhancement and its multiplanar capabilities suggest that demonstration of enhance-

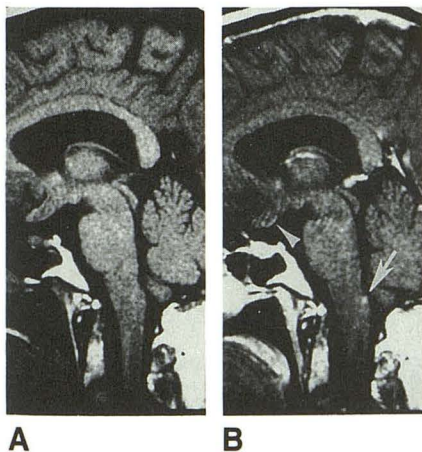


Fig. 1.—A and B, Sagittal T1-weighted MR images, SE 600/20/2, before (A) and after (B) injection of IV contrast material show small area of enhancement just dorsal to obex in area postrema (arrow). Choroid plexus of fourth ventricle is not enhanced, but pineal body is in B. Enlargement of optic chiasm and optic tracts is also present with faint contrast enhancement inferiorly (arrowhead).

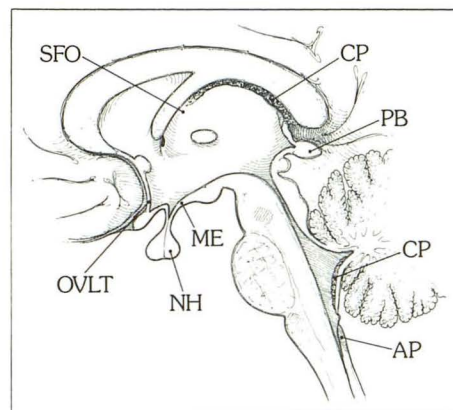


Fig. 2.—Drawing of midline sagittal section of brain shows locations of circumventricular organs. AP = area postrema, PB = pineal body, ME = median eminence, NH = neurohypophysis, OVLT = organum vasculosum of lamina terminalis, SFO = subfornical organ, CP = choroid plexus.

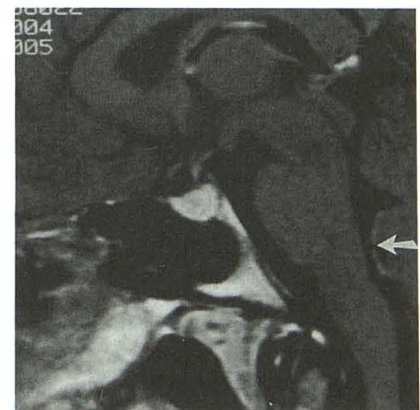

Fig. 3.—Sagittal T1-weighted MR image, SE 600/20, obtained after administration of contrast material shows enhancement in choroid plexus (arrow) just ventral to inferior medullary velum, separate from region of area postrema as seen in Fig. 1B.

ment in the area postrema will occur occasionally and should not be mistaken for disease.

Kenneth D. Williams
Bruce Dean
Burton P. Drayer
Barrow Neurological Institute
Phoenix, AZ 85013

REFERENCES

1. Sage MR. Blood-brain barrier: phenomenon of increasing importance to the imaging clinician. *AJNR* **1982**;3:127-138, *AJR* **1982**;138:887-898
2. Kilgore DP, Breger RK, Daniels DL, Pojunas KW, Williams AL, Haughton VM. Cranial tissues: normal MR appearance after intravenous injection of Gd-DTPA. *Radiology* **1986**;160:757-761
3. Carpenter MB, Sutin J. *Human neuroanatomy*. Baltimore: Williams & Wilkins, **1983**:23-24, 326-328
4. Miselis RR. Circumventricular organs. In: Adelman G, ed. *Encyclopedia of neuroscience*. Boston: Birkhauser, **1987**:251-253
5. Reichlin S. Neuroendocrinology. In: Wilson JD, Roster DW, eds. *Textbook of endocrinology*, 7th ed. Philadelphia: Saunders, **1985**:535-539
6. Shapiro RE, Miselis RR. The central neural connections of the area postrema of the rat. *J Comp Neurol* **1985**;234:344-364
7. Borison HL, Brizzee KR. Morphology of emetic chemoreceptor trigger zone in cat medulla oblongata. *Proc Soc Exp Biol Med* **1951**;77:38-42
8. Lalli AF. Contrast media reactions: data analysis and hypothesis. *Radiology* **1980**;134:1-12

Erratum

In the article "Lateral Ventricular Neoplasms of the Brain: Differential Diagnosis Based on Clinical, CT, and MR Findings" by Jelinek et al. (*AJNR* **1990**;11:567-574), an error was made in Figure 8. The branching between "No CT Enhancement" and CT Enhancement" should have been under the box "FOM/Body" and not under "Trigone: Meningioma." *AJNR* apologizes for this error.