Are your MRI contrast agents cost-effective?
Learn more about generic Gadolinium-Based Contrast Agents.
FRESENIUS KABI
caring for life

Multiple sclerosis in children: value of serial MR studies to monitor patients.

F Ebner, M M Millner and E Justich

AJNR Am J Neuroradiol 1990, 11 (5) 1023-1027
http://www.ajnr.org/content/11/5/1023

This information is current as of April 17, 2024.

Multiple Sclerosis in Children: Value of Serial MR Studies to Monitor Patients

Franz Ebner[1]
Michael M. Millner[2]
Erwin Justich[1]

A series of six children with clinical (4) and laboratory (2) evidence of multiple sclerosis is described. The mean age at onset was 12 years and the female-male ratio was 5:1. All patients had white matter abnormalities on initial MR scans. On follow-up MR studies, performed every 3 to 5 months, all children exhibited changing patterns of CNS signal abnormalities. In three cases, clinically silent brain lesions were detected. In four patients with an acute clinical attack, large lesions were present, demonstrating a lamellar structure on T1- and T2-weighted images. The lesions were seen best on long TR/short TE spin-echo sequences. Combined sagittal and axial series with EKG gating and flow-compensation technique were best for MR follow-up studies.

Our results show that MR is useful for monitoring patients with multiple sclerosis.

***AJNR* 11: 1023–1027, September/October 1990**

Multiple sclerosis (MS) is diagnosed clinically by the demonstration of white matter dysfunction separated in time and anatomic location [1]. MR imaging detects white matter abnormalities of MS and has been used to identify multiple anatomic sites of the disease [2–6]. And serial MR examinations can be used to identify serial episodes of the disease [7–11]. The aim of the present study was to assess CNS focal white matter abnormalities in childhood MS and to relate changes in their appearance over time with the clinical course of the disease.

Subjects and Methods

Between January 1987 and January 1989, 341 children, ages 2–14 years old, were referred for MR of the brain for evaluation of various neurologic deficits. One hundred seventy-nine children were in the 2–9 age group, and 162 children were in the 10–14 age group. There were 187 boys and 154 girls. The clinical work-up of patients with focal CNS white matter abnormalities revealed the presence of MS in six patients, all in the 10–14 age group. No case of MS was observed in the 2–9 age group.

MR was performed on a superconductive 1.5-T magnet system (Gyroscan S 15, Philips Company Eindhoven, Netherlands). T1-weighted images were obtained by using inversion recovery (IR) pulse sequences, 1500/450/30/4 (TR/TI/TE/excitations) and partial saturation spin-echo (SE) pulse sequences (450–600/20/4). T2-weighted images were obtained with a conventional spin-echo technique (multislice-multiecho sequence [SE 2500/30,60/2]) and with a gradient-echo technique (reduced flip angle of 15° and the shortest TR/TE). Sagittal long TR/long TE SE sequences were obtained with EKG gating and flow-compensation technique. For data acquisition, a matrix of 128 or 256 × 256 was used. The thickness of the slices ranged from 5.3 to 6 mm. In general, the slice gap was 10% of the slice thickness. In all patients imaging was performed in transverse and sagittal planes and in some cases coronal sections were also obtained. MR investigations of the cervical spine were done using a rectangular surface coil. Surface-coil imaging of the optic nerve was performed in two patients (STIR sequence) [12]. As gadopentetate dimeglumine was not approved for use in children, contrast scans were not done at that time.

Received August 14, 1989; revision requested October 3, 1989; revision received April 13, 1990; accepted April 19, 1990.

[1] Department of Radiology, MR-Center, Auenbruggerplatz 9, A-8036 Graz, Austria. Address reprint requests to F. Ebner.

[2] Department of Pediatrics, Karl-Franzens-University, Graz, Austria.

0195–6108/90/1105–1023
© American Society of Neuroradiology

Results

The average age of onset of MS in the present series was 12 years; the female-male ratio was 5:1. Table 1 gives the clinical presentation, CSF analysis, visual evoked responses (VER), brainstem auditory evoked responses (BAER), and EEG results. According to the clinical classification of Poser et al. [13], four children had clinically definite MS and two had laboratory supported definite MS.

The patients presented clinically with motor symptoms (4/6), visual disturbances (2/6), urinary dysfunction (2/6), gait disturbances (1/6), vertigo (1/6), and nystagmus (1/6). Of all paraclinical tests (see Table 1) MR proved to be the most useful for establishing the clinical diagnosis of MS. Clinically definite MS was diagnosed in four patients and laboratory supported definite MS in two patients. The time interval between the first clinical attack and the first examination by MR ranged from 2 weeks to 6 months (average, 5 weeks). Initial MR imaging detected an average of 16 lesions per patient (range, 3–50 lesions); follow-up MR, performed after an interval of 3 months (range, 7–13 weeks), found an average of 21 lesions per patient (range, 3–85 lesions). A third MR examination 5 months later (range, 6 weeks–12 months) demonstrated an average of 27 lesions per patient (range, 3–115 lesions). In four of six patients, a fourth MR study 8 months later showed a further increase in the number of lesions. Of six patients with follow-up MR, three had no clinical attack to suggest new MS plaques in the brain. Therefore, in three of six patients clinically silent lesions and/or progression of the demyelinating process was detected by MR. The MS lesions were located most frequently in the centrum semiovale (6/6), optic radiation (3/6), basal ganglia (3/6), brainstem (3/6), cervical medulla (3/6), corpus callosum (2/6), subcortical white matter (2/6), cerebral gray matter (1/6), and cerebellar peduncle (1/6). On initial MR examination all patients had brain white matter abnormalities that fulfilled the criteria of the MR classification of MS developed by Paty et al. [14].

On follow-up examinations all patients exhibited changing patterns of the multifocal CNS signal abnormalities: increase and decrease in number and size of MS foci, disappearance of lesions, lesions found in completely new locations, and confluence of the lesions (Figs. 1–4).

In four patients with acute clinical attack, large lesions (8–21 mm in diameter) were present, demonstrating a lamellar structure on both T1- proton-density- and T2-weighted images (Figs. 1 and 2A).

The large foci all demonstrated a central spherical core of low signal on T1-weighted images, isointense with CSF. This core was surrounded by a thick rim of high signal on T1- and proton-density-weighted images. In two children with a fresh demyelinating process, extensive perifocal white matter edema was indicated on MR (Fig. 1B). On follow-up this edema had resolved after an interval of 11 weeks (case 1) and 6 weeks (case 3). The large lesions in cases 1, 3, 4, and 6 showed a gradual decrease in size but still kept their anatomic characteristics during the observation period of 19 weeks (case 3), 26 weeks (case 4), and 15 months (cases 1 and 6).

All lesions had the highest signal/noise ratio compared with CSF and gray and white matter on proton-density-weighted, long TR/short TE SE sequences.

TABLE 1: Case Description

Case No.	Sex	Age at Onset (years)	First Symptoms	Oligoclonal Bands (OB)	CSF WBC	Protein	Visual Evoked Responses (VER)	Brainstem Auditory Evoked Responses (BAER)	EEG	Diagnostic Criteria (Poser et al. [13])
1	F	11	Weakness of left hand, vertigo	+	24	33	Normal	Normal	Normal	Laboratory supported definite MS[a]
2	F	13	Blurred vision, staggering gait, urinary dysfunction	–	24	27	Normal[b]	Normal	Normal	Clinically definite MS[b]
3	F	13	Spastic hemiplegia, nystagmus	+	27	39	Normal	Normal	Normal	Laboratory supported definite MS[a]
4	F	13	Divergent strabismus	+	16	23	Abnormal	Normal	Normal	Clinically definite MS[b]
5	F	11	Enuresis, weakness, paresthesia of lower limbs	–[c]	39	28	Abnormal	–	Sharp waves	Clinically definite MS[b]
6	M	13	Weakness of left arm	+[a]	29	58	Normal	–	Normal	Clinically definite MS[c]
7*	F	12	Diplopia, vertigo, staggering gait	+	25	27	Abnormal	Normal	Normal	Clinically definite MS[c]

[a] First investigation of OB 12 months after onset.
[b] VER normal but computerized perimetry abnormal.
[c] Elevated IgG but no OB.
* Recent case of MS not included in present study.

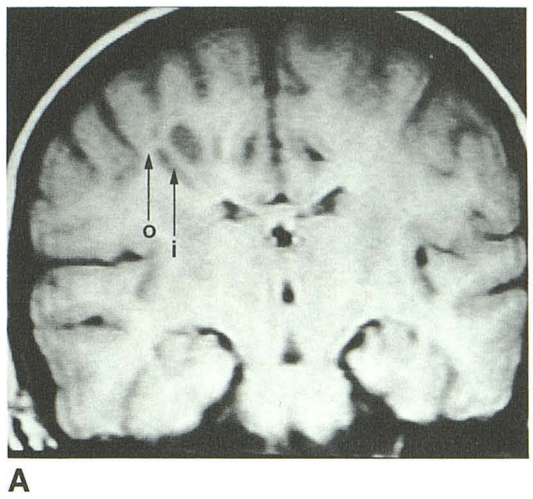

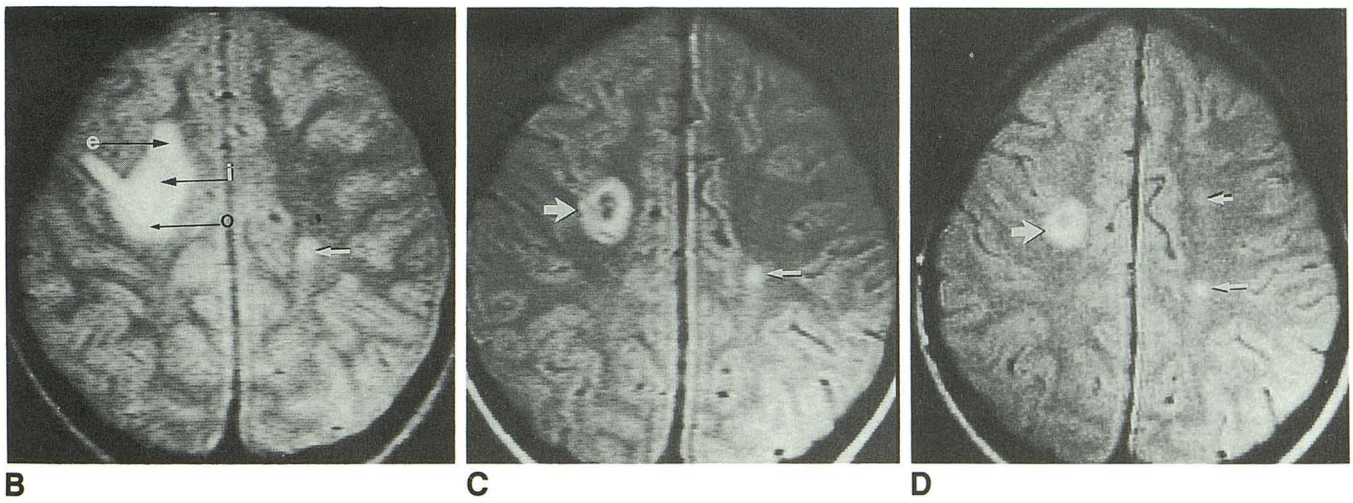

Fig. 1.—Case 1: 11-year-old girl with laboratory supported definite MS.

A, Coronal T1-weighted (700/30) spin-echo MR image 4 weeks after first clinical attack shows three separate lesions with lamellar structure. (i = inner zone of the lesion, o = outer zone)

B, Axial T2-weighted (2500/60) spin-echo MR image shows large lesion with surrounding edema. (i = inner zone, o = outer zone, e = edema)

C, Axial proton-density-weighted (2500/30) spin-echo MR image 11 weeks after first clinical attack shows lamellar structure of the lesion in the right centrum semiovale (*large arrow*). There was complete resorption of the previous edema.

D, Axial proton-density-weighted (2500/30) spin-echo MR image 15 months after first clinical attack shows further decrease in the size of the large lesion (*large arrow*). There was persistence of the lamellar structure.

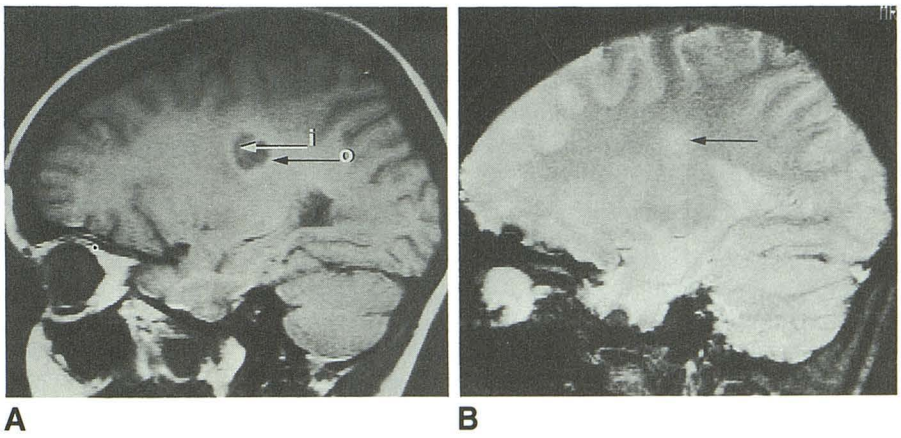

Fig. 2.—Case 3: 13-year-old girl with laboratory supported definite MS. MR shows the changing appearance of the acute and chronic MS focus on serial images.

A, Sagittal T1-weighted (600/30) spin-echo MR image shows lamellar structure of acute MS plaque. Diameter of lesion is 21 mm. (i = inner zone, o = outer zone)

B, Sagittal T2-weighted (600/35) gradient-echo MR image (flip angle = 15°) 1 year later shows decreased size and hazy appearance of chronic MS plaque (*arrow*) without any inner structure.

Combined series in axial and sagittal planes proved best for serial comparison of the distribution and number of focal white matter abnormalities on MR studies. Even small foci (less than 3 mm in diameter) could be reassessed on multiple follow-up examinations.

In case 5, a patient with clinically rapid progression, confluence of the periventricular lesions was observed and significantly worsened during the observation period of 6 months (Fig. 3).

Discussion

The frequency of MS with known onset in childhood ranges from less than 0.4% of all MS cases [15] and 2.7% [16] and

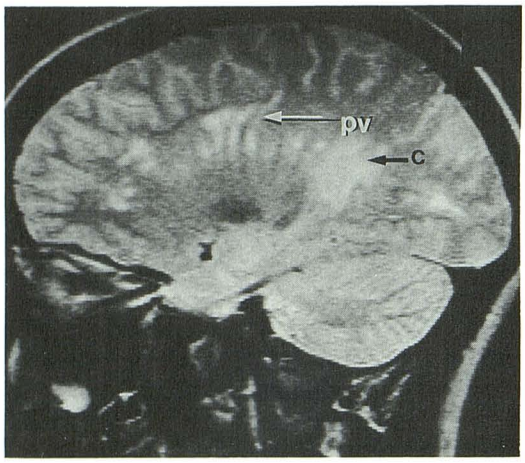

3

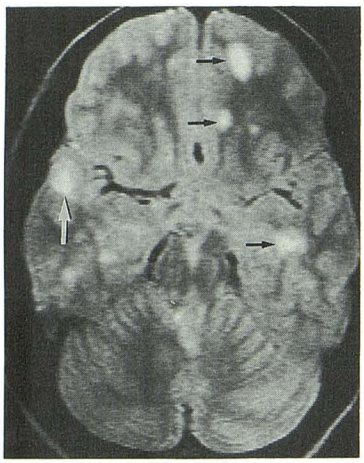

4

Fig. 3.—Case 5: At onset, 11-year-old girl with rapidly progressive course of clinically definite MS. Sagittal T2-weighted MR image at age 14 shows curvilinear hyperintensities in the corona radiata, possibly representing distribution of edema within the white matter tracts of the corona radiata or in perivascular-perivenous compartment. (pv = perivascular, c = confluence of periventricular lesions)

Fig. 4.—Case 4: At onset, 13-year-old girl with clinically definite MS. Axial T2-weighted (2500/60) spin-echo MR image at age 14 shows multiple foci at corticomedullary junction (*small black arrows*) in both cerebral hemispheres, and at least one large focus within the cortical layers of the right temporal lobe (*large white arrow*).

6% [17]. Early onset of MS has been described at 4 years [18] and at 2 years [19], and a patient with autopsy-verified MS, described by Shaw and Alvord [20], reportedly had the first of 11 attacks at the age of 10 months.

The female-male ratio in adults with MS is reported to be about 2:1; but in children it has been reported at 3:1 [16], 4:1 [21], and 5:1 in the present study. The frequency of MS in our population seems high in this 2-year observation period, although exact figures cannot be derived from this selective group of patients referred for MR. Whether this high frequency is due to a previously unrecognized early onset or represents an epidemic cluster of childhood MS cannot be determined at this time.

Initial clinical symptoms of MS in childhood are sensory symptoms (26.4%), optic neuritis (14%), diplopia (11%), pure motor symptoms (11%), gait disturbance (8%), blurred vision (6%), cerebellar ataxia (5%), sensory and motor symptoms (5%), and sphincter problems (0.8%) [16]. Brett [22] called optic neuritis in childhood a potential harbinger of MS, because isolated optic neuritis often is found to be the first clinical manifestation of MS [22–25]. Compston et al. [26] reported a conversion rate from optic neuritis to clinically definite MS of 60% within 8 years, Rizzo and Lessell [27] reported 74% and Francis et al. [28] reported 75% within 15 years. Dementing processes after rapid progression of childhood MS and psychotic symptoms were also described [19, 21]. In a few reports [29–32] the initial symptoms resembled an acute encephalopathy, and sometimes MS presented clinically and radiologically as a brain tumor or abscess. Mild headache, dizziness, nausea, vomiting, and vertigo [15] sometimes accompany the first clinical attack. Focal abnormalities of CNS white matter are encountered frequently in MR of the aging brain and in patients with cerebrovascular or cardiac risk factors. In the pediatric population MR white matter abnormalities are reported in acute disseminated encephalomyelitis (ADEM), progressive multifocal leucoencephalopathy, CNS lymphoma, mitochondrial encephalomyopathy, herpes simplex encephalitis, mucopolysaccharidosis, homo- and heterozygote adrenoleukodystrophy, methotrexate-encephalopathy, neurosarcoidosis, and others [33]. Thus, the MR findings are nonspecific. Sequential MR examinations, however, are capable of assessing changes in number, size, and configuration of white matter abnormalities. Under the prerequisite of careful rescanning, this changing pattern can suffice for the diagnosis of a disseminated disease. Serial MR cannot only prove dissemination in space but also dissemination in time, demonstrating clinically silent MS lesions in the brain.

Serial MR cannot rule out ADEM, since a remitting/relapsing course in some cases of ADEM has been described, but usually a differentiation is not a problem by clinical means [14]. If high standards of consistency are placed on patient positioning within the magnet imaging system, comparative imaging might be easily and reliably accomplished in any desired plane. In our experience the most exact rescanning of previously assessed lesions in repeated MR studies was achieved by combining sagittal and transverse sections using exactly the same pulse parameters, slice thickness, and number of slices. Flow-compensation technique and EKG gating should be applied.

Pathologically, the acute MS plaque comprises perivenous hypercellularity. Around the inflamed vessels, large spaces between myelinated axons suggest edema. Lymphocytes are confined to perivascular spaces or may spread throughout the surrounding parenchyma [34]. In fresh MS plaques myelin breakdown products, largely lipids, are found free and in macrophages [35–37]. At the edges of the lesions numerous fat-filled macrophages are found. This pathoanatomic description matches the MR morphology of acute MS foci, observed in our series. The center of low signal seen on T1-weighted images, of moderate signal seen on mixed sequences, and of high signal seen on T2-weighted images possibly represents the perivenous infiltration with lymphocytes. The surrounding rim of high signal on T1- and proton-density-weighted images probably corresponds to fat-laden macrophages or to free myelin products. Thus, MR could be used to assess the in vivo progression and regression of fresh demyelinating plaques. In two cases of our series the rim of high signal on

T1-weighted images was demonstrable during a period of 15 months (cases 1 and 6).

Anatomically, the chronic MS plaque is characterized by proliferation of glial tissue [34]. The degree of gliosis contributes significantly to the intensity of the MR signal [8]. On MR the chronic MS plaques show up as smaller homogeneous lesions without any inner structure. The best contrast/noise to surrounding white matter is shown on long TR/short TE SE sequences.

Acute plaques in MS can mimic the radiologic signs of a brain tumor or abscess. In two children having their first attack we observed large tumorlike foci on cranial CT and MR. The presence of a tumorlike focus in the brain on CT demands screening for additional, subtle, or invisible smaller lesions with MR in order to avoid unnecessary brain surgery.

In summary, serial MR was capable of detecting silent brain lesions without concommitant clinical attacks and to unfold the disseminating character of the given disease process. In four of six patients in our series, very large, fresh demyelinating plaques were encountered, which demonstrated a lamellar structure persisting over a long time. In all these patients MR was able to monitor the regression of the acute MS plaque. In acute MS, MR offers a tool to evaluate the patient's response to drug therapy.

REFERENCES

1. Schumacher GA, Beebe G, Kibler RF, et al. Problems of experimental trials of therapy in multiple sclerosis: report by the panel on the evaluation of experimental trials of therapy in multiple sclerosis. *Ann NY Acad Sci* **1965**;122:552–568
2. Young IR, Randell CP, Kaplan PW, et al. Nuclear magnetic resonance (NMR) imaging in white matter disease of the brain using spin echo sequences. *J Comput Assist Tomogr* **1983**;7:290–294
3. Cutler JR, Aminoff MJ, Brant-Zawadzki M. Evaluation of patients with multiple sclerosis by evoked potentials and magnetic resonance imaging: a comparative study. *Ann Neurol* **1986**;20:645–648
4. Rudick RA, Jacobs L, Kinkel PR, Kinkel WR. Isolated idiopathic optic neuritis. Analysis of free k-light chains in cerebrospinal fluid and correlation with nuclear magnetic resonance findings. *Arch Neurol* **1986**;43:456–458
5. Golden GS, Woody RC. The role of nuclear magnetic resonance imaging in the diagnosis of MS in childhood. *Neurology* **1987**;37:689–693
6. Haas G, Schroth G, Krägeloh-Mann I, Buchwald-Saal M. Magnetic resonance imaging of the brain of children with multiple sclerosis. *Dev Med Child Neurol* **1987**;29:586–591
7. Ormerod EC, Miller DH, McDonald WI, et al. The role of NMR imaging in the assessment of multiple sclerosis and isolated neurological lesions. *Brain* **1987**;110:1579–1616
8. Isaac C, Li DKB, Genton M, et al. Multiple sclerosis: a serial study using MRI in relapsing patients. *Neurology* **1988**;38:1511–1515
9. Paty DW, Koopmanns R, Willoughby E, Li DKB. Serial MRI studies in multiple sclerosis: a new method for assessing disease activity in both chronic progressive and relapsing patients. *Neurology* **1988**;3 (Suppl 1):255
10. Uhlenbrock D, Herbe E, Seidel D, Gehlen W. One-year MR imaging follow-up of patients with multiple sclerosis under cortisone therapy. *Neuroradiology* **1989**;31:3–7
11. Willoughby EW, Grochowski E, Li DKB, Oger J, Kastrukoff LF, Paty DW. Serial magnetic resonance scanning in multiple sclerosis: a second prospective study in relapsing patients. *Ann Neurol* **1989**;25:43–49
12. Miller DH, Newton MR, van der Poel JC, et al. Magnetic resonance imaging of the optic nerve in optic neuritis. *Neurology* **1988**;38:175–179
13. Poser CM, Paty DW, Scheinberg L, et al. New diagnostic criteria for multiple sclerosis: guidelines for research protocols. *Ann Neurol* **1983**;13:227–231
14. Paty DW, Oger JJF, Kastrukoff LF, et al. MRI in the diagnosis of MS: a prospective study with comparison of clinical evaluation, evoked potentials, oligoclonal banding, and CT. *Neurology* **1988**;38:180–184
15. Gall JC, Hayles AB, Siekert RG, Keith HM. Multiple sclerosis in children. *Pediatrics* **1958**;21:703–709
16. Duquette P, Murray TJ, Pleines J, et al. Multiple sclerosis in childhood: clinical profile in 125 patients. *J Pediatr* **1987**;111:359–363
17. Müller R. Course and prognosis of disseminated sclerosis in relation to age of onset. *Arch Neurol* **1951**;66:561–570
18. DiMario FJ, Berman PH. Multiple sclerosis presenting at 4 years of age: clinical and MRI correlations. *Clin Pediatr* **1988**;27:32–37
19. Bejar JM, Ziegler DK. Onset of multiple sclerosis in a 24-month-old child. *Arch Neurol* **1984**;41:881–882
20. Shaw CM, Alvord EC Jr. Multiple sclerosis beginning in infancy. *J Child Neurol* **1987**;2:252–256
21. Bye AME, Kendall B, Wilson J. Multiple sclerosis in childhood: a new look. *Dev Med Child Neurol* **1985**;27:215–222
22. Brett EM. Disseminated sclerosis in childhood. In: *Paediatric neurology*. London: Churchill Livingstone, **1983**:225–226
23. Gilbert JJ, Sadler M. Unsuspected multiple sclerosis. *Arch Neurol* **1983**;40:533–536
24. Ormerod EC, McDonald WI, DuBoulay GH, et al. Disseminated lesions at presentation in patients with optic neuritis. *J Neurol Neurosurg Psychiatry* **1986**;49:124–127
25. Jacobs L, Kinkel PR, Kinkel WR. Silent brain lesions in patients with isolated idiopathic optic neuritis. *Arch Neurol* **1986**;43:452–455
26. Compston DAS, Batchelor JR, Earl CJ, McDonald WI. Factors influencing the risk of multiple sclerosis developing in patients with optic neuritis. *Brain* **1978**;101:495–511
27. Rizzo JF, Lessell S. Risk of developing multiple sclerosis after uncomplicated optic neuritis: a long term prospective study. *Neurology* **1988**;38:185–190
28. Francis DA, Compston DAS, Batchelor JR, McDonald WI. A reassessment of the risk of multiple sclerosis developing in patients with optic neuritis after extended follow-up. *J Neurol Neurosurg Psychiatry* **1987**;50:758–765
29. Andler W, Roosen K. Multiple Sklerose im ersten Lebensjahrzehnt. *Klin Padiatr* **1980**;192:365–369
30. Nelson MJ, Miller SL, McLain LW, Gold LHA. Multiple sclerosis: large plaque causing mass effect and ring sign. *J Comput Assist Tomogr* **1981**;5:892–894
31. Ishihara O, Yamaguchi Y, Matsuishi T, et al. Multiple ring enhancement in a case of acute reversible demyelinating disease in childhood suggestive of acute multiple sclerosis. *Brain Dev* **1984**;6:401–406
32. Hunter SB, Ballinger WE, Rubin JJ. Multiple sclerosis mimicking primary brain tumor. *Arch Pathol Lab Med* **1987**;111:464
33. Valk J, van der Knaap MS. *Magnetic resonance of myelin, myelination, and myelin disorders*. New York: Springer Verlag, **1989**
34. Rodriguez M, Powell HC, Lampert PW. Demyelination and leukodystrophy. In: Rosenberg RN, ed. *The clinical neuroscienes*. London: Churchill Livingstone, **1983**
35. McFarlin DE, McFarland HF. Multiple sclerosis (first of two parts). *N Engl J Med* **1982**;307:1183–1188
36. Prineas J. Pathology of the early lesion in multiple sclerosis. *Hum Pathol* **1975**;6:531–554
37. Prineas JW, Wright RG. Macrophages, lymphocytes, and plasma cells in the perivascular compartment in chronic multiple sclerosis. *Lab Invest* **1978**;38:409