

**Are your MRI contrast agents cost-effective?**

Learn more about generic Gadolinium-Based Contrast Agents.



**FRESENIUS  
KABI**

caring for life

**AJNR**

**Transcatheter obliteration of a cerebellar  
arteriovenous fistula with platinum coils.**

M D Smith, E J Russell, R Levy and R M Crowell

*AJNR Am J Neuroradiol* 1990, 11 (6) 1199-1202

<http://www.ajnr.org/content/11/6/1199.citation>

This information is current as  
of April 19, 2024.

# Transcatheter Obliteration of a Cerebellar Arteriovenous Fistula with Platinum Coils

Michael D. Smith,<sup>1</sup> Eric J. Russell,<sup>1</sup> Robert Levy,<sup>2</sup> and Robert M. Crowell<sup>3</sup>

A single-hole arteriovenous fistula (AVF) consists of a solitary abnormal communication between an artery and a vein without an intervening capillary network. An AVF must be distinguished from an arteriovenous malformation (AVM), which is composed of a complex network of arteriovenous connections (nidus or core). Most AVFs develop as a result of trauma; those between the internal carotid artery and the cavernous sinus (carotid-cavernous fistulas) are the most commonly encountered [1]. Spontaneous (congenital or acquired) AVFs are uncommon and may be seen in children (AVFs associated with vein of Galen malformations) or in association with angiodysplasia in patients with neurofibromatosis and Ehlers-Danlos syndrome [2]. Single-hole AVFs are also encountered in the external carotid circulation [3, 4]. Congenital AVFs located in the posterior fossa are extremely rare [5].

Because surgical treatment for solitary AVFs is difficult and often unsuccessful, transvascular embolization therapy has become increasingly important. Both balloons and platinum coils have been used to treat supratentorial AVFs [6]. Balloon embolization of a posterior fossa AVF has also been described [5]. We present a case of a single-hole posterior fossa AVF fed by a tortuous right superior cerebellar artery (SCA) in which dilated draining veins displaced the pons, resulting in a progressive neurologic deficit related to a circulatory steal and direct compression of the brainstem. The fistula and the arterial feeder were successfully occluded with platinum minicoils delivered through a Tracker microcatheter of variable stiffness (Target Therapeutics, Los Angeles, CA). Dramatic clinical improvement was noted toward the end of the procedure. The fistula was completely closed, and clinical improvement continued over the next several months. Postprocedural CT and follow-up angiography at 6 months revealed thrombosis of the large compressive varices and persistent fistula closure. We believe this case to be the first successful coil embolization of a posterior fossa AVF. The immediate neurologic improvement seen after fistula closure likely resulted from correction of the circulatory steal and brainstem decompression.

## Case Report

A 46-year-old man presented with slowly progressive left-sided weakness, diplopia, and altered mentation. At the age of 18, he had suffered a subarachnoid hemorrhage, and a diagnosis of posterior fossa AVM was made. Subsequent surgical excision was incomplete, although specific information regarding the exact diagnosis and surgical procedure is lacking. The patient did well until approximately 14 years before admission, at which time he noted gradual onset of left-sided weakness and diplopia. One year before admission, his symptoms began to increase dramatically. He became unable to ambulate without a cane, had difficulty reading and writing, and was increasingly forgetful. CT of the brain performed at an outside institution 8 months before admission revealed large enhancing vascular masses in the right posterior fossa with resultant compression of the brainstem and obstructive hydrocephalus (Fig. 1). The patient was referred to our institution for angiography and possible embolotherapy.

Neurologic examination at the time of admission revealed an alert and oriented man. Focal findings included a complete right sixth nerve palsy, nystagmus with the fast component to the left, a slight left facial droop, dysarthria, rightward tongue deviation, and left-sided weakness (lower extremity worse than upper extremity). Mild hyperreflexia was also noted on the left, and the patient had a left Babinski reflex.

Selective vertebral angiography was performed, revealing a complex vascular compartment leading to a single-hole AVF, fed by two branches of the tortuous, dilated right superior cerebellar artery. Immensely dilated veins draining the fistula at the right cerebellopontine angle markedly compressed the pons (Fig. 2). The arterial feeders were thought to be accessible to superselective catheterization.

Because of the obstructive hydrocephalus, an external ventricular drain was placed. Over the next 2 days, the patient became progressively more lethargic but remained arousable and appropriately responsive. He continued to deteriorate despite closure of the drainage.

The patient was then brought to the angiographic suite for balloon embolization of his AVF. A 2-French coaxial balloon-catheter system (Interventional Therapeutics, San Francisco, CA) was fluoroscopically guided through a nontapered guiding catheter to the distal segment of the inferior and larger of the two arterial feeders to the AVF. After test balloon inflation (near the fistula site) with nonionic contrast medium, check angiography revealed obstruction of flow toward the fistula; no adverse neurologic effects were noted. Owing to the marked tortuosity and kinking of the proximal arterial feeder, attempts

Received January 19, 1990; accepted March 27, 1990.

<sup>1</sup> Department of Radiology, Northwestern Memorial Hospital, 710 N. Fairbanks, Chicago, IL 60611. Address reprint requests to E. J. Russell.

<sup>2</sup> Department of Neurosurgery, Northwestern Memorial Hospital, Chicago, IL 60611.

<sup>3</sup> Department of Neurosurgery, Massachusetts General Hospital, Boston, MA 02114.



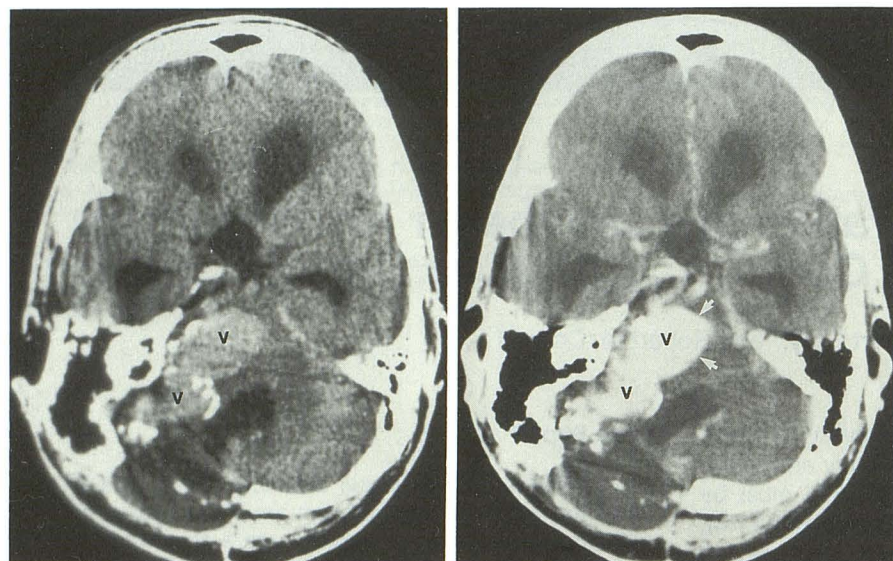


Fig. 1.—A and B, Axial pre- (A) and postinfusion (B) CT scans obtained before embolization show large, peripherally calcified, enhancing vascular masses (v) in right posterior fossa, representing aneurysmally dilated venous sacs draining the arteriovenous fistula. Brainstem is markedly compressed by the most anteromedial sac (arrows, B). Also note obstructive hydrocephalus and old postoperative changes (suboccipital craniectomy).

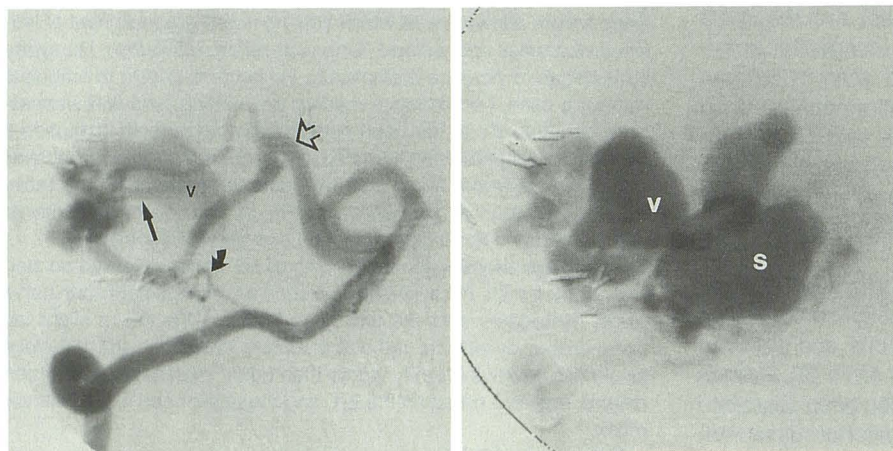


Fig. 2.—Right vertebral intraarterial digital subtraction angiograms obtained before embolization (anteroposterior oblique view).

A, Markedly enlarged right superior cerebellar artery (open arrow) is bifurcated into two dilated distal vessels, which course toward the prior operative site (marked by surgical clips). A jet of contrast through the single fistula hole (straight arrow) begins to fill the most proximal venous sac (v). Also note anterior inferior cerebellar artery branch (curved arrow), which was later found to provide collateral flow toward the fistula.

B, More distally located contiguous venous sacs filled from the first sac later during the same injection. The most distal sac (s) corresponds to the venous aneurysm, seen to compress the pons on CT studies (Fig. 1).

at balloon detachment were unsuccessful, and the catheter system fractured near the right femoral introducer sheath without balloon detachment. The balloon deflated and the proximal end of the catheter retracted into the iliac artery. To retrieve the catheter, the opposite femoral artery was then punctured, a femoral introducer sheath was placed, and a wire snare and catheter combination was advanced across the aortic bifurcation from the left to the right iliac artery. Manipulation of the snare resulted in entrapment and subsequent retrieval of the remaining intravascular catheter and balloon. At this time, no occlusion had been accomplished and the patient's neurologic status remained unchanged.

The following day, the left vertebral artery was recatheterized and check angiography revealed continued patency of the AVF. A coaxially placed Tracker microcatheter could be manipulated only as far as the junction of the two large superior cerebellar artery branches feeding the AVF. Attempts at more distal placement were unsuccessful. Six helix platinum coils (Target Therapeutics) were sequentially introduced through the Tracker catheter with a coil pusher, resulting in progressive occlusion of the feeders. The first coil that was introduced was flow-guided to the AVF hole, the remainder obstructed the feeders more proximally. Check angiography via the proximal right SCA and the left vertebral artery revealed total occlu-

sion of the two SCA feeders (Figs. 3A and 3B). A small amount of flow toward the fistulous site was noted from the right anterior inferior cerebellar artery (AICA), which collateralized to the distalmost segment of the inferior right superior cerebellar artery feeder (Fig. 3C). However, flow stasis and nonfilling of the fistula site indicated complete cessation of abnormal flow.

Toward the end of the procedure, while still in the angiographic suite, the patient's mental status improved dramatically. Immediately afterward, neurologic examination revealed an improved speech pattern, increased strength in both left extremities, and decreased nystagmus. Over the next week, continued neurologic improvement was noted. The external ventricular drain was pulled and the patient was transferred to a rehabilitation facility.

Follow-up CT 1½ months after embolization demonstrated a decrease in the previously seen hyperdensity in the lobulated veins in and around the right cerebellopontine cistern, suggesting venous thrombosis. Hydrocephalus was still present, and a ventriculoperitoneal shunt was placed. Neurologic examination 1 month later revealed no noticeable dysarthria, only minimal left facial weakness, and an essentially normal motor examination of the extremities. The right sixth nerve palsy remained stable. The patient stated his memory, balance, and coordination were greatly improved.



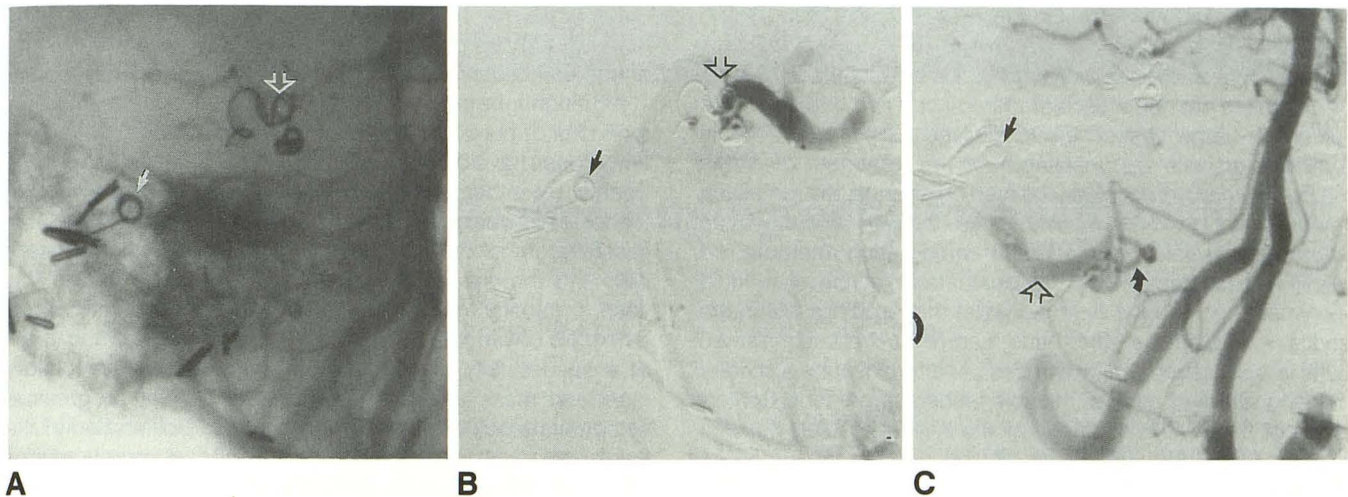


Fig. 3.—A–C, Postembolization scout view (A) and digital subtraction angiograms (B and C) acquired via catheters placed in the proximal right superior cerebellar artery (SCA) (B) and left vertebral artery (C). Note surgical clips from prior operation and newly placed platinum coils, one at the fistula site (arrow) and others at the arterial feeder bifurcation (open arrows, A and B). The two feeder branches are totally occluded (B). The more inferior SCA branch (open arrow, C) fills beyond the proximal coil occlusion by collateral flow from the right anterior inferior cerebellar artery (curved arrow, C). This blind SCA segment did not fill the fistula, owing to occlusion by the more distally placed coil (straight arrow).

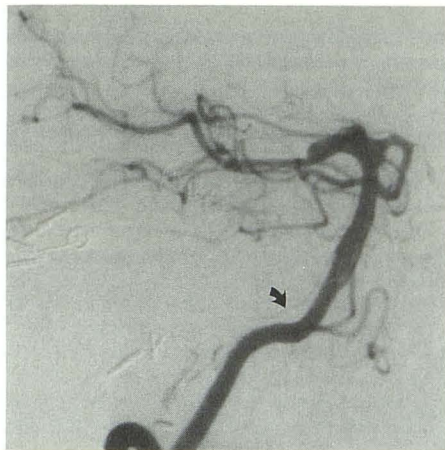

Fig. 4.—Right vertebral digital subtraction angiogram (anteroposterior oblique view) obtained 7 months after embolization. Note undisturbed coil position and no filling of the fistula, which is completely thrombosed. Also note interval decrease in size of right anterior inferior cerebellar artery (arrow; compare with Fig. 3C).

A repeat angiogram obtained 6 months after embolization revealed no filling of the fistula (Fig. 4).

## Discussion

AVMs and AVFs within the posterior fossa most often present clinically with signs and symptoms of sudden intracranial hemorrhage. Alternatively, a progressive neurologic deficit referable to the brainstem or cerebellum (e.g., ataxia, dysarthria) may be the initial complaint [7, 8]. Two mechanisms, either alone or in combination, are responsible for this presentation. High-flow arteriovenous shunting may lead to

inadequate perfusion of viable CNS tissue, a phenomenon known as cerebral circulatory steal. The resultant ischemia may be manifested as a focal neurologic deficit [9]. In addition, turbulence and increased pressure within draining veins may lead to the formation of giant intracranial varices [10]. These dilated venous channels can exert significant mass effect, producing compression of adjacent structures and impairment of CSF pathways with concomitant hydrocephalus. Vinuela et al. [11] reported eight cases of giant intracranial varices associated with AVFs; patients presented with cranial nerve palsies, gait ataxia, focal motor deficits, headache, or seizures.

It may be difficult in some cases to ascertain which of these two mechanisms is responsible for clinical symptomatology. Our patient presented with progressive focal neurologic deficits as well as altered mentation. Hydrocephalus resulted from compression of the pons and cerebral aqueduct by mass effect created by large varices. Interestingly, attempted relief of the obstructive hydrocephalus prior to embolization by placement of a ventricular drain resulted in further neurologic decompensation. It is likely that the reduction of intraventricular pressure and subsequent reduction of intracranial pressure may have created a hemodynamic environment favoring increased arteriovenous shunting, resulting in increased cerebral steal with worsening clinical symptoms. Alternatively, the change in intracranial pressure may have shifted the dilated venous sacs in such a manner as to cause more compression of the brainstem.

The labile nature of the symptomatology associated with high-flow arteriovenous shunts is further illustrated by the dramatic neurologic improvement sustained by our patient immediately after complete fistula closure. Increased left extremity strength and improved speech most likely resulted from correction of the steal, which had been further decompensated by placement of the ventricular drain. A reduction



in variceal pressure causing decreased mass effect is an alternative hypothesis.

It is important to angiographically distinguish an AVF from an AVM, as the endovascular therapy of these two entities is different. Large vasoocclusive devices such as detachable balloons or coils are unsuitable for the treatment of AVMs since they can only occlude the feeding arteries; the remaining nidus (core) can recruit new arterial feeders that are often more inaccessible to subsequent embolization attempts. An AVM is best treated with transcatheter injection of a liquid polymer (e.g., *N*-butyl cyanoacrylate) that solidifies within the nidus. AVFs, on the other hand, can be successfully treated with larger vasooccluding devices used to blockade a solitary feeding artery or each of multiple feeders, if present. Obliteration of the venous drainage or the AVF hole itself will also close the fistula, regardless of the number of supplying arteries [12, 13].

In our patient, attempts at balloon occlusion of the fistula were unsuccessful. Most technical difficulties encountered during balloon embolization relate to balloon detachment. Undesirable premature balloon detachment can occur if too little traction is needed; stretching or tearing of the surrounding vasculature can occur if too much is required [2]. We encountered an additional problem: the tortuosity of vessels leading to the fistula site prevented easy balloon detachment, resulting in a previously undescribed complication—catheter fracture. Feeder tortuosity also hampered subsequent attempts at placement of a Tracker catheter distally near the AVF hole, but more proximal positioning was successful and feeder occlusion with microcoils was accomplished without difficulty.

It has been previously stated that rapid reversal of cerebral steal by sudden reduction of blood flow through an intracranial AVM or AVF may lead to hypertensive breakthrough, blood-brain barrier breakdown, and hemorrhage in areas previously affected by the steal [14, 15]. A progressive obliteration of the fistula, with slow reversal of the steal, may prevent this complication [14]. Balloon embolization has the advantage of allowing test occlusion for several minutes while carefully monitoring neurologic function prior to permanent fistula obliteration [2, 5]. Coils, on the other hand, cannot be removed once positioned and do not permit a trial of occlusion. Our patient tolerated balloon test occlusion of the arterial feeders well, and we were thus confident that microcoils could be safely used for fistula embolization.

Consideration was given to the use of a liquid polymer as an embolic agent for obliteration of our patient's AVF. Although liquid agents are difficult to deposit accurately and may pass through a large fistula hole, Lasjaunias et al. [16] reported a case of successful embolization of a single-hole vein of Galen fistula using isobutyl 2-cyanoacrylate (IBCA) deposited within the feeding pedicle and fistula hole. IBCA is no longer available because of studies suggesting its weak mutagenicity. Its replacement, *N*-butyl 2-cyanoacrylate (NBCA), has only recently become available to us, and is still undergoing clinical FDA trials [1]. In addition, the inability to

obtain distal placement of our Tracker catheter near the fistula hole would have precluded the use of a liquid polymer were one to have been available.

Although infratentorial AVMs are not uncommon [7], only a handful of pure fistulous malformations located in the posterior fossa have been reported [5, 11, 17]. These AVFs were treated by either surgical ligation of the feeding artery or feeder occlusion with a detachable balloon. We have successfully embolized a posterior fossa AVF with microcoils delivered through a Tracker catheter. As illustrated in this case, tortuosity may inhibit distal catheterization with microcatheters of variable stiffness, or it may prevent detachment of a successfully placed balloon. Both cerebral circulatory steal and mass effect are responsible for the progressive symptomatology of posterior fossa AVFs. Obliteration of the fistula can result in rapid and dramatic clinical improvement.

## REFERENCES

1. Eskridge JM. Interventional neuroradiology. *Radiology* 1989;172:991-1006
2. Halbach VV, Higashida RT, Hieshima GB, Hardin CW, Dowd CF, Barnwell SL. Transarterial occlusion of solitary intracerebral arteriovenous fistulas. *AJNR* 1989;10:747-752
3. Berenstein A, Scott J, Choi IS, Persky M. Percutaneous embolization of arteriovenous fistulas of the external carotid artery. *AJNR* 1986;7:937-942
4. Halbach VV, Higashida RT, Hieshima GB, Hardin CW. Arteriovenous fistula of the internal maxillary artery: treatment with transarterial embolization. *Radiology* 1988;168:443-445
5. Vinuela F, Fox AJ, Kan S, Drake CG. Balloon occlusion of a spontaneous fistula of the posterior inferior cerebellar artery. *J Neurosurg* 1983;58:287-290
6. Jellinger K. Vascular malformations of the central nervous system: a morphological overview. *Neurosurg Rev* 1986;9:177-216
7. Batjer H, Samson D. Arteriovenous malformations of the posterior fossa: clinical presentation, diagnostic evaluation, and surgical treatment. *Neurosurg Rev* 1986;9:287-296
8. Ojemann RG, Heros RC, Crowell RM. Surgical management of cerebrovascular disease, 2nd ed. Baltimore: Williams & Wilkins, 1988
9. Nornes H, Grip A. Hemodynamic aspects of cerebral arteriovenous malformations. *J Neurosurg* 1980;53:456-464
10. Vinuela F, Nombela L, Roach MR, Fox AJ, Pelz DM. Stenotic and occlusive disease of the venous drainage system of deep brain AVMs. *J Neurosurg* 1985;63:180-184
11. Vinuela F, Drake CG, Fox AJ, Pelz DM. Giant intracranial varices secondary to high-flow arteriovenous fistulae. *J Neurosurg* 1987;66:198-203
12. Lawdahl RB, Routh WD, Vitek JJ, McDowell HA, Gross GM, Keller FS. Chronic arteriovenous fistulas masquerading as arteriovenous malformations: diagnostic considerations and therapeutic implications. *Radiology* 1989;170:1011-1015
13. Russell EJ, Goldblatt D, Levy JM, et al. Percutaneous obliteration of a postoperatively persistent vertebral arteriovenous fistula. *AJNR* 1989;10:196-200
14. Morgan MK, Johnston I, Besser M, Baines D. Cerebral arteriovenous malformations, steal, and the hypertensive breakthrough threshold. *J Neurosurg* 1987;66:563-567
15. Spetzler RF, Wilson CB, Weinstein P. Normal perfusion pressure breakthrough theory. *Clin Neurosurg* 1978;25:651-673
16. Lasjaunias P, Rodesch G, Pruvast P, Laroche FG, Landrieu P. Treatment of vein of Galen aneurysmal malformation. *J Neurosurg* 1989;70:746-750
17. Yasargil MG. AVM of the brain: history, embryology, pathological considerations, hemodynamics, diagnostic studies, microsurgical anatomy. *Microsurgery*, vol. IIIA. New York: Thieme, 1987:107-108