

Are your **MRI contrast agents** cost-effective?

Learn more about generic **Gadolinium-Based Contrast Agents**.



FRESENIUS
KABI

caring for life

AJNR

Spontaneous expulsive choroidal hemorrhage: CT findings.

E A Knopp and K Y Chynn

AJNR Am J Neuroradiol 1990, 11 (6) 1208-1209

<http://www.ajnr.org/content/11/6/1208.citation>

This information is current as
of April 19, 2024.

Spontaneous Expulsive Choroidal Hemorrhage: CT Findings

Edmond A. Knopp¹ and K. York Chynn^{1,2}

Spontaneous expulsive choroidal hemorrhage is a rare ophthalmologic emergency [1]. It is important for the clinician to attempt to establish an etiology of the disorder prior to any surgical intervention in order to rule out the possibility of an underlying malignancy [2]. If the hemorrhage is caused by a malignancy, patient management will be different than if no malignancy is present [3, 4]. In terms of radiologic evaluation, CT has been shown to be an accurate, precise, and noninvasive means of evaluating the eye [5].

Case Report

The patient is an 80-year-old woman whose surgical history is significant for a cataract extraction from her left eye 7 years before the present admission. Her history also includes non-insulin-dependent diabetes mellitus, hypertension, and congestive heart failure. She has no history of glaucoma. The patient stated that four days before admission her left eye had become injected; the day before admission it had become painful; and on the day of admission it had begun to bleed. She presented to the emergency room with a large bloody mass protruding from her left eye. Her blood pressure was 180/110 mm Hg. Ophthalmologic examination revealed protruded, expelled globe contents, a nonvisible cornea, and no evidence of glaucoma. The differential diagnosis included expulsive choroidal hemorrhage, mass lesion, and ruptured globe.

Thin-section contiguous axial CT sections were obtained before and after IV administration of contrast material. The CT images documented the expulsive nature of this choroidal hemorrhage, including a soft-tissue mass protruding from the anterior aspect of the eye (Fig. 1A). The globe was intact posteriorly, and a density value of 84 H was obtained from the central portion of the globe (Fig. 1B). On postcontrast CT, the choroidal vessels enhanced intensely, with the density measuring 155 H (Fig. 1C).

Orbital examination under general anesthesia showed the orbit to be unremarkable in appearance, with intraocular contents extruding out of a melted cornea and through an old cataract incision. An enucleation was performed. Pathologic examination revealed recent hemorrhage in the globe cavity with acute inflammation of the uveal tract and sclera. There was no evidence of malignancy.

Discussion

Expulsive hemorrhage is commonly associated with opening of the globe during ophthalmologic surgery [6]. It may also occur with malignant tumors, spontaneously or following trauma [7]. The frequency of true expulsive choroidal hemorrhage following cataract extraction ranges from 0.05% to 0.4% [7]. Spontaneous expulsive choroidal hemorrhage, on the other hand, is rare, with fewer than 20 cases reported [1]. It is associated with old age, high myopia, and glaucoma. Ours is one of the few reported cases in which there was no history of glaucoma.

One of the differential considerations when a patient presents with an expulsive hemorrhage is that of malignancy [7]. There have been several reports in the literature describing cases in which an enucleation was performed on the basis of a clinical diagnosis of uveal melanoma when the final pathologic examination revealed choroidal hemorrhage [8, 9]. It is therefore important to clarify the precise cause of the expulsion. CT has been shown to be valuable in the evaluation of the posterior uvea [10]. Peyman et al. [11] have documented the importance of the role of CT in evaluating choroidal detachment as well as uveal melanoma. On post-contrast CT we noted an extreme enhancement of the choroidal mass, corresponding to the enhancement of the ciliary vessels (Fig. 1C). There was no evidence of additional soft-tissue mass related to the uvea or any evidence of extrascleral disease. It has been shown that the presence of extrascleral spread of uveal melanoma can influence surgical management and prognosis [3]. Although this is controversial within the ophthalmologic community [4], it behooves the neuroradiologist to alert the ophthalmologist to the presence of malignancy.

With the clinical presentation of expulsion, the routine means of examination (ophthalmoscopy, fluorescein angiography, or sonography) are rendered almost useless. There-

Received April 5, 1990; revision requested May 1, 1990; revision received May 22, 1990; accepted May 24, 1990.

Presented at the annual meeting of the American Society of Neuroradiology, Los Angeles, March 1990.

¹ Department of Diagnostic Radiology, St. Luke's/Roosevelt Hospital Center, Columbia University College of Physicians and Surgeons, Amsterdam Ave. & 114th St., New York, NY 10025. Address reprint requests to E. A. Knopp.

² Division of Neuroradiology, St. Luke's/Roosevelt Hospital Center, Columbia University College of Physicians and Surgeons, New York, NY 10025.

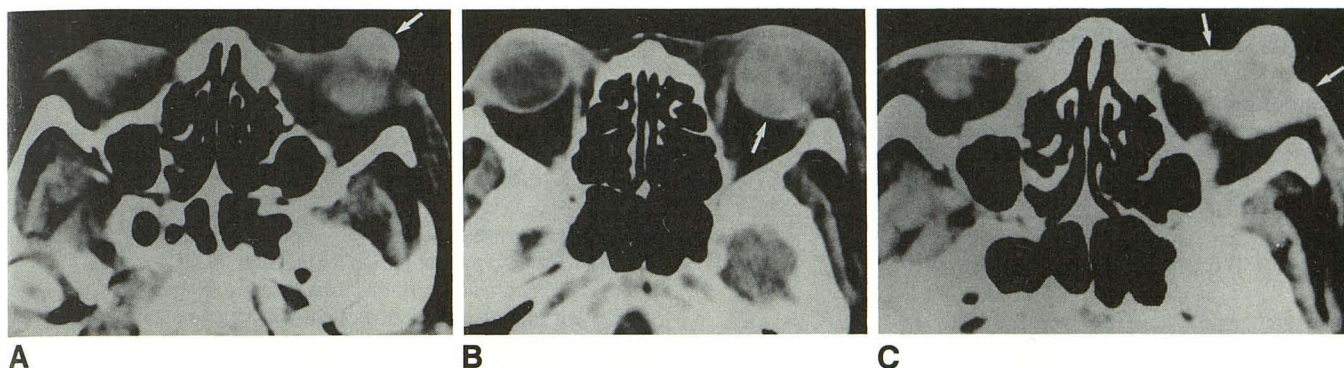


Fig. 1.—80-year-old woman with expulsive choroidal hemorrhage.

A, Precontrast CT scan shows hemorrhagic mass protruding from anterior aspect of globe (arrow); density measured 118 H.

B, Precontrast CT scan shows posteriorly intact globe (arrow) with its hemorrhagic contents; density measured 84 H.

C, Postcontrast CT scan shows dense enhancement of the mass of choroidal vessels (arrows); density measured 155 H.

fore, other means of evaluation must be used. In addition to CT, MR imaging with its ability to resolve soft-tissue contrast coupled with its multiplanar scanning capability significantly advances the state of ocular imaging. As experience increases it will soon become the premier imaging method, if it is not already considered to be so.

The necessity for rapid intervention in cases of expulsive choroidal hemorrhage is because of sympathetic ophthalmia. This autoimmune process occurs after the violation of the privileged ocular compartment. It is thought to sensitize the immune system, which will elicit a progressive inflammatory reaction in the contralateral eye, leading to blindness. It can occur as early as 10 days after injury to the first eye [12].

CT provides an accurate means of visualizing the posterior uvea in a noninvasive manner. The additional benefit of IV administration of iodinated contrast material is that it enables visualization of the vascularity of the choroid and the nature of any choroidal disease. This allows the clinician to intervene rapidly so as not to compromise the visual acuity of the contralateral eye. Establishment of the correct etiology and extent of disease prior to enucleation obviates surgical reexploration after the results of the pathologic examination are known.

REFERENCES

1. Pe'er J, Weiner A, Vidaurri L. Clinicopathological report of spontaneous expulsive hemorrhage. *Ann Ophthalmol* 1987;19:139-141
2. Shields JA, Zimmerman LE. Lesions simulating malignant melanoma of the posterior uvea. *Arch Ophthalmol* 1973;89:466-471
3. Shammas HF, Blodi FC. Orbital extension of choroidal and ciliary body melanomas. *Arch Ophthalmol* 1977;95:2002-2005
4. Shields JA, Shields CL. Malignant melanoma of the posterior uvea. In: Fraunfelder FT, Roy FH, eds. *Current ocular therapy 3*. Philadelphia: Saunders, 1990:394-398
5. Atlas SW, Zimmerman RA, Bilaniuk LT. The orbit. In: Lee SH, Rao KCVG, eds. *Cranial computed tomography and MRI*, 2nd ed. New York: McGraw-Hill, 1987:105-164
6. Jaffe NS, Jaffe MS, Jaffe GF. *Cataract surgery and its complications*, 5th ed. St. Louis: Mosby, 1990:497-505
7. Whitehouse GM, Filipic M, Francis IC. Expulsive choroidal haemorrhage: a clinical and pathological review. *Aust NZ J Ophthalmol* 1989;17:225-232
8. Ferry AP. Lesions mistaken for malignant melanoma of the posterior uvea. *Arch Ophthalmol* 1964;72:463-469
9. Rones B, Zimmerman LE. An unusual choroidal hemorrhage simulating malignant melanoma. *Arch Ophthalmol* 1963;70:30-32
10. Mafee MF, Peyman GA, McKusick MA. Malignant uveal melanoma and similar lesions studied by computed tomography. *Radiology* 1985;156:403-408
11. Peyman GA, Mafee MF, Schulman J. Computed tomography in choroidal detachment. *Ophthalmology* 1984;91:156-162
12. Smolin G, O'Connor GR. *Ocular immunology*, 2nd ed. Boston: Little, Brown, 1986:331-335