

Are your **MRI contrast agents** cost-effective?

Learn more about generic **Gadolinium-Based Contrast Agents**.



FRESENIUS
KABI

caring for life

AJNR

Eighth nerve herpetic neuritis and contralateral rhombencephalitis and mesencephalitis on contrast-enhanced MR imaging.

E E Awwad and D S Martin

AJNR Am J Neuroradiol 1991, 12 (1) 198

<http://www.ajnr.org/content/12/1/198.citation>

This information is current as of April 17, 2024.

Eighth Nerve Herpetic Neuritis and Contralateral Rhombencephalitis and Mesencephalitis on Contrast-Enhanced MR Imaging

Tien et al. [1] recently reported on the MR findings in herpes trigeminal neuritis and rhombencephalitis. We report a similar case of herpetic auditory neuritis, rhombencephalitis, and mesencephalitis following the auditory tract.

The patient was a 46-year-old man who had had a liver transplant 2 years earlier. A vesicular cephalic rash and right-sided otalgia developed over 2 weeks. Approximately 7 days later, a progressive right-sided hearing loss began, and the otalgia and tinnitus subsided. The patient became deaf on the right side after 1 week. No other neurologic symptoms or signs were present. Herpes viral titers were elevated at the time of physical examination.

Subsequent MR showed contrast enhancement within the right internal auditory canal on T1-weighted images (Fig. 1A). T2-weighted images showed increased signal intensity in the vicinity of the contralateral inferior colliculus and the contralateral midmesencephalon (Fig. 1B). Our findings are similar to those described by Tien et al. In both cases, the paraaxial portions of the nerve appeared to enhance, whereas the central involvement was shown on the T2-weighted images only.

Eric E. Awwad

David S. Martin

St. Louis University Medical Center
St. Louis, MO 63110-0250

REFERENCE

1. Tien RD, Dillon WP. Herpes trigeminal neuritis and rhombencephalitis on Gd-DTPA-enhanced MR imaging. *AJNR* 1990;11:413-414

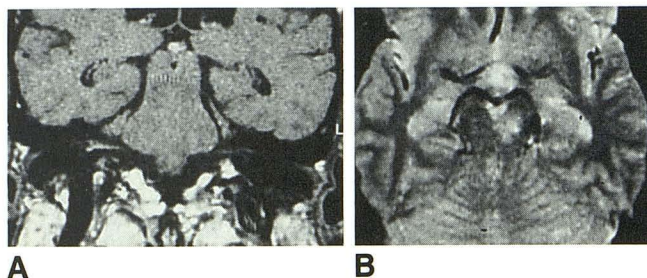


Fig. 1.—Eighth nerve herpetic neuritis and contralateral rhombencephalitis and mesencephalitis.

A, T1-weighted MR image at 0.38 T, SE 550/20, obtained after administration of gadopentetate dimeglumine shows enhancement within right internal auditory canal.

B, T2-weighted MR image, SE 2000/75, shows increased signal intensity within left midbrain.

Reply

The symptoms and signs of the case presented by Drs. Awwad and Martin are similar to those of Ramsay Hunt syndrome, which usually is caused by herpes zoster virus. However, their case was caused by herpes simplex. The inflammatory involvement of the auditory pathway is interesting. In fact, I have seen several cases each of herpes simplex neuritis associated with rhombencephalitis, Ramsay Hunt syndrome, and herpes zoster ophthalmicus. I think MR will reveal more cases of inflammatory cranial neuritis caused by herpesviruses.

Robert D. Tien

University of California, San Diego, Medical Center
San Diego, CA 92103-19907

Letters are published at the discretion of the Editor and are subject to editing.
Letters to the Editor must not be more than two *double-spaced*, typewritten pages. One or two figures may be included. Abbreviations should not be used.
Material being submitted or published elsewhere should not be duplicated in letters, and authors of letters must disclose financial associations or other possible conflicts of interest.
Letters concerning a paper published in the *AJNR* will be sent to the authors of the paper for a reply to be published in the same issue. Opinions expressed in the Letters to the Editor do not necessarily reflect the opinions of the Editor.