

Are your **MRI contrast agents** cost-effective?

Learn more about generic **Gadolinium-Based Contrast Agents**.



FRESENIUS
KABI

caring for life

AJNR

Gadopentetate dimeglumine-enhanced MR imaging in children following surgery for brain tumor: spectrum of meningeal findings.

P A Hudgins, P C Davis and J C Hoffman, Jr

AJNR Am J Neuroradiol 1991, 12 (2) 301-307

<http://www.ajnr.org/content/12/2/301>

This information is current as of April 18, 2024.

Gadopentetate Dimeglumine–Enhanced MR Imaging in Children Following Surgery for Brain Tumor: Spectrum of Meningeal Findings

Patricia A. Hudgins¹
Patricia C. Davis
James C. Hoffman, Jr.

Gadopentetate dimeglumine–enhanced MR imaging was performed in 51 consecutive postoperative pediatric neurosurgical patients with a diagnosis of brain tumor. These studies were examined retrospectively to determine the spectrum of meningeal findings in this patient population. Patterns of enhancement were correlated with type of surgery, interval since surgery, clinical and CSF findings, and the use of radiation and steroid therapies. Normal postoperative meningeal findings include no meningeal enhancement or mild focal or diffuse dural enhancement. More moderate dural or subdural enhancement may be seen in clinically well children who have postsurgical subdural collections, or who have a remote history of serious meningeal disease (meningitis or subarachnoid hemorrhage). In all six cases in which nodular dural, leptomeningeal, or ependymal enhancement was seen, recurrent local tumor, leptomeningeal metastases, or infection were present. Leptomeningeal tumor or infection should be suspected if such patterns of enhancement are noted. Parameters that did not appear to affect the pattern of meningeal enhancement included type of surgery, interval since surgery, or therapeutic radiation.

AJNR 12:301–307, March/April; *AJR* 156: June 1991

MR is essential for initial and follow-up imaging of pediatric patients with intracranial lesions. Advantages of MR include superior soft-tissue contrast, multi-planar capability, and absence of beam-hardening artifacts in the posterior fossa [1–4]. Gadopentetate dimeglumine has proved to be a useful adjunct for demonstration of lesions that disrupt the blood-brain barrier, for extraaxial lesions, and for leptomeningeal diseases [5–12].

Recent reports describe meningeal enhancement with gadopentetate dimeglumine following a wide variety of CNS surgical procedures, primarily in adults [10, 13–15]. In children, the expected postoperative enhancement patterns, the time course of this enhancement, and the relationship of this enhancement to radiation therapy have not been reported. Children with brain tumors are a unique population and are different from adults: they more commonly have lesions located in the posterior fossa, neurosurgical intervention frequently involves both tumor biopsy or resection and placement of ventricular shunts, and leptomeningeal spread of tumor is a common complication.

In this series, patterns of meningeal enhancement on MR in 31 children with known brain tumors and prior cranial surgical procedures were correlated with the interval and type of surgery, clinical and CSF evaluations, and other therapeutic treatments used (radiation and steroid therapy). From these data we attempted to identify the spectrum of findings associated with normal patterns of postoperative meningeal enhancement. Analysis of nine cases of documented meningeal disease revealed pattern differences that suggest tumor or infection in the postoperative child.

Received May 3, 1990, revision requested July 6, 1990; revision received August 27, 1990; accepted September 10, 1990.

¹ All authors: Department of Radiology, Section of Neuroradiology, Emory University School of Medicine, 1364 Clifton Rd., N. E., Atlanta, GA 30322. Address reprint requests to P. A. Hudgins.

0195–6108/91/1202–0301
© American Society of Neuroradiology

Materials and Methods

Over a 10-month period, from September 1988 to July 1989, 58 consecutive contrast-enhanced brain MR examinations were performed in a total of 38 pediatric patients with CNS neoplasia. Seven patients were excluded from the study owing to absence of recognizable enhancement of normal structures on immediate post-enhancement sequences, indicating that these patients did not receive contrast medium. The study group then consisted of 31 patients who underwent 51 postoperative enhanced MR examinations. The population comprised 18 boys and 13 girls aged 11 months to 18 years (mean, 9 years 5 months). Nineteen patients had one postoperative enhanced MR study and 12 had two or more follow-up enhanced MR studies. Twenty scans were obtained after ventricular shunt placement and craniotomy, 12 after CT-guided biopsy and shunt placement, 10 after craniotomy only, six after ventricular shunt placement, and three after CT-guided biopsy. Enhanced MR was performed to define a known lesion or to evaluate the efficacy of surgical intervention. Clinical findings (neurologic status; interval since surgery, radiation, and chemotherapy; and other significant CNS illnesses including meningitis, hemorrhage, and shunt malfunctions) and CSF analyses (29/31) were studied by chart review.

Thirty of the 31 patients had histologic or cytologic confirmation of a CNS neoplasm. One child without histologic proof had a presumed germ cell tumor of the pineal region on the basis of MR intensities suggesting fat. Neoplasms are listed in Table 1.

MR was performed with a 1.5-T superconducting magnet (Philips Medical Systems, Shelton, CT) operating at 0.5 T (17 scans) or 1.5 T (34 scans). All studies were performed with a head coil and a spin-

echo technique. All patients had an initial localizing sagittal sequence, 400–800/20, 30/1 (TR/TE/excitations), at 5-mm slice thickness, followed by axial T2-weighted images, 1900–2200/50–100. Additional unenhanced short TR sequences (400–800/20, 30/1) in either the coronal or axial plane were completed in 28 of 31 patients. After obtaining written informed consent, gadopentetate dimeglumine (Magnevist, Berlex Laboratories, Wayne, NJ) was given in a dose of 0.1 mmol/kg IV. At least one immediate (beginning within 5 min of contrast administration) short TR sequence was completed in all patients, with additional enhanced sequences in 20 of 31 patients. Imaging planes were chosen for optimal demonstration of the primary lesion.

The unenhanced and enhanced short TR sequences were compared retrospectively by two experienced neuroradiologists. Five meningeal characteristics were evaluated: (1) degree of enhancement (mild, moderate, or marked); (2) distribution of the enhancement (diffuse or focal); (3) if focal, the proximity of the enhancement to the surgical site; (4) location of enhancement (dural, pia–arachnoidal, or ependymal); and (5) nodularity of enhancement.

Results

The distribution and location of meningeal enhancement patterns, mean interval since surgery, child's clinical status, existence of significant leptomeningeal disease, and history of radiation therapy are noted in Table 2. Thirty-eight of 51 scans revealed either no meningeal enhancement or only mild dural enhancement, either diffuse or focal at the surgical site (Fig. 1). Detailed findings on the 13 of 51 scans with more extensive enhancement are given in Table 3. Four of the 13 scans (cases 1, 2 [scan 1], 3, and 4) showed bilateral post-operative collections in the subdural space (Fig. 2). These children were clinically well. Two of the 13 with more extensive enhancement (case 2 [scans 2 and 3]) were seen in a patient with chemical meningitis based on clinical and CSF analysis (Fig. 3). This child had a cystic craniopharyngioma and the meningitis was attributed to subarachnoid contamination by intracystic contents. This patient was scanned during acute illness and again 3 months later when the illness had resolved. Both scans showed moderate, smooth, diffuse dural enhancement. One patient (case 5) who had a craniotomy and radia-

TABLE 1: Neoplasms Identified in Children Studied with Enhanced MR

Tumor Type	No. of Patients
Astrocytoma	9
Craniopharyngioma	6
Neuroblastoma	3
Ependymoma	3
Chiasmatal-hypothalamic astrocytoma	3
Other (one each: ependymblastoma, medulloblastoma, gliosarcoma, meningioma, choroid plexus papilloma, pineoblastoma, pineal region tumor [probably teratoma])	7

TABLE 2: Patterns of Meningeal Enhancement on MR Imaging

Meningeal Enhancement on MR	No. of Scans (n = 51)	Interval Since Surgery (Mean)	Clinical Status	Significant LM Disease	No. with RT	Interval Since RT (Mean)
None	9	1 wk–10 yr (3¼ yr)	Healthy	None	7	6 wk–6½ yr (8 mo)
Dural or subdural						
Mild						
Diffuse	20	1 d–5 yr (3¼ yr)	Healthy	None	12	1 mo–8 yr (2 yr)
Focal (surgical site)	9	5 d–9½ yr (2½ yr)	Healthy	None	5	1 yr–10 yr (8 yr)
Moderate	7	2 wk–8 yr (16½ mo)	Healthy, 5	PO SDH, 4; S/P remote SAH, 1; chemical meningitis, 2	2	3 mo–8 yr (5½ mo)
Nodular	4	3 mo–9 mo (6 mo)	Healthy, 3; febrile after HF Tx, 1	Normal CSF	4	1 mo–4 mo (2½ mo)
Pia-arachnoid	1	1 mo	III	Meningeal abnormalities on PE; CSF cytology: LM pineoblastoma	NP	–
Ependymal	1	2 mo	III	CSF + <i>Aspergillus</i>	NP	–

Note.—LM = leptomeningeal; RT = radiation therapy; wk = week(s); mo = month(s); yr = year(s); d = day(s); PO = postoperative; SDH = subdural hematoma; S/P = status post (after); SAH = subarachnoid hemorrhage; HF Tx = hyperfractionation treatment; NP = not performed; PE = physical examination.

Fig. 1.—14-year-old child 4 years after craniotomy and shunt placement for craniopharyngioma, now clinically well.

A, Coronal unenhanced short-TR MR image (600/30) shows ferromagnetic artifacts at craniotomy site (arrows).

B, Enhanced short-TR MR image (600/30) reveals thin, symmetric dural enhancement over both convexities and along interhemispheric fissure (white arrows). If unenhanced study had not been performed, ferromagnetic artifacts at craniotomy site (black arrows) might have been mistaken for meningeal enhancement.

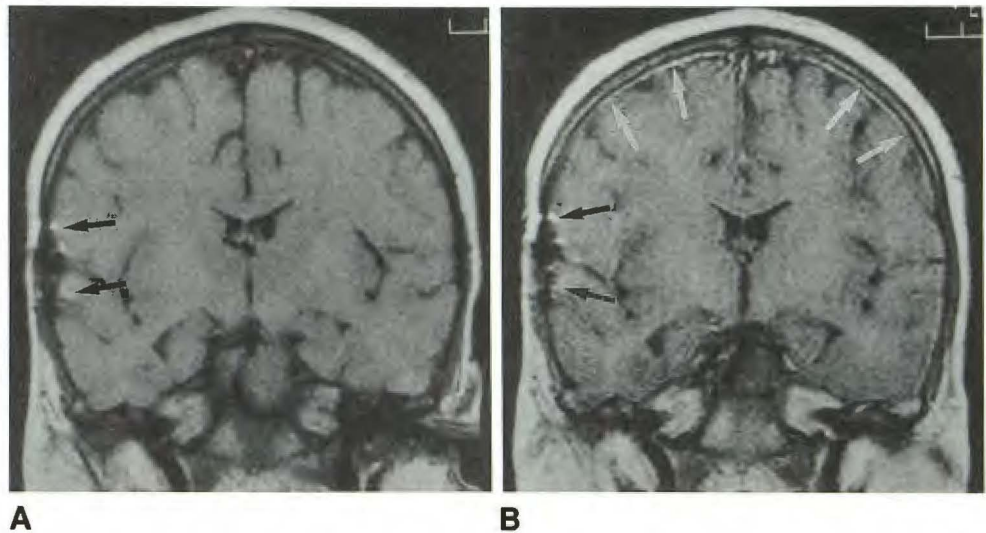


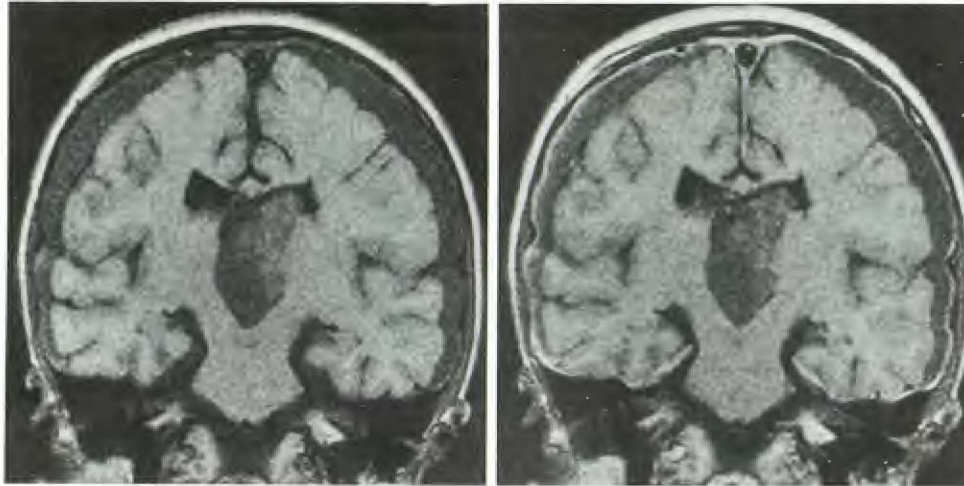
TABLE 3: Abnormal Patterns of Meningeal Enhancement

Case No.	Tumor Detected	Scan No. (Interval Since Previous Study)	Pattern of Enhancement	Reason for Enhancement Pattern
1	Craniopharyngioma	1	Moderate: dural, biconvexity	Postcraniotomy SDH; clinically well
2	Craniopharyngioma	1	Moderate: dural, biconvexity	Postcraniotomy SDH; clinically well
		2 (3 mo)	Moderate: dural; bifrontal & biparietal enhancement more prominent & diffuse	Chemical meningitis based on CSF/clinical findings
		3 (3 mo)	Moderate: dural; no change	Acute illness clinically improved
3	Hypothalamic astrocytoma	1	Moderate: dural, biconvexity	Postshunt SDH; clinically well
4	Pineal region	1	Moderate: dural, tentorial	Postshunt SDH; clinically well
5	Ependymoma	1	Moderate: dural, prepontine	3 yr S/P SAH; multiple shunt revisions; clinically well
6	Brainstem astrocytoma	1	Nodular: dural, CP angle	Known subtotal resection (presumed residual tumor); clinically well
		2 (2 mo)	Moderate: dural/subdural enhancement in prepontine cistern (CP angle nodule unchanged)	S/P hyperfractionation therapy; CSF normal
7	Medulloblastoma (CP angle)	1	Nodular: dural, CP angle	Subtotal resection (presumed residual tumor)
		2 (2 mo)	No change	Clinically well
8	Pineoblastoma	1	Marked: leptomeningeal; nodular: suprasellar, prepontine, pineal region	Leptomeningeal metastases, CSF cytology
9	Cerebellar astrocytoma	1	Intraventricular	<i>Aspergillus</i> ventriculitis & mycotic aneurysm

Note.—mo = month(s); yr = year(s); SDH = subdural hematoma; S/P = status post (after); SAH = subarachnoid hemorrhage; CP = cerebellopontine.

tion therapy for an ependymoma and had undergone multiple shunt revisions experienced a subarachnoid hemorrhage of uncertain origin. The MR examination showed moderate dural enhancement, although the patient was clinically well at that time. One patient (case 6 [scan 1]) had undergone subtotal resection of a brainstem glioma; enhanced MR showed a residual tumor nodule in the cerebellopontine angle, although the patient was clinically well. The patient then underwent hyperfractionation therapy, and a sequential enhanced MR study 2 months later (scan 2) revealed progression of enhancement. This focal enhancement was in the prepontine

cistern, and precise localization to a specific meningeal layer was not possible. The patient's only symptom was recurrent fever; he was otherwise clinically well and CSF was negative. In case 7, two scans showed focal nodular enhancement in the cerebellopontine angle; this represented residual tumor (Fig. 4). The patient had undergone subtotal resection of a medulloblastoma and was otherwise clinically well. One patient (case 8) had marked nodular leptomeningeal enhancement remote from the primary tumor site consistent with leptomeningeal metastases; CSF cytology at that time revealed metastatic pineoblastoma (Fig. 5). One patient (case



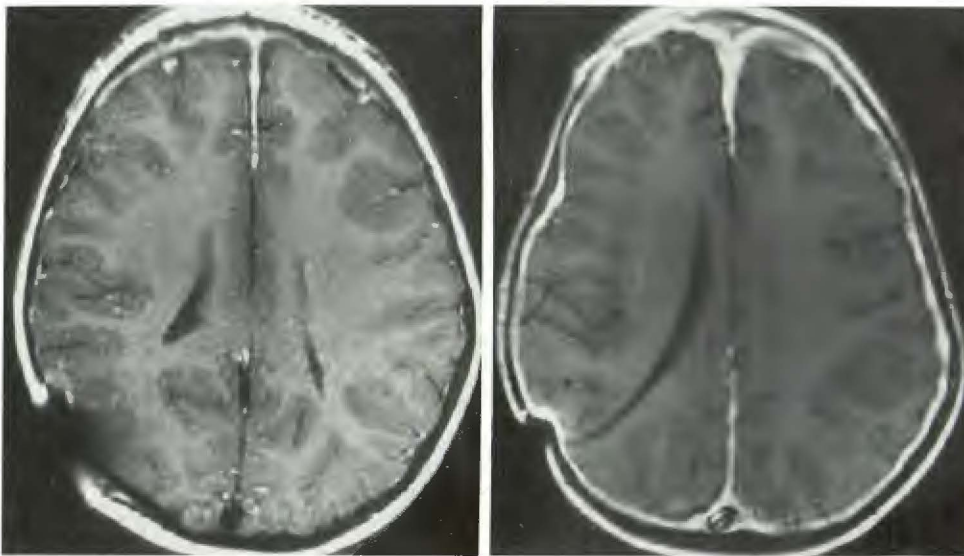
A

B

Fig. 2.—6-year-old child 2 weeks after biventricular shunt placement for hydrocephalus resulting from hypothalamic astrocytoma.

A, Coronal unenhanced short-TR MR image (600/30) shows large bilateral low-intensity subdural collections that developed after shunt placement.

B, Enhanced short-TR MR image (600/30) shows symmetric thin rim of dural enhancement along periphery of subdural effusions. The child is well, without meningeal symptoms.



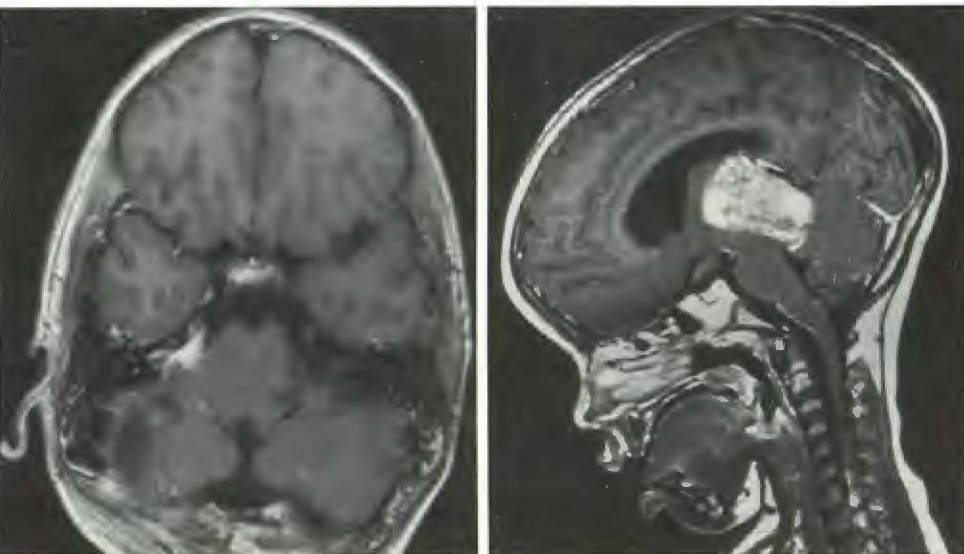
A

B

Fig. 3.—3-year-old girl with cystic craniopharyngioma.

A, Enhanced short-TR MR image (600/30) 1 month after biventricular shunt placement and frontal craniotomy reveals moderate bifrontal and interhemispheric dural enhancement. CT scan confirmed small bilateral subdural effusions. The child was clinically well.

B, Enhanced short-TR MR image (800/20) 4 months later reveals more extensive and prominent dural enhancement. CSF and clinical findings confirm chemical meningitis, probably resulting from spill of cystic tumor contents.



4

5

Fig. 4.—14-year-old boy 3 months after craniectomy for subtotal resection of medulloblastoma. Enhanced short-TR MR image (800/20). Nodular enhancement in right cerebellopontine angle represents known residual tumor.

Fig. 5.—4-year-old girl after ventricular shunt placement and CT-guided biopsy of pineal region tumor (pineoblastoma). Sagittal enhanced short-TR MR image (500/20) shows abnormal enhancement along ventral medulla. At this time, CSF was positive for tumor cells.

9) had undergone total resection of a cerebellar astrocytoma. Four months after surgery, the patient was acutely ill and an enhanced scan revealed ependymal enhancement of the right lateral ventricle (Fig. 6). CSF was positive at this time for *Aspergillus*, and the patient subsequently died from a mycotic aneurysm.

The pattern of enhancement associated with each neurosurgical procedure is shown in Table 4. No enhancement pattern was specific or isolated to a particular surgical procedure. The prevalence of enhancement was approximately equal after craniotomy and shunt placement.

Twenty-nine of the 51 scans were obtained after high-dose (5000 R [1290 mC/kg] or greater) radiation; the interval since radiation ranged from 1 month to 10 years (Table 2). All children receiving postoperative radiation were treated with high-dose steroids during part or all of the duration of radiation therapy. By the end of the radiation treatment, most had been tapered from steroids. The exact course and time of steroid taper were not available. Children in whom scans were obtained years after radiation therapy were not on steroid therapy at the time of the MR scan.

Sequential scans were obtained in 12 patients; in only four was there any change in meningeal enhancement. In one patient progression of enhancement on the second scan was temporally related to chemical meningitis. In a second patient, nodular dural enhancement due to residual cerebellopontine angle tumor progressed to moderate dural enhancement in the prepontine cistern following hyperfractionation therapy. This child was febrile with repeated normal CSF analyses following radiation therapy. Following neurosurgical procedures, postsurgical subdural hygromas developed in two patients. Progression of dural enhancement from mild to moderate was seen in both; these children were clinically well. In eight of 12 patients, there was no change in the pattern or degree of enhancement.

The unenhanced T1-weighted image was helpful for accurate interpretation of the enhanced scan (Fig. 1). In a number of cases, ferromagnetic artifacts localized to the craniotomy

site, presumably resulting from minute metallic fragments, resulted in an area of high signal along the meningeal surface; this appearance simulated postoperative dural enhancement. One patient who had undergone gross total resection 10 years before for an ependymoma had an acute, severe headache; a focal extraaxial hematoma was seen on MR at the suboccipital craniectomy site. This hematoma was manifested by high signal intensity on T1-weighted sequences and did not change in appearance following enhancement. Without the unenhanced sequence, the hemorrhagic collection might have been misinterpreted as enhancing recurrent tumor.

Discussion

Enhanced MR imaging with gadopentetate dimeglumine has emerged as the technique of choice for evaluating the postoperative pediatric neurosurgical patient. Except in the most uncomplicated clinical settings, such as shunt malfunction or sequential evaluation of uncomplicated extraaxial collections, MR imaging has supplanted CT in this area. In addition to its well-known advantages over CT, such as multiplanar capability, improved soft-tissue contrast, and lack

TABLE 4: Correlation of Surgical Procedures and Pattern of Enhancement

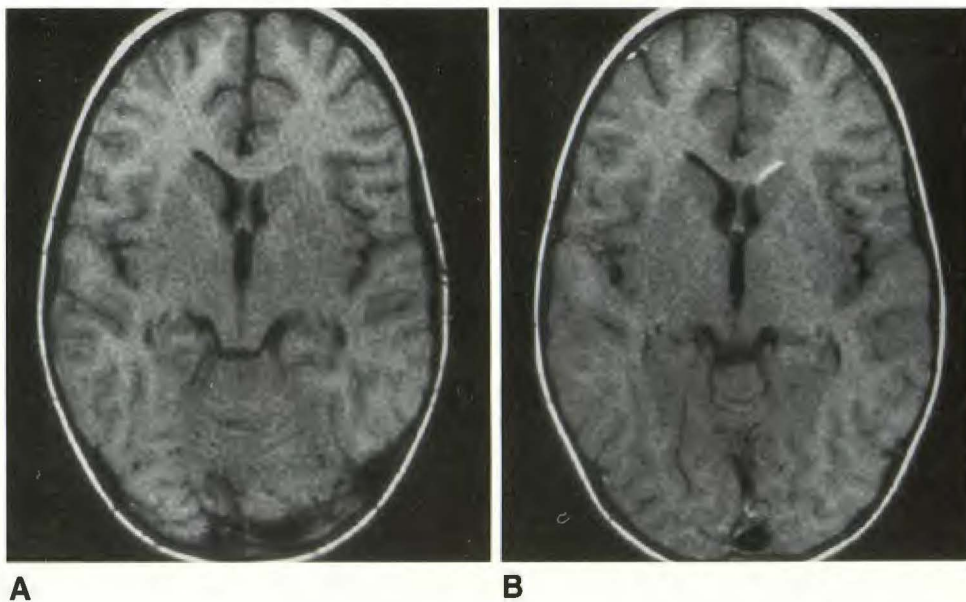
Enhancement on MR	No. of Scans (n = 51)				
	Shunt and Craniotomy	Shunt and Biopsy	Craniotomy	Shunt	Biopsy
None	3	2	1	1	2
Dural or subdural					
Mild					
Focal	5	2	1	0	1
Diffuse	5	7	5	3	0
Moderate	5	0	0	2	0
Other ^a	2	1	3	0	0
Total	20	12	10	6	3

^a Comprises nodular/dural, ependymal, leptomeningeal.

Fig. 6.—4-year-old boy 2 months after suboccipital craniectomy for gross total resection of cerebellar astrocytoma.

A, Axial unenhanced short-TR MR image (550/30) shows mild asymmetry of frontal horns; it is otherwise normal.

B, Enhanced short-TR MR image (550/30) reveals ependymal enhancement in frontal horn of left lateral ventricle. CSF culture revealed *Aspergillus*; the patient subsequently died of complications of a mycotic aneurysm.



of ionizing radiation, recent reports suggest that contrast-enhanced MR is more sensitive than contrast-enhanced CT in revealing and characterizing meningeal lesions [10]. Particularly because of beam-hardening artifacts, CT is poor in evaluating meningeal abnormalities at the base of the skull and inner table of the calvaria, regions visualized discretely on MR. Furthermore, while breakdown of the blood-brain barrier is a requirement for abnormal enhancement on both CT and MR, it has been suggested that enhanced MR may be more sensitive than enhanced CT and may reveal the breakdown at an earlier stage [8].

The blood-brain barrier is a physiologically complex structure. Simplistically, it comprises cerebral capillaries with tight junctions, the function of which is to prevent the free passage of molecules into the brain tissue [16]. The meninges, comprising the dura, the arachnoid, and the pia, are a significant site of blood-brain barrier. The dura itself is devoid of blood-brain barrier; capillary junctions within the dura are not tight and, therefore, form no barrier to prevent the free passage of molecules. One would anticipate that since it is devoid of a blood-brain barrier, the dura would enhance intensely and predictably following the administration of IV contrast material. However, it is relatively avascular, and the second requirement for contrast enhancement, an adequate delivery of contrast material via arteries and capillaries, is not met. This is the explanation for the variable enhancement pattern of the dura on both CT and MR. Both layers of the arachnoid and the pia have tight junctions within the capillaries, and, therefore, have a functional blood-brain barrier. For this reason, and despite the relative vascularity of the arachnoid and pia, enhancement within the arachnoid and the pia is not seen normally following contrast administration for either MR or CT. If arachnoidal or pial enhancement is seen, leptomeningeal disease should be suspected.

A wide variation in gadopentetate dimeglumine enhancement patterns of the dura in postoperative patients has been described [10, 13, 14]. As the enhancement pattern in the intact dura is variable [17], it is not surprising that the traumatized dura might show a variety of enhancement patterns. If this spectrum of normal postoperative enhancement patterns is familiar, recognition of pathologic meningeal enhancement is facilitated.

The ability to detect dural and leptomeningeal lesions is of particular importance in children with intracranial neoplasms, as a number of the common pediatric tumors (medulloblastoma, ependymoma, pineal region tumors, and anaplastic astrocytomas) may metastasize to the leptomeninges via the CSF. While enhanced MR is more sensitive than enhanced CT in detecting leptomeningeal enhancement, it is no more specific. Criteria for differentiation between insignificant (i.e., postoperative) and significant (i.e., neoplastic, inflammatory) meningeal enhancement have not been established for the pediatric population. The goal of this article is to describe the normal appearances of the dura and leptomeninges in the postoperative neurosurgical pediatric patient with an intracranial neoplasm.

Common postoperative findings in clinically well patients varied from no dural enhancement to smooth, thin dural enhancement, either immediately at the operative site or more

diffusely over the convexities. These findings may persist for prolonged periods (e.g., 10 years) postoperatively. A history of prior therapeutic radiation appeared to have no recognizable relationship to the presence or degree of enhancement. Similarly, the specific type of neurosurgical procedure performed had no relationship to the presence or degree of enhancement. In all cases in this study, therefore, the presence of mild, smooth dural enhancement, either focal or diffuse, implied benign postoperative meningeal changes.

A common cause of moderate dural or subdural enhancement is a subdural postoperative collection, usually nonhemorrhagic. Our experience was similar to that of other investigators in that the enhancement occurred in the peripheral portion of the collection [10]. During the organization phase of a subdural collection, numerous capillaries permeate the outer aspect of the hematoma or hygroma, forming a membrane that is relatively vascular, especially when compared with the inner avascular membrane on the arachnoidal side of the clot [18]. This explains the different degree of enhancement within a subdural collection.

Other causes of moderate dural enhancement in our series included remote subarachnoid hemorrhage and acute or remote chemical meningitis. Interestingly, enhancement in one patient persisted long after resolution of acute illness. Additional experience with enhanced MR is required to determine whether or not these findings eventually resolve. It is significant that this moderate enhancement does not always predict the presence of serious acute or active disease, but instead may be a manifestation of prior meningeal disease.

In each of the four cases (a total of six scans) in this series of enhancement of the pia-arachnoid or ependyma, or of nodular dural enhancement, a pathologic process other than simple benign postoperative enhancement was demonstrated. Although we noted only two patients with patterns of ependymal or leptomeningeal enhancement, both had significant disease. Even after intraventricular shunt placement, no ependymal enhancement was seen on 38 scans obtained after the procedure. On the basis of this limited experience, we believe that leptomeningeal or ependymal enhancement should suggest recurrent tumor or infection.

Nodular dural or subdural enhancement was not a pattern seen on scans of clinically well children. Four scans in our series showed nodular dural enhancement; in all cases this represented recurrent or residual exophytic tumor.

Radiation therapy may result in blood-brain barrier breakdown, but at clinical doses this effect may be delayed [19]. This may explain why no increase in meningeal enhancement was apparent in the subset of patients scanned soon after receiving radiation therapy. Additionally, steroid therapy stabilizes the blood-brain barrier [16, 20-23] and is often administered during part or all of the radiation course. This may be a second explanation for the lack of an increased prevalence of enhancement following radiation. Although in theory radiation may result in delayed blood-brain barrier breakdown, 14 of 29 patients scanned 1 year or more after radiation therapy had no evidence of blood-brain barrier breakdown. Thus, radiation-induced disruption of the blood-brain barrier in the relatively avascular meninges is probably subclinical and below the threshold of detection with enhanced MR. Abnormal

meningeal enhancement should not be ascribed to radiation therapy until other causes have been excluded.

No patient in this series with normal dura, pia, arachnoid, or ependyma on enhanced MR had evidence of leptomeningeal or ependymal disease based on clinical or laboratory data. However, we do not propose that a normal enhanced MR examination absolutely excludes meningeal disease. Other investigators have described normal enhanced MR scans of the brain and spine in patients with cytologically proved leptomeningeal disease; presumably this could also occur intracranially with either neoplasia or infection [10] (Yousem DM, Grossman RI, presented at the annual meeting of the Radiological Society of North America, November 1989). Rather, the appearance of the dura, leptomeninges, and ependyma on enhanced MR scans complements the clinical examination and CSF findings.

Our current technique in this patient population includes a T2-weighted axial sequence and an unenhanced T1-weighted sequence through the surgical site and prior tumor bed. We then repeat the T1-weighted sequence immediately after the administration of contrast material. Most patients undergo at least one additional T1-weighted sequence in another plane. If a patient has a tumor with a known propensity for metastasis to the leptomeninges, the entire brain is scanned after enhancement.

Conclusions

Mild focal or diffuse dural enhancement is a normal finding on enhanced MR in the pediatric patient who has undergone biopsy, craniotomy, or intraventricular shunt placement for an intracranial neoplasm or associated hydrocephalus. Benign-appearing meningeal enhancement was noted on some scans obtained 8 or more years after surgery. Prior radiation therapy did not appear to increase the prevalence or degree of meningeal enhancement. Moderate dural enhancement may occur in clinically well patients with postsurgical subdural collections or when there is a history of remote serious meningeal disease such as a subarachnoid hemorrhage or meningitis. Nodular dural enhancement, leptomeningeal enhancement, or ependymal enhancement were patterns not seen in our clinically well postsurgical group of patients. On the basis of our small population of patients who exhibited such enhancement, these patterns of enhancement may suggest serious disease, such as leptomeningeal tumor, residual tumor, or meningitis. Finally, enhanced T1-weighted sequences and careful contrast administration techniques are essential for optimal use of enhanced MR in the postoperative pediatric patient.

REFERENCES

1. Kucharczyk W, Brant-Zawadzki M, Sobel D, et al. Central nervous system tumors in children: detection by magnetic resonance imaging. *Radiology* **1985**;155:131-136
2. Lee BCP, Kneeland JB, Deck MDF, Cahill PT. Posterior fossa lesions: magnetic resonance imaging. *Radiology* **1984**;153:137-143
3. Smith AS, Weinstein MA, Modic MT, et al. Magnetic resonance with marked T2-weighted images: improved demonstration of brain lesions, tumor, and edema. *AJNR* **1985**;6:691-697
4. Hasso AN, Fahmy JL, Hinshaw DB. Tumors of the posterior fossa. In: Stark DD, Bradley WG, eds. *Magnetic resonance imaging*. St. Louis: Mosby, **1988**:425-427
5. Elster AD, Rieser GD. Gd-DTPA-enhanced cranial MR imaging in children: initial clinical experience and recommendations for its use. *AJNR* **1989**;10:1027-1030
6. Brant-Zawadzki M, Berry I, Osaki L, Brasch R, Murovic J, Norman D. Gd-DTPA in clinical MR of the brain: 1. Intraaxial lesions. *AJNR* **1986**;7:781-788
7. Berry I, Brant-Zawadzki M, Osaki L, Brasch R, Murovic J, Newton TH. Gd-DTPA in clinical MR of the brain: 2. Extraaxial lesions and normal structures. *AJNR* **1986**;7:789-793
8. Mathews VP, Kuharik MA, Edwards MK, D'Amour PG, Azzarelli B, Dreesen RG. Gd-DTPA-enhanced MR imaging of experimental bacterial meningitis: evaluation and comparison with CT. *AJNR* **1988**;9:1045-1050
9. Sze G, Abramson A, Krol G, et al. Gadolinium-DTPA in the evaluation of intradural extramedullary spinal disease. *AJNR* **1988**;9:153-163
10. Sze G, Soletsky S, Bronen R, Krol G. MR imaging of the cranial meninges with emphasis on contrast enhancement and meningeal carcinomatosis. *AJNR* **1989**;10:965-975
11. Frank JA, Girton M, Dwyer AJ, Wright DC, Cohen PJ, Doppman JL. Meningeal carcinomatosis in the VX2 rabbit tumor model: detection with Gd-DTPA-enhanced MR imaging. *Radiology* **1988**;167(3):825-829
12. Berns DH, Blaser S, Ross JS, Masaryk TJ, Modic MT. MR imaging with Gd-DTPA in leptomeningeal spread of lymphoma. *J Comput Assist Tomogr* **1988**;12(3):499-500
13. Elster AD, DiPersio DA. Cranial postoperative site: assessment with contrast-enhanced MR imaging. *Radiology* **1990**;174:93-98
14. Burke JW, Podrasky AE, Bradley WG. Meninges: benign postoperative enhancement on MR images. *Radiology* **1990**;174:99-102
15. Destian S, Heier LA, Zimmerman RD, Morgello S, Deck MDF. Differentiation between meningeal fibrosis and chronic subdural hematoma after ventricular shunting: value of enhanced CT and MR scans. *AJNR* **1989**;10:1021-1026
16. Sage MR. Blood-brain barrier: phenomenon of increasing importance to the imaging clinician. *AJNR* **1982**;3(2):127-138
17. Kilgore DP, Breger RK, Daniels DL, Pojunas KW, Williams AL, Haughton VM. Cranial tissues: normal MR appearance after intravenous injection of Gd-DTPA. *Radiology* **1986**;160:757-761
18. Burger PC, Vogel FS. *Surgical pathology of the nervous system and its coverings*, 2nd ed. New York: Wiley, **1982**:153-156
19. Kun LE. The brain and spinal cord. In: Moss WT, Cox JD, eds. *Radiation oncology. Rationale, technique, results*. St. Louis: Mosby, **1989**:597
20. Marty R, Cain ML. Effects of corticosteroid (dexamethasone) administration on the brain scan. *Radiology* **1973**;107:117-121
21. Laster DW, Moody DM, Ball MR. Resolving intracerebral hematoma: alteration of the "ring sign" with steroids. *AJR* **1978**;130:935-939
22. Eisenberg HM, Barlow CF, Lorenzo AV. Effect of dexamethasone on altered brain vascular permeability. *Arch Neurol* **1970**;23:18-22
23. Sears ES, Tindall RSA, Zarnow H. Active multiple sclerosis. Enhanced computerized tomographic imaging of lesions and the effect of corticosteroids. *Arch Neurol* **1978**;35:426-434