

Are your **MRI contrast agents** cost-effective?

Learn more about generic **Gadolinium-Based Contrast Agents**.



**FRESENIUS
KABI**

caring for life

AJNR

CT and MR of meningeal melanocytoma.

L G Naul, J H Hise, S C Bauserman and F D Todd

AJNR Am J Neuroradiol 1991, 12 (2) 315-316

<http://www.ajnr.org/content/12/2/315.citation>

This information is current as
of April 18, 2024.

CT and MR of Meningeal Melanocytoma

L. Gill Naul,¹ Joseph H. Hise,¹ S. C. Bauserman,² and F. D. Todd³

The majority of melanotic neoplasms of the CNS are metastatic in origin. Rarely, a primary CNS melanoma arises from the leptomeninges, which in certain regions normally contain melanocytic cells [1]. These primary neoplasms are usually histologically and clinically malignant [2]. The meningeal melanocytoma is at the benign end of the spectrum of primary melanotic neoplasms and is less common than its malignant counterparts [2]. In this article we describe a patient with a meningeal melanocytoma adjacent to the foramen magnum. We report clinical, surgical, CT, and MR findings, as well as the pathologic features revealed by immunohistochemistry and electron microscopy.

Case Report

A 68-year-old woman presented with a 6-week history of suboccipital headaches, dizziness, nausea, vomiting, and difficulty walking. Physical examination revealed a quadriparesis with hyperreflexia of all four extremities. A CT scan demonstrated a dense, well-circumscribed, extraaxial, 3-cm mass in the inferior aspect of the posterior fossa posteriorly, which enhanced in a homogeneous fashion after IV administration of iodinated contrast material (Fig. 1A). MR imaging revealed the mass to be isointense with the adjacent normal brain tissue on images from all pulse sequences and hypointense relative to brain and most other brain neoplasms on T2-weighted images, 2000/100/2 (TR/TE/excitations) (Figs. 1B and 1C). The mass also enhanced homogeneously after IV injection of gadopentetate dimeglumine (Fig. 1D). Angiography revealed the mass to be hypovascular with displacement of the surrounding vessels. Findings were thought to represent a foramen magnum meningioma. At surgery, an extraaxial gray neoplasm was removed without difficulty. Intraoperative frozen sections were consistent with an atypical meningioma.

Microscopic examination of the permanent sections revealed spindle- and epithelioid-appearing cells containing scattered areas of cytoplasmic pigment deposition consistent with melanin (Fig. 1E). There was no necrosis or significant mitotic activity. Electron microscopy revealed premelanosomes and melanosomes in the cytoplasm of some cells (Fig. 1F). The electron microscopy as well as the immunohistochemistry (positive S-100 and HMB-45) suggested a melanotic origin for the neoplasm. The lack of significant mitotic activity or other anaplastic features was consistent with a meningeal melanocytoma.

Following the pathologic diagnosis of a melanocytic neoplasm, careful examination of the patient failed to reveal any suspicious skin or eye lesions. A follow-up examination 10 months after surgery showed no evidence of recurrence or metastatic disease.

Discussion

The leptomeninges normally contain widely distributed pigmented cells that are most numerous about the ventral portions of the brainstem and spinal cord [3]. Although the majority of CNS melanotic tumors are metastatic in origin, primary tumors occasionally arise from pigmented cells in the leptomeninges [4]. The majority of these primary neoplasms are malignant, with about 25% associated with neurocutaneous melanosis syndrome [2]. The meningeal melanocytoma is a benign variant arising from the pigmented cells of the leptomeninges. As expected, the majority of the reported melanocytomas have been located at the base of the brain and in the spinal canal [5]. In 1987, Winston et al. [5] reported a case of meningeal melanocytoma and reviewed the literature. At that time, only 11 cases were thought to definitely represent meningeal melanocytoma. Of these, four were intracranial, six were primarily spinal, and one was at the level of the foramen magnum, similar to our case. Only one of these cases was evaluated by MR. However, the MR characteristics of the tumor were not described in this case. Other primary intracranial neoplasms—including meningiomas, schwannomas, ependymomas, choroid plexus papillomas, and medulloblastomas—occasionally contain melanin pigment [2]. However, these neoplasms are not composed of cells of melanocytic origin [2]. Analogy to ocular melanocytoma seems most appropriate in terms of biologic behavior morphology.

This case is interesting in that the appearance of the neoplasm is compatible with a meningioma on both the CT and MR scans. A large percentage of meningiomas are isointense or hypointense relative to normal brain tissue on the T2-weighted MR images [6]. Recently it has been shown that other neoplasms—including metastatic melanoma, metastatic adenocarcinoma, metastatic prostatic carcinoma, met-

Received July 19, 1990; revision requested August 14, 1990; revision received September 17, 1990; accepted September 18, 1990.

¹ Department of Radiology, Scott and White Clinic, 2401 S. 31st St., Temple, TX 76508. Address reprint requests to L. G. Naul

² Department of Pathology, Scott and White Clinic, Temple, TX 76508.

³ Department of Surgery, Division of Neurosurgery, Scott and White Clinic, Temple, TX 76508.

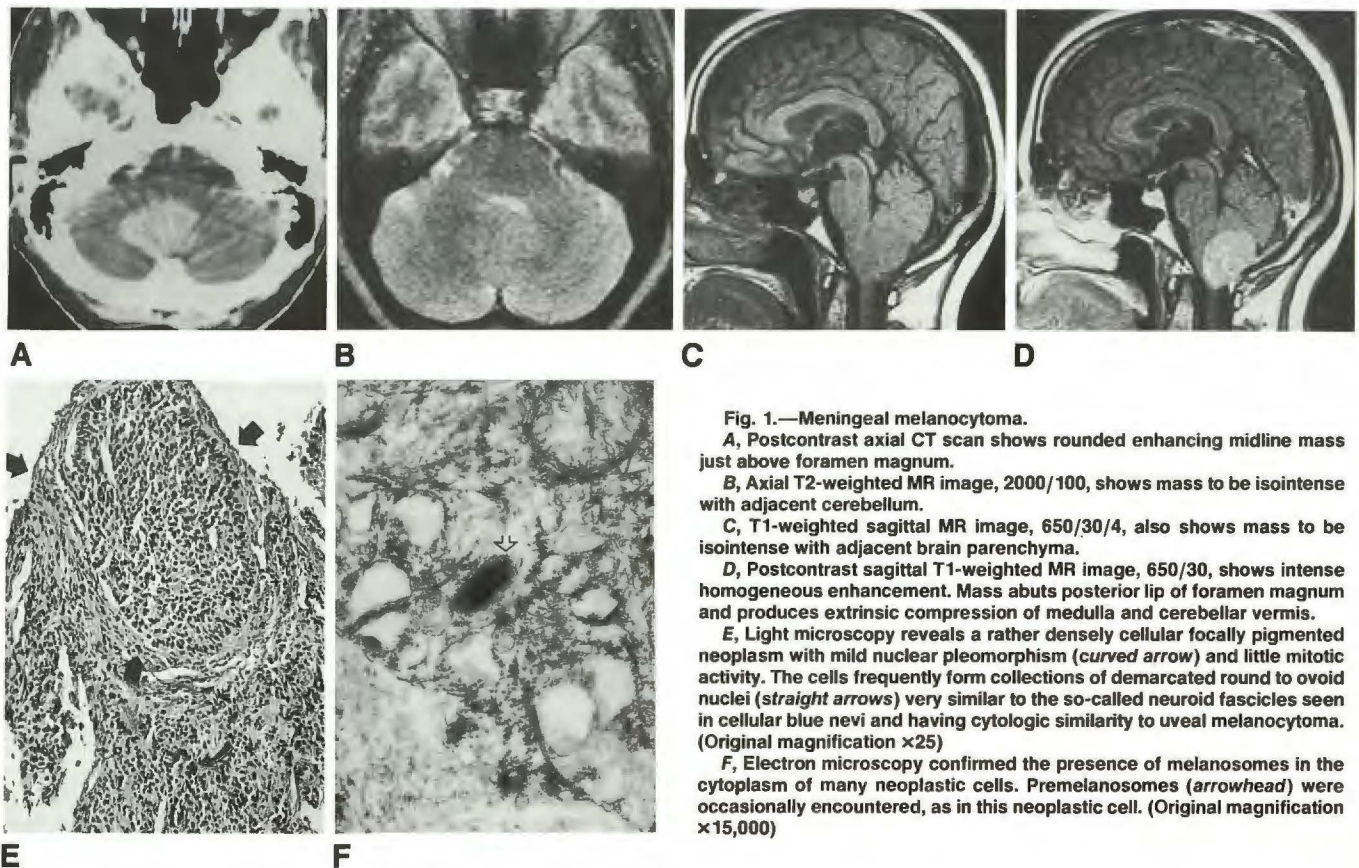


Fig. 1.—Meningeal melanocytoma.

A, Postcontrast axial CT scan shows rounded enhancing midline mass just above foramen magnum.

B, Axial T2-weighted MR image, 2000/100, shows mass to be isointense with adjacent cerebellum.

C, T1-weighted sagittal MR image, 650/30/4, also shows mass to be isointense with adjacent brain parenchyma.

D, Postcontrast sagittal T1-weighted MR image, 650/30, shows intense homogeneous enhancement. Mass abuts posterior lip of foramen magnum and produces extrinsic compression of medulla and cerebellar vermis.

E, Light microscopy reveals a rather densely cellular focally pigmented neoplasm with mild nuclear pleomorphism (curved arrow) and little mitotic activity. The cells frequently form collections of demarcated round to ovoid nuclei (straight arrows) very similar to the so-called neuroid fascicles seen in cellular blue nevi and having cytologic similarity to uveal melanocytoma. (Original magnification $\times 25$)

F, Electron microscopy confirmed the presence of melanosomes in the cytoplasm of many neoplastic cells. Premelanosomes (arrowhead) were occasionally encountered, as in this neoplastic cell. (Original magnification $\times 15,000$)

astatic osteosarcoma, medulloblastoma, and lymphoma—can exhibit similar signal characteristics [7]. The lack of characteristic hyperintensity on T2-weighted MR images exhibited by most other CNS neoplasms has been theorized to be due to their very cellular or fibrous nature and resulting diminished water content, paramagnetism, susceptibility effects, or possibly hemorrhage [7]. Some melanotic lesions have been noted to be hypointense on the T2-weighted MR images, which has been attributed to the paramagnetic effects of melanin or associated hemorrhage [8]. In our case, this particular signal characteristic was probably related to either the fibrous nature of the neoplasm or the paramagnetic effects of melanin.

In summary, we have described a rare neoplasm with radiologic features similar to those of a meningioma. Although unusual, meningeal melanocytoma should be added to the expanding list of intracranial neoplasms that are isointense on T1-weighted MR images and isointense or hypointense on T2-weighted images.

REFERENCES

1. Limas C, Tio FO. Meningeal melanocytoma ("melanotic meningioma"). Its melanocytic origin as revealed by electron microscopy. *Cancer* 1972;30:1286-1294
2. Russell DS, Rubinstein LN. *Pathology of tumours of the nervous system*. Baltimore: Williams & Wilkins, 1989;794-797
3. Pappenheim E, Bhattacharji SK. Primary melanoma of the central nervous system. Clinical-pathological report of a case, with survey and discussion of the literature. *Arch Neurol* 1962;7:101-113
4. Abbott M, Killeffer FA, Crandall PH. Melanotic meningioma. Case report. *J Neurosurg* 1968;29:283-286
5. Winston KR, Sotrel A, Schnitt SJ. Meningeal melanocytoma. Case report and review of the clinical and histological features. *J Neurosurg* 1987;66:50-57
6. Zimmerman RD, Fleming CA, Saint-Louis LA, Lee BCP, Manning JJ, Deck MDF. Magnetic resonance imaging of meningiomas. *AJNR* 1985;6:149-157
7. Pomeranz SJ. MR of supratentorial neoplasia. In: Pomeranz SJ, ed. *Craniospinal magnetic resonance imaging*. Philadelphia: Saunders, 1989:208-247
8. Weindling SM, Press GA, Hesselink JR. MR characteristics of a primary melanoma of the quadrigeminal plate. *AJNR* 1988;9:214-215