

Are your **MRI contrast agents** cost-effective?

Learn more about generic **Gadolinium-Based Contrast Agents**.



FRESENIUS
KABI

caring for life

AJNR

Epidural pneumatosis: a benign entity in trauma patients.

S J Willing

AJNR Am J Neuroradiol 1991, 12 (2) 345

<http://www.ajnr.org/content/12/2/345.citation>

This information is current as
of April 20, 2024.

Epidural Pneumatosis: A Benign Entity in Trauma Patients

Air may be visualized in the spinal epidural space in a variety of settings. Pathologic collections of air from herniated vacuum disk and epidural abscess have been described [1, 2]. Iatrogenic air may result from epidural anesthesia or unsuccessful lumbar puncture. Intraspinous air (pneumorrhachis) after trauma has been considered a rare occurrence; only three cases have been reported in the literature. In one case, air was found in the thoracic spine after a fracture dislocation of L2 with jejunal perforation [3]; in the second case, air was seen in the cervical spine in association with a pneumothorax [4]. In the third case, subarachnoid air extended from a traumatic pneumocephalus [5]. In other instances, pneumorrhachis would suggest an open or penetrating spinal injury. Epidural air directly resulting from a pneumomediastinum has not been reported before. Three cases are described here.

Case Reports

The first patient is a 34-year-old man who had multiple fractures of the left ribs, hemothorax, and multiple fractures of the extremities after a motor vehicle accident. Chest CT performed to assess the mediastinum showed subcutaneous emphysema and a pneumomediastinum. CT of the cervical spine showed air in the epidural space and paravertebral soft tissues (Fig. 1). The patient was neurologically normal at the time of admission and throughout his hospital stay. The second patient, a 19-year-old man, was found at the scene of a motor vehicle accident. He was unconscious, and his systolic blood pressure was 80 mm Hg. On arrival at the emergency room he was intubated. His score on the Glasgow Coma Scale was 6; he moved only his left side in a nonpurposeful manner. Injuries included splenic rupture, a severe liver laceration, and pulmonary and cardiac contusions. Cranial CT showed a contusion of the left frontal lobe and intraventricular hemorrhage. A thoracic CT scan obtained on the 11th day because of persistent fever showed a pneumomediastinum, subcutaneous emphysema, and air in the epidural space (Fig. 2). The patient was discharged on the 40th day with a moderate cognitive deficit and mild right-sided hemiparesis. The third patient was a 28-year-old man who had a left-sided flail chest, pneumothorax, and splenic laceration after a motor vehicle accident. He was unconscious at the scene but was alert and without neurologic deficits on arrival at the hospital. CT of the head was normal. CT of the pelvis performed to assess the acetabula showed air in the lumbar epidural space. All three patients had normal spinal radiographs.

Discussion

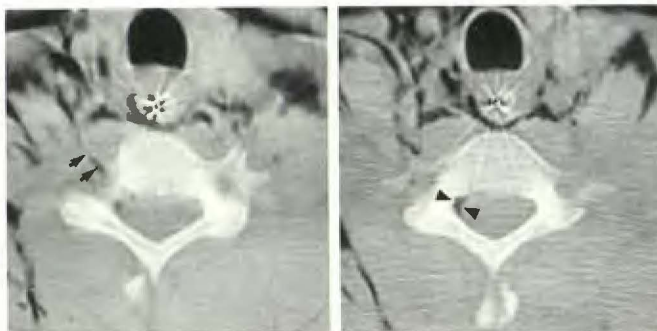
No fascial boundaries prevent communication of the posterior mediastinum or retropharyngeal space with the epidural space via the neural foramina. If a pneumomediastinum is present, air may dissect through the neural foramina into the epidural space, as shown in the first case. These three cases shared several common features: (1) all had major thoracic trauma: flail chest in two and cardiopulmonary contusion in the third; (2) the pneumomediastinum was substantial, with extensive subcutaneous emphysema; (3) the amount of epidural air was small; (4) the air was recognized only on CT; and (5) the air was an incidental finding in two patients whose scans were performed for indications unrelated to the spine. No neurologic abnormalities referable to the spine developed in any of these patients. It is possible that nontraumatic pneumomediastinum also could result in intraspinal air; however, such patients seldom have CT scanning, and no such cases have been documented.

In conclusion, epidural pneumatosis is a benign occurrence seen occasionally in trauma patients and is the result of direct dissection of a pneumomediastinum. It may be found anywhere along the spinal axis. Epidural air in a trauma patient might suggest an open or penetrating spinal injury or prompt a fruitless search for occult calvarial injuries. Satisfaction of the aforementioned criteria should permit the diagnosis of benign pneumatosis.

Steven J. Willing
University of Alabama at Birmingham
Birmingham, AL 35233

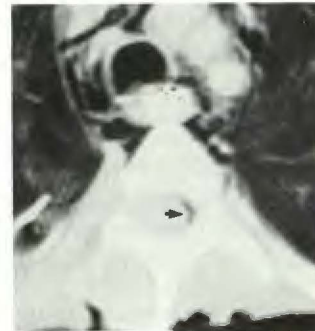REFERENCES

1. Kirzner H, Oh Y, Lee S. Intraspinous air: a CT finding of epidural abscess. *AJR* 1988;151:1217-1218
2. Jamison M, Stanworth P, MacLennan I. An unusual rectal fistula: extradural abscess discharging per rectum. *Br J Surg* 1984;71:651-652
3. Silver S, Nadel H, Flodmark O. Pneumorrhachis after jejunal entrapment caused by a fracture dislocation of the lumbar spine. *AJR* 1988;150:1129-1130
4. Place JN, Pezzuti RT. Clinical significance of traumatic pneumorrhachis (letter). *AJR* 1989;153:655
5. Newbold RG, Wiener MD, Vogler JB, Martinez S. Traumatic pneumorrhachis. *AJR* 1987;148:615-616



1A

1B



2

Fig. 1.—A and B, CT scans show cervical and retropharyngeal emphysema with linear air collection in right C6-C7 neural foramen (arrows, A) and air in epidural space at C7 (arrowheads, B).

Fig. 2.—CT scan shows pneumomediastinum and air in epidural space (arrow).