AJNR

Chemical-shift imaging of a spontaneous internal carotid artery dissection: case report.

R Pacini, J Simon, L Ketonen, D Kido and K Kieburtz

AJNR Am J Neuroradiol 1991, 12 (2) 360-362
http://www.ajnr.org/content/12/2/360.citation

Chemical-Shift Imaging of a Spontaneous Internal Carotid Artery Dissection: Case Report

Richard Pacini,[1] Jack Simon,[1] Lena Ketonen,[2] Daniel Kido,[2] and Karl Kieburtz[2]

The clinical and angiographic manifestations of spontaneous dissection of the internal carotid artery (SDICA) have been described in the literature [1–7]. Several reports have discussed the utility of MR in the diagnosis and follow-up of SDICA [4, 8–10]. This case demonstrates the direct visualization of an SDICA, the extension of the SDICA during the course of therapy, and the increased sensitivity and specificity gained through the use of a lipid-suppression chemical shift imaging (CSI) method for evaluating SDICA.

Case Report

MR images were acquired at 1.5 T (Signa, GE Medical Systems, Milwaukee, WI) using conventional T1- and T2-weighted sequences, as well as CSI lipid-suppressed views using the technique described by Szumowski et al. [11], consisting of a preparatory frequency-selective 1331 pulse followed by Chopper fat suppression [12].

A previously healthy 46-year-old man developed a sudden onset of vague abdominal discomfort and nausea while sitting at his desk. On arising, he noted heaviness and weakness in the right arm and leg, worsening over several minutes. En route to the hospital, he developed blurred vision in the left eye. On evaluation in the emergency room, he had difficulty finding his words but no difficulty understanding when spoken to. All symptoms resolved over a period of 90 min. His history was negative for neck trauma, hypertension, diabetes, or cardiovascular disease. On physical examination, carotid pulses were symmetric and 2+, without bruits. Neurologic examination revealed decreased right arm swing and an upgoing right toe.

The day after admission, both a head CT and duplex Doppler examination of the carotid arteries were normal. An angiogram on the second day demonstrated a severe 2-cm long stenosis of the

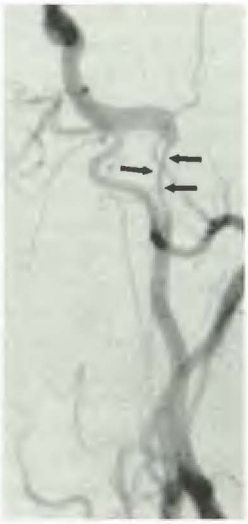

Fig. 1.—Anteroposterior view of left common carotid injection. Note severe narrowing of internal carotid artery proximal to base of skull (*arrows*).

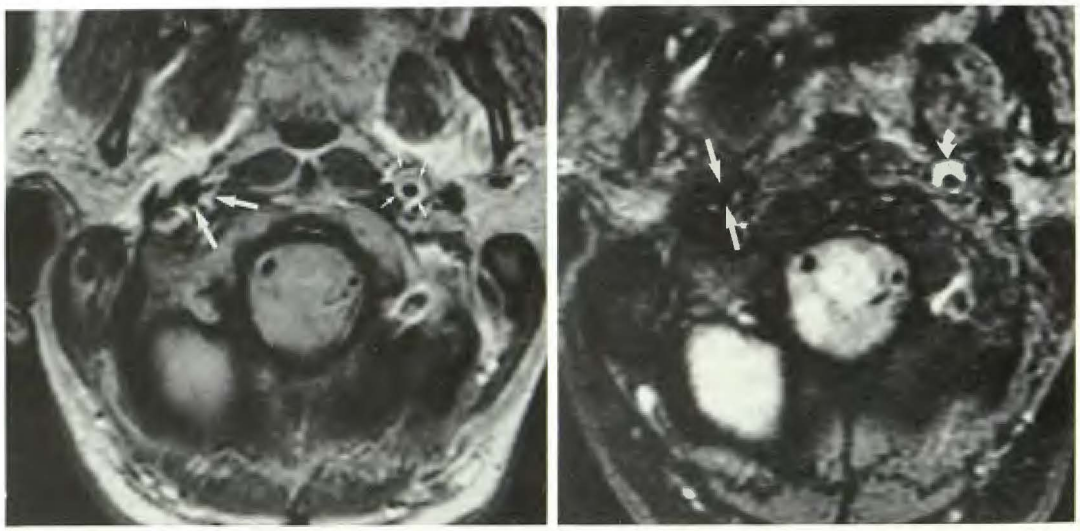

A B

Fig. 2.—*A* and *B*, MR images acquired day of angiography. Conventional SE image 2000/30/1 (*A*) and CSI image 2000/30/2 (*B*). A circumferential ring of increased signal surrounds lumen of left internal carotid artery (ICA) (*small arrows* in *A*). Similar though less extensive increased signal partially encircles normal right ICA (*large arrows* in *A*). CSI images separate suppressible fat from thrombus (*curved arrow* in *B*) in left ICA, and confirm a normal right ICA (*straight arrows* in *B*).

Received April 4, 1990; revision requested May 9, 1990; revision received October 22, 1990; accepted October 24, 1990.

[1] Department of Radiology, University of Colorado Health Sciences Center, Box A-034, 4200 E. Ninth Ave., Denver, CO 80262. Address reprint requests to J. Simon.

[2] Department of Radiology, University of Rochester Medical Center, Rochester, NY 14642.

 0195–6108/91/1202–0360

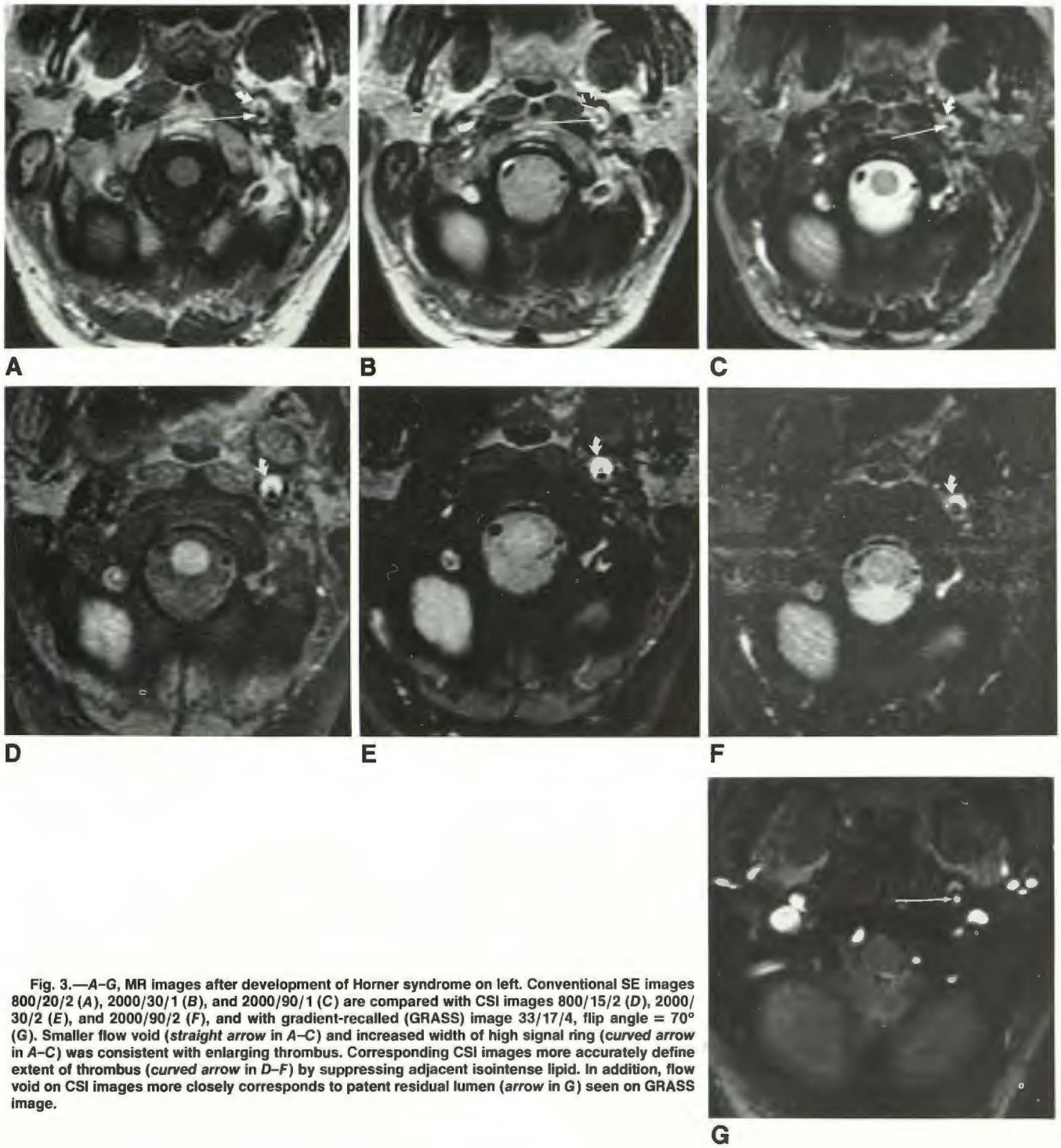

Fig. 3.—*A–G*, MR images after development of Horner syndrome on left. Conventional SE images 800/20/2 (*A*), 2000/30/1 (*B*), and 2000/90/1 (*C*) are compared with CSI images 800/15/2 (*D*), 2000/30/2 (*E*), and 2000/90/2 (*F*), and with gradient-recalled (GRASS) image 33/17/4, flip angle = 70° (*G*). Smaller flow void (*straight arrow* in *A–C*) and increased width of high signal ring (*curved arrow* in *A–C*) was consistent with enlarging thrombus. Corresponding CSI images more accurately define extent of thrombus (*curved arrow* in *D–F*) by suppressing adjacent isointense lipid. In addition, flow void on CSI images more closely corresponds to patent residual lumen (*arrow* in *G*) seen on GRASS image.

high cervical left internal carotid artery, thought to be a dissection (Fig. 1). MR imaging was done to confirm the diagnosis, to search for associated focal ischemic lesions, and to serve as a baseline for future studies. It demonstrated high signal intensity inseparable from the vessel wall on the T1- and T2-weighted images, corresponding to the angiographic-demonstrated stenosis (Fig. 2A). The margins, nature, and extent of the high signal lesion were seen better on the CSI series (Fig. 2B), which allowed an unequivocal separation of lipid (suppressible) from presumed subacute hemorrhage (nonsuppressed).

The patient was placed on IV heparin for presumed SDICA. On the second day of treatment, with a partial thromboplastin time in the therapeutic range, the patient developed left miosis and ptosis. Repeat duplex Doppler studies (and oculoplethysmography) showed reversal of flow in the ophthalmic artery but no abnormality of the visualized portion of the left ICA. Repeat MR performed the following

day (7 days after admission) demonstrated extension of mural and/or intraluminal blood clot into the carotid canal and proximal carotid siphon as well as increasing thickness of the abnormal high signal (Fig. 3). On the basis of the new clinical and MR findings, heparin was discontinued. The patient was placed on aspirin therapy and was discharged with stable residual decreased right arm swing and a questionable upgoing right toe. Three months later, a follow-up MR examination demonstrated nearly complete resolution of the abnormal periluminal high signal and only mild residual stenosis of the left ICA.

Discussion

Spontaneous dissection of the internal carotid artery is an uncommon but not rare event that is recognized as a cause of stroke in younger adults [1, 3–6]. It typically presents in the second to fifth decade with acute transient or, less commonly, persistent neurologic deficits. A diagnosis of SDICA is suggested by associated ipsilateral focal (usually frontal) headache, oculosympathetic paresis (Horner syndrome), and neck pain [1, 3–6, 13]. However, in some patients the symptoms can be minor. The prognosis is debated in the literature. A good functional outcome has been associated with early reopening of the occluded dissection [1].

Several case reports have emphasized the utility of MR in the diagnosis and follow-up of this entity [4, 8–10]. Duplex sonography with oculoplethysmography is sensitive to atherosclerotic disease of the carotids [14] but its sensitivity to SDICA is likely to be compromised by the usual high cervical location beyond the reach of direct visualization. Doppler signals in the proximal ICA may indicate flow reduction at a more cephalad level but this finding is not without significant problems in interpretation [14]. If MR proves to be sensitive to SDICA, then it may become a good initial screening test for patients with features suggestive of the syndrome.

We report a case in which MR noninvasively diagnosed an extension of a high ICA dissection when duplex sonography/oculoplethysmography findings were equivocal. The patient's treatment was influenced by the MR findings; there was no need to repeat angiography.

One of the potential limitations of MR in the neck and skull base is the suboptimal detection of high signal lesions on T1-weighted images (e.g., methemoglobin, Gd-chelates), which appear similar to normal lipids [15]. The CSI approach retains the advantages of MR for anatomic resolution and physiological information (flow) but in addition provides increased chemical characterization (methemoglobin versus lipid). Another advantage of the CSI method is minimization of chemical shift misregistration artifacts, which may obscure fine detail in small structures such as vessels surrounded by normal lipids. Despite the decreasing signal intensity of lipid with increasing T2 weighting, significant signal does persist (Fig. 3F). CSI methods better suppress this signal on all echoes, eliminating the need for prolonged echo times to achieve lipid suppression [16].

This case demonstrates the increased sensitivity to dissection and improved definition of lesion margins by using a lipid-suppression technique. With the increasing availability of lipid-suppression techniques on commercial MR instruments, this will likely prove to be a helpful adjunct in the diagnosis and management of spontaneous dissection of the internal carotid artery.

REFERENCES

1. Bogousslavsky J, Despland PA, Regli F. Spontaneous carotid dissection with acute stroke. *Arch Neurol* **1987**;44:137–140
2. Davies L. A case of vagal palsy due to dissecting aneurysm of the carotid artery. *Med J Aust* **1987**;147:352–353
3. Houser OW, Mokri B, Sundt TM, Baker HL, Reese DF. Spontaneous cervical cephalic arterial dissection and its residuum: angiographic spectrum. *AJNR* **1984**;5:27–34
4. Lieschke GJ, Davis S, Tress BM, Ebeling P. Spontaneous internal carotid artery dissection presenting as hypoglossal nerve palsy. *Stroke* **1988**;9:1151–1155
5. Mokri B, Sundt TM, Houser OW, Piepgras DG. Spontaneous dissection of the cervical internal carotid artery. *Ann Neurol* **1986**;19:126–138
6. Petro GR, Witwer GA, Cacayorin ED, et al. Spontaneous dissection of the cervical internal carotid artery: correlation of arteriography, CT, and pathology. *AJNR* **1986**;7:1053–1058
7. Sellier N, Chiras J, Benhamou M, et al. Dissections spontanees de la carotide interne: aspects cliniques, radiologiques et evolutifs: a propos de 46 cas. *J Neuroradiol* **1983**;10:243–259
8. Alvarez O, Edwards JH, Hyman RA. MR recognition of internal carotid artery occlusion. *AJNR* **1986**;7:359–360
9. Goldberg HI, Grossman RI, Gomori JM, Asbury AK, Bilaniuk LT, Zimmerman RA. Cervical internal carotid artery dissecting hemorrhage: diagnosis using MRI. *Radiology* **1986**;158:157–161
10. Rothrock JF, Lim V, Press G, Gosink B. Serial magnetic resonance and carotid duplex examinations in the management of carotid dissection. *Neurology* **1989**;39:686–692
11. Szumowski J, Eisen JE, Vinitski S, Haake PW, Plewes DB. Hybrid methods of chemical-shift imaging. *Magn Reson Med* **1989**;9:379–388
12. Szumowski J, Plewes DB. Separation of lipid and water MR imaging signals by chopper averaging in the time domain. *Radiology* **1987**;165:247–250
13. Kline BL, Vitek J, Raymon BC. Painful Horner's syndrome due to spontaneous carotid artery dissection. *Ophthalmology* **1987**;94:226–230
14. Castaldo JE, Nicholas GG, Gee W, Reed JF. Duplex ultrasound and ocular pneumoplethysmography concordance in detecting severe carotid stenosis. *Arch Neurol* **1989**;46:518–522
15. Simon JH, Szumowski J. Chemical shift imaging with paramagnetic contrast material enhancement for improved lesion depiction. *Radiology* **1989**;171:539–543
16. Simon JH, Szumowski J, Totterman S, et al. Fat-suppression MR imaging of the orbit. *AJNR* **1988**;9:961–968