

Are your **MRI contrast agents** cost-effective?

Learn more about generic **Gadolinium-Based Contrast Agents**.



FRESENIUS
KABI

caring for life

AJNR

Growth of a thrombosed giant vertebral artery aneurysm after parent artery occlusion.

S T Hecht, J A Horton and H Yonas

AJNR Am J Neuroradiol 1991, 12 (3) 449-451

<http://www.ajnr.org/content/12/3/449.citation>

This information is current as
of April 17, 2024.

Growth of a Thrombosed Giant Vertebral Artery Aneurysm After Parent Artery Occlusion

Stephen T. Hecht,^{1,2} Joseph A. Horton,¹ and Howard Yonas¹

Parent artery ligation is an accepted treatment for intracranial aneurysms that are not amenable to a direct surgical approach. Parent artery ligation is one of the oldest effective surgical means of aneurysm therapy (the "Hunterian principle" [1]). Recently it has become possible to perform parent artery occlusion of the carotid or vertebral artery percutaneously by using detachable balloon technology [2–5]. We report a case of a patient with a vertebral artery giant aneurysm, which was treated by parent artery occlusion of the vertebral artery, resulting in thrombosis of the aneurysm. In spite of thrombosis of the aneurysm and the parent artery, the aneurysm continued to grow.

This case suggests that giant aneurysm growth is not always dependent on pulsatile blood flow as a driving force, and that recurrent mural hemorrhage into the highly vascularized aneurysm wall is a more likely mechanism. Giant aneurysms can be unstable lesions even when they (and their parent arteries) are thrombosed. Continued surveillance with CT and/or MR imaging is prudent following thrombosis of giant aneurysms by parent artery occlusion.

Case Report

A 78-year-old woman who was congenitally deaf bilaterally presented with progressive ataxia. She had no focal neurologic deficits on initial presentation except a severe bilateral eighth cranial nerve deficit. CT without and with IV contrast administration demonstrated a bilobed giant aneurysm in the right cerebellopontine angle (Fig. 1A). The posterior component did not enhance (except for peripheral, ring enhancement) and was presumably thrombosed. The anterior component enhanced markedly after IV contrast administration, suggesting that it was patent. A right vertebral arteriogram (Figs. 1B and 1C) demonstrated a single patent aneurysm lumen (the anterior component) arising from an acute bend in the right vertebral artery, located proximal to the confluence of the vertebral arteries to form the basilar artery. The absence of angiographic filling of the posterior component confirmed that it was thrombosed. Parent artery occlusion was performed by placement of a detachable silicone balloon (Interventional Therapeutics Corp., So. San Francisco, CA) in the right vertebral artery, proximal to both the aneurysm and the origin of the right

posterior inferior cerebellar artery. A control arteriogram and contrast-enhanced CT scan 1 week after the balloon occlusion demonstrated interval thrombosis of the previously patent aneurysm lumen (Figs. 1D, 1E, and 1F). The patient's symptoms improved substantially after parent artery occlusion.

Ten months later the patient experienced recurrent ataxia. CT with IV contrast enhancement showed that the anterior component was stable in size and appeared thrombosed, but that the posterior component had grown substantially (Fig. 1G). An MR study showed laminations of various stages of blood clot (Figs. 1H and 1I). A cerebral angiogram was not performed during the second admission.

The aneurysm was surgically removed, with the patient hypothermic and in circulatory arrest. After surgery she had an anoxic brain injury, presumably due to the 52-min circulatory arrest. She died of pneumonia 2 months after the surgery. An autopsy was not performed.

Discussion

Despite major advances in surgical treatment of aneurysms, some types of aneurysms remain beyond the grasp of the clip. Giant aneurysms (greater than 2.5 cm in diameter) are among the aneurysms that often cannot be treated successfully by direct surgical attack and therefore may be treated by parent artery ligation [1, 6–9]. Parent artery ligation is one of the older surgical treatments for aneurysms; it is effective in a large percentage of cases. With the development of effective detachable balloon technology, percutaneous parent artery occlusion with detachable balloons presents an alternative to parent artery ligation [2–5, 10, 11]. Balloon occlusion of an artery often can be accomplished without the use of general anesthesia. With an awake patient, the neurologic examination can be continuously monitored during the process of arterial test occlusion and permanent balloon occlusion. The therapeutic effectiveness of parent artery occlusion is similar to that of parent artery ligation.

Thrombosis of a giant aneurysm does not ensure that further growth of the aneurysm will not occur. Spontaneously thrombosed giant aneurysms can grow [12, 13]. The present case in some respects represents another example of growth

Received June 28, 1990; revision requested September 16, 1990; revision received November 9, 1990; accepted November 18, 1990.

¹ Departments of Radiology and Neurological Surgery, University of Pittsburgh, Presbyterian-University Hospital, Pittsburgh, PA 15213.

² Present address: Departments of Radiology and Neurological Surgery, University of California, Davis, 2516 Stockton Blvd., Ticon II, Sacramento, CA 95817. Address reprint requests to S. T. Hecht.

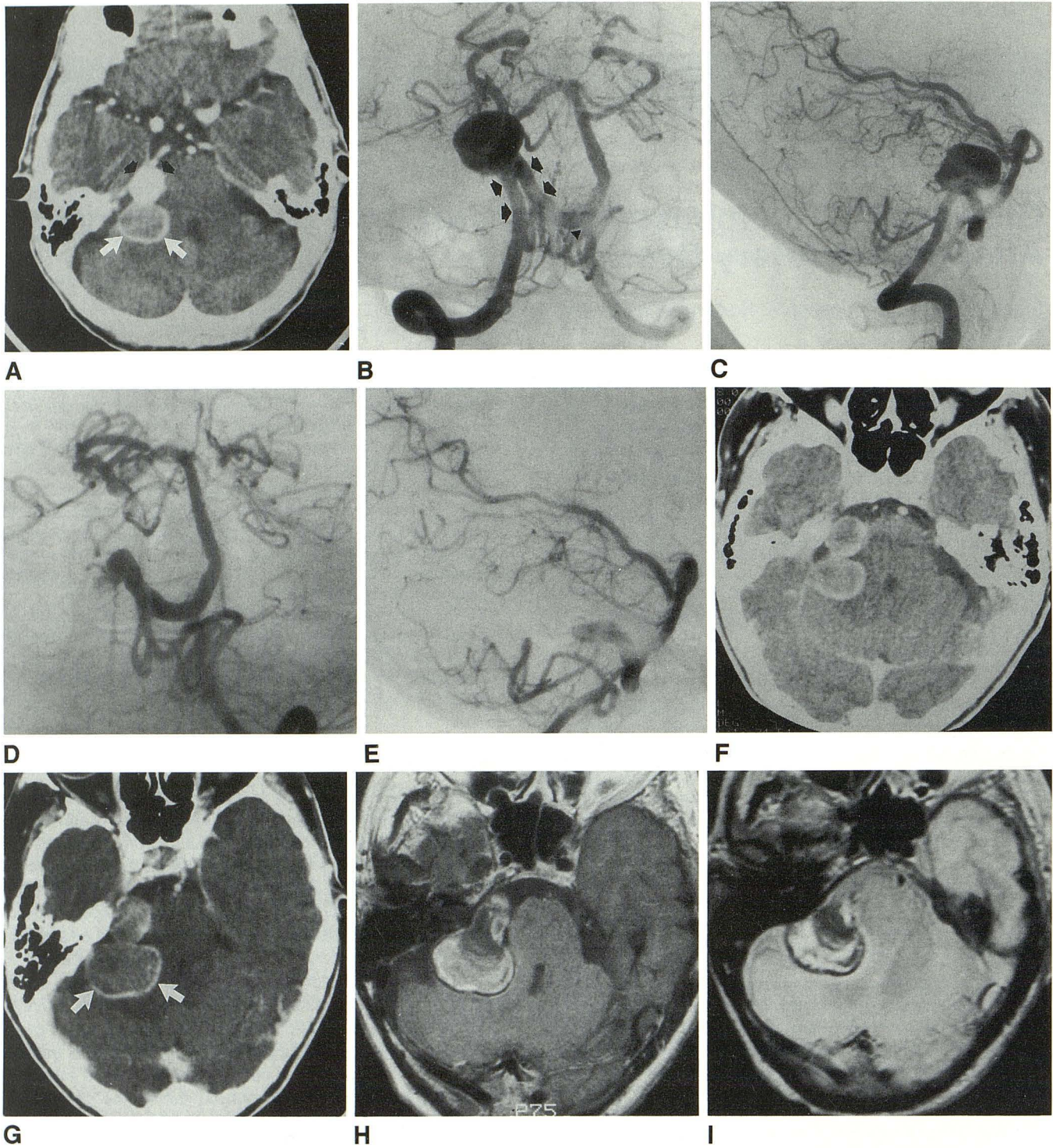


Fig. 1.—78-year-old woman with giant vertebral artery aneurysm.

A, Contrast-enhanced CT scan at time of presentation shows bilobed aneurysm in right cerebellopontine angle cistern. Anterior component (*black arrows*) enhances throughout, indicating patency, and posterior component (*white arrows*) only enhances peripherally in a rim, indicating that it is thrombosed.

B and C, Right vertebral arteriograms, transfacial (B) and lateral (C) projections, at time of presentation. Transfacial projection shows origin of aneurysm from a knuckle of the right vertebral artery (*arrows*). *Arrowhead* indicates confluence of vertebral arteries.

D and E, Left vertebral artery control arteriograms 1 week after balloon occlusion of right vertebral artery, transfacial (D) and lateral (E) projections, show that previously patent aneurysm lumen is nearly completely thrombosed.

F, Contrast-enhanced control CT scan 1 week after balloon occlusion of right vertebral artery shows that nearly complete thrombosis of anterior component has occurred since the previous arteriogram.

G, Contrast-enhanced CT scan 10 months after balloon occlusion of right vertebral artery shows that anterior component of aneurysm is completely thrombosed. Posterior component (which was thrombosed at presentation and remains thrombosed) has grown substantially in the 10-month interval (*arrows*).

H and I, MR images, 651/20 (H) and 2867/30 (I), 10 months after balloon occlusion of right vertebral artery show concentric layers of various intensities, indicating multiple mural hemorrhages of various ages.

of a spontaneously thrombosed giant aneurysm, since the portion of the aneurysm that grew (the posterior component) was completely thrombosed at the time of presentation, prior to parent artery occlusion. The portion of the aneurysm that grew had been occluded for a minimum of 10 months. The unique facet of this case (although not proved by documentation with a follow-up angiogram) is that the parent artery was occluded in addition to the aneurysm itself. If the parent artery were thrombosed, transmitted blood pulsation would be an implausible mechanism for growth of the aneurysm (although it is possible that the contralateral vertebral artery may have filled the residual anterior component lumen). It is doubtful that pulsations transmitted from the patent ipsilateral posterior inferior cerebellar artery played a role in the enlargement of the aneurysm.

What was the growth mechanism of this aneurysm? We believe that the present case supports the mechanism proposed by Schubiger et al. [14] that giant aneurysms have a growth mechanism similar to that of chronic subdural hematomas; they grow by recurrent hemorrhage into their highly vascularized walls. The hyperdense, peripheral, ring-enhancing structures imaged on CT of this and other thrombosed giant aneurysms may represent the hypervascular, membranous wall. The laminated MR appearance of the aneurysm contents represents methemoglobin and hemosiderin resulting from the numerous mural hemorrhages of various ages [15].

As demonstrated by this case, we conclude that giant aneurysms, even when thrombosed either spontaneously or therapeutically, can be unstable lesions and are prone to enlarge. After thrombosis of a giant aneurysm has been induced by parent artery occlusion or ligation, continued CT and/or MR surveillance is prudent.

ACKNOWLEDGMENT

We thank Julian Bailes for providing information regarding this patient's surgical management.

REFERENCES

1. Drake CG. Giant intracranial aneurysms: experience with surgical treatment in 174 patients. *Clin Neurosurg* 1979;26:12-95
2. Debrun G, Fox A, Drake C, Peerless S, Girvin J, Ferguson G. Giant unclippable aneurysms: treatment with detachable balloons. *AJNR* 1981;2:167-173
3. Berenstein A, Ransohoff J, Kupersmith M, Flamm E, Graeb D. Transvascular treatment of giant aneurysms of the cavernous carotid and vertebral arteries: functional investigation and embolization. *Surg Neurol* 1984; 21:3-12
4. Fox AJ, Viñuela F, Pelz DM, et al. Use of detachable balloons for proximal artery occlusion in the treatment of unclippable cerebral aneurysms. *J Neurosurg* 1987;66:40-46
5. Higashida RT, Halbach VV, Dormandy B, Bell JD, Hieshima GB. Endovascular treatment of intracranial aneurysms with a new silicone microballoon device: technical considerations and indications for therapy. *Radiology* 1990;174:687-691
6. Giannotta SL, McGillicuddy JE, Kindt GW. Gradual carotid artery occlusion in the treatment of inaccessible internal carotid artery aneurysms. *Neurosurgery* 1979;5:417-421
7. Swearingen B, Heros RC. Common carotid occlusion for unclippable carotid aneurysms: an old but still effective operation. *Neurosurgery* 1987;3:288-295
8. Sundt TM Jr, Piepgras DG. Surgical approach to giant intracranial aneurysms: operative experience with 80 cases. *J Neurosurg* 1979;51: 731-742
9. Drake CG. Ligation of the vertebral (unilateral or bilateral) or basilar artery in the treatment of large intracranial aneurysms. *J Neurosurg* 1975;43:255-274
10. Serbinenko FA. Balloon catheterization and occlusion of major cerebral vessels. *J Neurosurg* 1974;41:125-145
11. Raymond J, Théron J. Intracavernous aneurysms: treatment by proximal occlusion of the internal carotid artery. *AJNR* 1986;7:1087-1092
12. Artmann H, Vonafakos D, Müller H, Grau H. Neuroradiologic and neuropathologic findings with growing giant intracranial aneurysm: review of the literature. *Surg Neurol* 1984;21:391-401
13. Batjer HH, Purdy PD. Enlarging thrombosed aneurysm of the distal basilar artery. *Neurosurgery* 1990;26:695-700
14. Schubiger O, Valavanis A, Wichmann W. Growth-mechanism of giant intracranial aneurysms: demonstration by CT and MR imaging. *Neuroradiology* 1987;29:266-271
15. Atlas SW, Grossman RI, Goldberg HI, Hackney DB, Bilaniuk LT, Zimmerman RA. Partially thrombosed giant intracranial aneurysms: correlation of MR and pathologic findings. *Radiology* 1987;162:111-114