

Are your **MRI contrast agents** cost-effective?

Learn more about generic **Gadolinium-Based Contrast Agents**.



FRESENIUS
KABI

caring for life

AJNR

Primary spinal echinococcosis causing paraplegia: case report with MR and pathologic correlation.

A Jena, R P Tripathi and A K Jain

AJNR Am J Neuroradiol 1991, 12 (3) 560

<http://www.ajnr.org/content/12/3/560.citation>

This information is current as
of April 20, 2024.

Primary Spinal Echinococcosis Causing Paraplegia: Case Report with MR and Pathologic Correlation

Spinal echinococcosis is rare and occurs most commonly as a direct extension from pulmonary lesions. Isolated spinal hydatidosis caused by hematogenous seeding has not been reported in the literature. We report the first case of a primary echinococcosis that was manifested as acute paraplegia. MR characteristics and their correlation with pathologic and histologic findings are included.

Case Report

A 65-year-old man had a tender soft-tissue swelling in the right paraspinal area at the T10–T11 level and paraplegia of 10 days duration. Chest radiograph showed healed tubercular lesions in the upper right lung. Vertebral bodies and paravertebral areas were reported to be normal. Blood and sputum cultures for acid-fast bacilli were negative. Metrizamide myelography showed a complete block at the T9 level. MR imaging showed a multiloculated cystic mass in the extradural space at T9–T11 on the right side compressing the spinal cord (Fig. 1). Extradural spread of the lesion was seen through a widened right neural foramen at T8–T9 extending into the muscle plane up to the L1 level like a "bunch of grapes." Various amounts of hyperintensity with intervening areas of low intensity were observed in the multiloculated cysts on T2-weighted images.

Surgery for decompression of the thoracic spine showed a multicystic mass containing clear fluid within the cysts. The lesion was localized in the extradural space at T9–T11 and extended into the muscle planes to the L1 level on the right. Gross pathologic and histologic examinations confirmed the diagnosis of hydatid disease. Bronchoscopy done subsequently excluded pulmonary hydatidosis.

Discussion

Transit of echinococcal larvae through hepatic and pulmonary beds during the worm's life cycle makes these organs favored sites for parasitic infection. In rare circumstances (approximately 10% of

cases), the parasites are disseminated to other organs. In 1–2% of cases, the CNS is involved. Extradural compression by hydatid cyst in the spinal canal as a direct spread from pulmonary lesion has been reported [1]. Primary hematogenous seeding of echinococci in the epidural space in the cranium also has been reported [2]. Our case showed no evidence of pulmonary or chest wall hydatidosis, and spinal extradural deposits were due to hematogenous spread. Areas of low signal intensity seen in few cysts on T2-weighted images were similar to earlier observations for hepatic and pulmonary lesions [3, 4]. This finding was attributed to a decreased amount of fluid and collapsed chitinous hyaline membrane of the cyst's wall, suggesting dying or dead cysts.

Our case showed primary spinal echinococcosis that was manifested as paraplegia. MR can provide preoperative delineation of the lesion, and the lesion's morphologic characteristics may suggest the diagnosis.

Amarnath Jena
Rajendra Prasad Tripathi
Institute of Nuclear Medicine and Allied Sciences
Lucknow Marg, Delhi-110054, India
Anil Kumar Jain
G. T. B. Hospital
Shahdara, Delhi-110095, India

REFERENCES

1. Mikhael MA, Ciric IS, Tarkington JA. MR imaging in spinal echinococcosis. *J Comput Assist Tomogr* 1985;9(2):398–400
2. Ba'assiri A, Haddad FS. Primary extradural intracranial hydatid disease: CT appearance. *AJNR* 1984;5:474–475
3. Von Sinner WN, Rifai A, Strake LTE, Seick J. Magnetic resonance imaging of thoracic hydatid disease: correlation with clinical findings, radiography, ultrasonography, CT and pathology. *Acta Radiol* 1990;31:59–62
4. Morris DL, Buckley J, Gregson R, Worthington BS. Magnetic resonance imaging in hydatid disease. *Clin Radiol* 1987;38:141–144

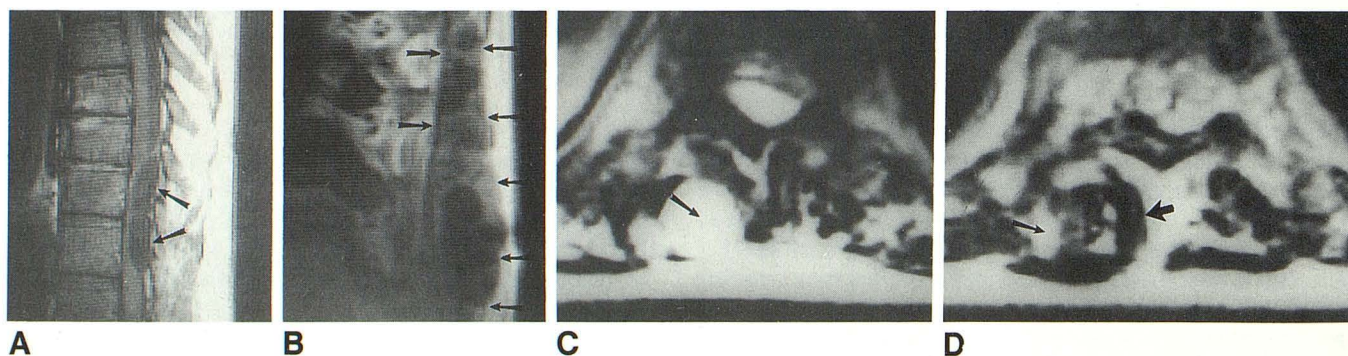


Fig. 1.—Extradural compression due to spinal echinococcosis.

A, Sagittal MR image (SE 700/22) shows a loculated cystic lesion (arrows) in extradural space at T9–T11 compressing spinal cord. No extrinsic impression on vertebral bodies is seen.

B, Parasagittal T1-weighted MR image (SE 700/22) shows multicystic mass (daughter cysts) in muscle plane (arrows). Cysts contain low-intensity fluid, and cyst walls are iso- to mildly hyperintense.

C, Axial T2-weighted MR image (SE 2000/56) shows a viable cyst in muscle (arrow). Cyst is filled with fluid and appears hyperintense.

D, Axial MR image (SE 2000/56) shows a dying cyst. Note minimal hyperintense fluid (thin arrow) and mostly low-intensity collapsed cyst wall (thick arrow).