

Are your MRI contrast agents cost-effective?

Learn more about generic Gadolinium-Based Contrast Agents.



**FRESENIUS
KABI**

caring for life

AJNR

Neurocutaneous melanosis and temporal lobe tumor in a child: MR study.

G Sebag, J Dubois, P Pfister, F Brunelle and C St-Rose

AJNR Am J Neuroradiol 1991, 12 (4) 699-700

<http://www.ajnr.org/content/12/4/699.citation>

This information is current as
of April 10, 2024.

Neurocutaneous Melanosis and Temporal Lobe Tumor in a Child: MR Study

The concept of neurocutaneous melanosis was described in 1948 by Van Bogaert [1] as a nonfamilial neuroectodermal dysplasia, but the first report of an individual with stigmata of neurocutaneous melanosis was made by Rokitsansky [2] in 1861. The criteria to be met for diagnosis are large multiple pigmented skin nevi (more than 20 cm in diameter) with an excess of melanotic cells in the leptomeninges, no malignant melanomatous transformation of the involved skin, and no evidence of malignant melanoma in any organ other than the nervous system.

Until recently, diagnosis of involvement of the leptomeninges was impossible in vivo. MR imaging can be used now to diagnose such an involvement. The patient reported here is extremely unusual: He had typical skin involvement, but his intracerebral melanoma did not involve the leptomeninges. MR showed an unusual signal appearance, probably associated with the degree of enhancement of paramagnetic relaxation, that allowed us to diagnose a melanotic tumor even though the expected leptomeningeal involvement was absent.

Case Report

The patient has been observed since his birth because of multiple congenital giant hairy skin nevi on his buttocks and back (Fig. 1A). He was asymptomatic until the age of 4 years, when he experienced multiple episodes of complex partial seizures. Clinical examination showed a normal child with no neurologic deficit. Electroencephalography showed abnormal electrical activity in the right temporal region. CT showed a hyperdense noncalcified, nonenhancing right temporal mass. MR at 0.5 T showed a 15-mm mass in the right temporal lobe with signal hyperintensity on a short TR short TE (T1-weighted spin-echo) sequence (Fig. 1B). The same region was hypointense on long TR long TE (T2-weighted spin-echo) images (Fig. 1C). No evidence of high flow was present. This appearance was unchanged on follow-up MR images obtained 4 months later.

At surgery, a brownish tumor was found in the right temporal lobe, with a clear demarcation between the normal ependyma of the temporal ventricular horn and the mass. No involvement of the leptomeninges was seen. The tumor was resected completely. Pathologic examination showed a blackish pigment confined to the white matter and minimal involvement of the gray matter. The meninges

and the Virchow-Robin spaces appeared normal, with no pigmentation. Histologically, the pigment was extracellular or within macrophages and was arranged principally along the perivascular spaces. The neuromelanin composition of these pigmented granules was proved by using the Fontana method. No iron was found on the Perls reaction. Electron microscopy showed melanoblast. The neurons were normal ultrastructurally except for the presence of the melanotic granules associated with lipofuscin granules. No cellular atypia was present, and mitotic figures were not identified. No evidence of previous hemorrhage was seen. The final diagnosis was melanoma involving mostly the white matter and minimally the gray matter, without leptomeningeal involvement.

Discussion

Neurocutaneous melanosis is an embryonal neuroectodermal dysplasia. Primarily infants and young children are affected, and no sex predilection is known. The usual signs are epilepsy, hydrocephalus, cranial nerve palsies, subdural hemorrhage, or intracranial hemorrhage.

In a recent review of the literature, Vanheusen et al. [3] found that 77 cases with multiple large pigmented nevi and leptomeningeal melanosis have been reported. Cases with leptomeningeal involvement have a potential for malignant degeneration; the estimated prevalence is 40–50%. All of the 77 cases were confirmed by pathologic findings. CT was done in only a few cases [4, 5], and MR of the spinal cord was done in only one case of leptomeningeal spinal melanosis. To our knowledge, no MR of intracerebral involvement has been described. The interesting aspect of our case was that MR showed no melanotic infiltration of the leptomeninges but did show parenchymal involvement.

A paramagnetic effect of melanin has been discussed in the literature, but the nature of this effect is still controversial. Unlike most brain neoplasms, which have increased T1 and T2 relaxation times on MR, in our case, the temporal lesion had decreased T1 and T2 relaxation times, suggestive of a melanotic lesion [6]. Areas of hemorrhage and stable free radicals (indolesemiquinones and semiquinonimines) within melanin are paramagnetic and reportedly are

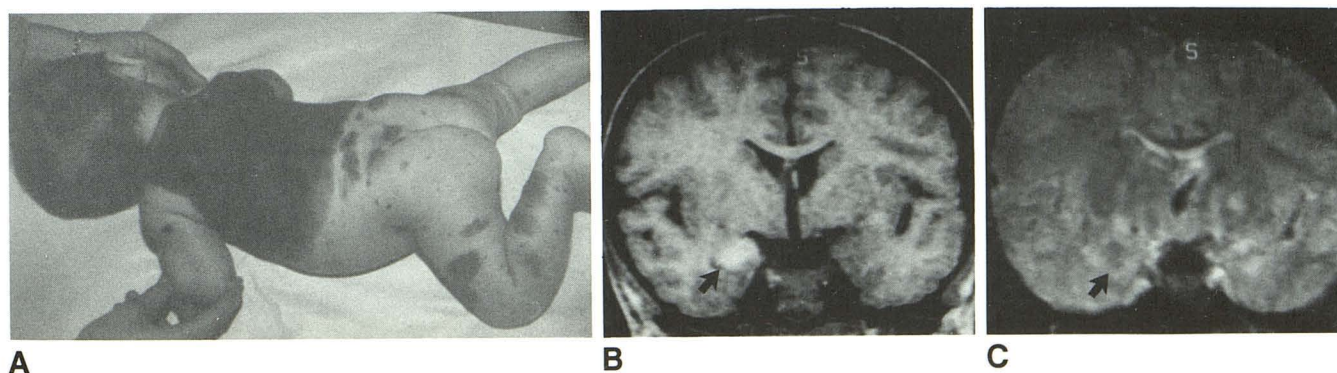


Fig. 1.—Neurocutaneous melanosis and temporal lobe tumor.

A, Photograph of patient when he was 6 months old shows multiple congenital hairy nevi.

B and C, Coronal spin-echo MR images show a lesion in right temporal lobe that is hyperintense on T1-weighted sequence (380/40, B) and hypointense on T2-weighted sequence (1818/120, C).

responsible for inducing a susceptibility effect and therefore decreasing the T1 and T2 relaxation times of melanotic lesions. It also has been reported that the greater the melanin content, the more pronounced is the decrease in both T1 and T2 relaxation times [6].

To our knowledge, only one other case of intraparenchymal melanosis without leptomeningeal involvement has been reported [7]. In all the other cases reported, melanoblastic infiltration of meninges produced macroscopic thickening and pigmentation of pia-arachnoid. In the case reported by Fox et al. [7], histologically, at necropsy, an excess of melanin was found in the gray matter, especially in the brainstem nuclei, the reticular gray matter of the pons. A few areas of cerebral cortex also were involved. The case of Fox et al. differs from ours because of the diffuse involvement of gray matter. Although leptomeningeal infiltration is part of the definition of neurocutaneous melanosis, our case likely is a variant of the disease, suggesting that neurocutaneous melanosis syndrome includes a spectrum of findings.

G. Sebag
J. Dubois
P. Pfister
F. Brunelle
C. St-Rose

Hopital des Enfants-Malades
75015 Paris, France

REFERENCES

1. Van Bogaert LC. La mélanose neurocutanée diffuse hérédofamiliale. *Bull Acad R Med Belg* 1948;13:397-427
2. Rokitsansky J. Ein ausgezeichneter Fall von Pigment-Malmit ausgebreiteter pigmentierung der inneren Hirn-und Rücken markshäute. *Allg Wien Med Ztg* 1861;6:113-116
3. Vanheusen EP, Kaise MC, Deslegter RGM. Neurocutaneous melanosis associated with intraspinal lipoma. *Neuroradiology* 1989;31:349-351
4. Leaney BJ, Rowe PW, Klug GL. Neurocutaneous melanosis with hydrocephalus and syringomyelia. *J Neurosurg* 1985;62:148-152
5. Faillace WJ, Shige-Hisa O, et al. Neurocutaneous melanosis with extensive intracerebral and spinal cord involvement. *J Neurosurg* 1984;61:782-785
6. Woodruff WW Jr, Djang WT, McLendon RE, Heinz ER, Voorhees DR. Intracerebral malignant melanoma: high-field-strength MR imaging. *Radiology* 1987;165:209-213
7. Fox H, Emery JL, Goodbody RA, Yates O. Neuro-cutaneous melanosis. *Arch Dis Child* 1964;39:508-516