

Are your **MRI contrast agents** cost-effective?

Learn more about generic **Gadolinium-Based Contrast Agents**.



FRESENIUS
KABI

caring for life

AJNR

Dumbbell-shaped spinal cavernous hemangioma: a case report.

A B Haimes and G Krol

AJNR Am J Neuroradiol 1991, 12 (5) 1021-1022

<http://www.ajnr.org/content/12/5/1021.citation>

This information is current as
of April 19, 2024.

Dumbbell-Shaped Spinal Cavernous Hemangioma: A Case Report

Epidural cavernous hemangiomas are rare. The MR appearance of a purely intraspinal, epidural lesion has recently been described [1]. We report a case of a dumbbell-shaped cavernous hemangioma that extended through the adjacent neural foramen, producing a large paraspinous mass.

Case Report

An otherwise healthy 46-year-old man had had midthoracic pain and lower-extremity hypoesthesia for 10 months. Chest radiographs showed a smoothly marginated, 3-cm, left-sided paraspinous mass. Lumbar and subsequent cervical myelograms showed cord compression with high-grade epidural block and mostly left-sided epidural disease extending from T2 to T4. CT scans obtained after myelography showed a dumbbell-shaped mass with a large intrathoracic component extending through the T3–T4 neural foramen (Fig. 1A). The well-circumscribed left-sided epidural component of the mass extended from T2 to the T4–T5 interspace. No intradural component was seen. The mass was isodense with muscle and relatively homogeneous. The T3 vertebral body was mildly eroded but intrinsically normal. The well-circumscribed mass was isointense with spinal cord and skeletal muscle on T1-weighted MR images (600/20) (Figs. 1B and 1C) and markedly hyperintense to these structures on T2-weighted images (2150/60) (Fig. 1D), where scattered serpiginous foci of hypointensity were noted within the lesion. The coronal T1-weighted images showed the dumbbell shape and long intracanalicular segment. A small hyperintense focus was present in the posterolateral aspect of the vertebral body adjacent to the mass. The preoperative differential diagnosis included lymphoma, neurofibroma, schwannoma, and meningioma. Thoracotomy and laminectomies revealed a more infiltrative mass than suspected preoperatively, and only partial resection was possible. No intradural or osseous involvement was present despite the suggestion of vertebral involvement on the axial T2-weighted MR images. Pathologic examination showed

a cavernous hemangioma involving the overlying parietal pleura and entrapping a segment of peripheral nerve and spinal ganglion.

Discussion

Most hemangiomas involving the epidural space are actually extensions of lesions of the vertebral bodies [2]. Purely vertebral hemangiomas are relatively common; they are found in 11% of spines at autopsy and are symptomatic in less than 1% of cases [3]. Exclusively extradural hemangiomas are distinctly unusual, and the few reported dumbbell-shaped lesions were in the thoracic spine [4]. Although grossly they appear well-circumscribed, hemangiomas are unencapsulated and infiltrate adjacent tissue, necessitating extensive surgery. Although some think that hemangiomas are true neoplasms, most pathologists think the lesions are hamartomatous malformations and categorize the masses as cavernous or capillary on the basis of the size of the vascular channels; cavernous hemangiomas are the larger ones.

The intensities of soft-tissue cavernous hemangiomas on MR have been described and are characteristic, reflecting the lesions underlying morphology [5, 6]. T1-weighted MR images suggest a well-defined mass hypointense to muscle. The marked hyperintensity on T2-weighted images may reflect the increased free water in the stagnant blood present within the large vascular channels. Intervening fibrofatty septae, vascular thrombosis, and calcification appear as serpiginous foci of central hypointensity.

Although characteristic, the radiologic features of hemangiomas are nonspecific and might be compatible with a diagnosis of neurofibroma, schwannoma, or meningioma, tumors that more commonly produce dumbbell-shaped spinal lesions [7]. The extensive cephalocaudal epidural involvement, the absence of an intradural component, and the possible involvement of the adjacent vertebral body should, however, prompt consideration of and an adequate surgical approach suitable for other more infiltrating extradural entities, such as lym-

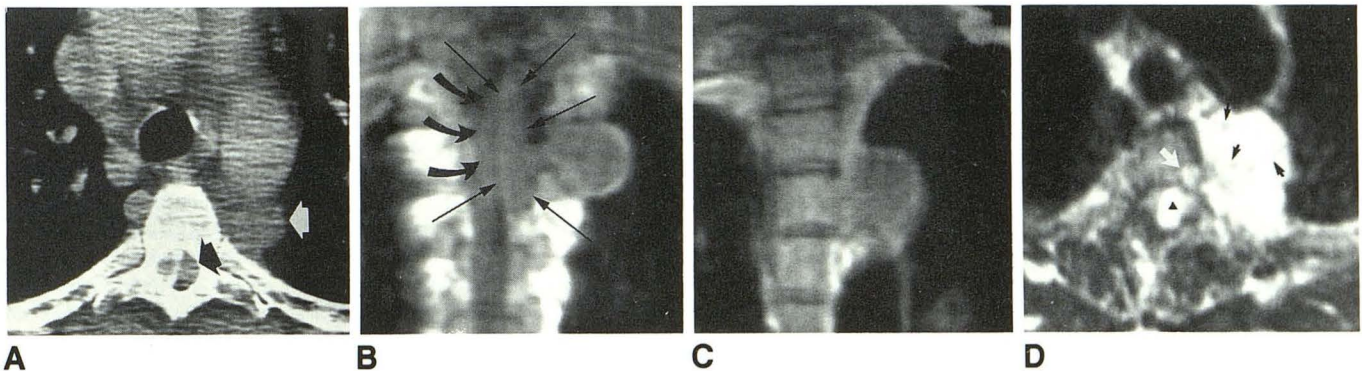


Fig. 1.—Dumbbell-shaped epidural spinal cavernous hemangioma.
A, Axial CT scan after myelography shows dumbbell-shaped lesion with extradural intraspinal extension (*black arrow*) and a large intrathoracic component (*white arrow*).
B and C, Coronal T1-weighted MR images (600/20) confirm dumbbell shape of well-circumscribed mass, which is isointense with spinal cord (*curved arrows*) and skeletal muscle. Long intracanalicular segment (*straight arrows*) is well seen.
D, Axial T2-weighted MR image (2150/60) shows markedly hyperintense mass with internal foci of hypointensity (*black arrows*). Hyperintense focus in left posterolateral vertebral body is similar in intensity to mass (*white arrow*). *Triangle* is in center of intraspinal mass. Sac is displaced to right.

phoma, angioliipoma, and, as described, cavernous hemangioma. Administration of contrast agent also might be helpful in preoperative differential diagnosis.

Alison B. Haimes
Memorial Sloan-Kettering Cancer Center
New York, NY 10021
George Krol
SJK Magnetic Resonance Imaging
New York, NY 10021

REFERENCES

1. Feider HK, Yuille DL. An epidural cavernous hemangioma of the spine. *AJNR* 1991;243-244
2. Guthkelch AN. Hemangioma involving the spinal epidural space. *J Neurosurg Psychiatry* 1948;11:199-210
3. Brobeck O. Hemangioma of the vertebra associated with compression of the spinal cord. *Acta Radiol* 1950;34:235-243
4. Padovani R, Poppi M, Pazzati E, Tognetti F, Querzola C. Spinal epidural hemangiomas. *Spine* 1981;6(4):336-340
5. Cohen EK, Kressel HY, Perosio T, et al. MR imaging of soft-tissue hemangiomas: correlation with pathologic findings. *AJR* 1988;150:1079-1081
6. Buetow PC, Kransdorf MJ, Moser RP Jr, Jelinek JS, Berry BH. Radiologic appearance of intramuscular hemangioma with emphasis on MR imaging. *AJR* 1990;154:563-567
7. Burk DL Jr, Brunberg JA, Kanal E, Latchaw RE, Wolf GL. Spinal and paraspinous neurofibromatosis: surface coil MR imaging at 1.5 T. *Radiology* 1987;162:797-801

Erratum

In the commentary by Kucharczyk that followed the letters to the editor by Abrahams and by Berns and the reply by Katz (*AJNR* 1991;12:580-581), the first sentence of the fifth paragraph should read "The coronal image in case 1 in the paper by Benschhoff and Katz [not Truwit and Barkovich, as printed] is misleading." *AJNR* apologizes for this error.