

Are your **MRI contrast agents** cost-effective?

Learn more about generic **Gadolinium-Based Contrast Agents**.



FRESENIUS  
KABI

caring for life

# AJNR

## **Improved detection of cerebral hypoperfusion with internal carotid balloon test occlusion and <sup>99m</sup>Tc-HMPAO cerebral perfusion SPECT imaging.**

S B Peterman, A Taylor, Jr and J C Hoffman, Jr

This information is current as of April 16, 2024.

*AJNR Am J Neuroradiol* 1991, 12 (6) 1035-1041  
<http://www.ajnr.org/content/12/6/1035>

# Improved Detection of Cerebral Hypoperfusion with Internal Carotid Balloon Test Occlusion and $^{99m}\text{Tc}$ -HMPAO Cerebral Perfusion SPECT Imaging

Susan Brothers Peterman<sup>1</sup>  
 Andrew Taylor, Jr.  
 James C. Hoffman, Jr.

A new method that employs a cerebral perfusion imaging agent,  $^{99m}\text{Tc}$ -HMPAO, is described for identifying those patients who clinically pass an internal carotid artery balloon test occlusion but who then may develop a cerebral infarction after permanent occlusion. Test balloon occlusion of the internal carotid artery was performed in 17 patients, and  $^{99m}\text{Tc}$ -HMPAO was injected intravenously while the balloon was inflated. The balloon was deflated and removed approximately 15–20 min later, and single-photon emission CT (SPECT) imaging of the brain was performed. In patients with an area of focal hypoperfusion, the  $^{99m}\text{Tc}$ -HMPAO study was repeated the next day to determine if the hypoperfusion was due to the temporary balloon occlusion or to a preexisting abnormality. All 17 patients had normal neurologic examinations at the time of the balloon test occlusion. Fifteen had symmetric perfusion on the  $^{99m}\text{Tc}$ -HMPAO SPECT scans. Five of these had permanent internal carotid artery occlusion, and four did not develop a neurologic deficit. One patient developed an ipsilateral watershed infarction after internal carotid artery occlusion during significant intraoperative hypotension. Two patients had ipsilateral regions of hypoperfusion with the test occlusion. Both these patients had repeat nonocclusion  $^{99m}\text{Tc}$ -HMPAO SPECT studies that were normal. One patient is being followed. The second patient had ipsilateral EEG changes associated with temporary intraoperative occlusion of the internal carotid artery during aneurysm surgery.

Although the numbers are relatively small, this study suggests that this protocol may be able to predict a good outcome after permanent carotid artery occlusion as well as to identify patients who are at greater risk for developing cerebral infarction after permanent occlusion. This procedure is safe and can be performed with equipment that is readily available in most radiology departments.

*AJNR* 12:1035–1041, November/December 1991

The treatment of inoperable internal carotid artery aneurysms and extensive tumors involving the neck or skull base may require occlusion of the internal carotid artery. The circle of Willis provides collateral circulation for the territory of the occluded internal carotid artery; however, it is completely intact in only 21% of the population [1]. Balloon test occlusion of the internal carotid artery with monitoring of clinical neurologic status is used to identify those patients who might develop ischemia and infarction with permanent occlusion. However, 5–20% of the patients who show no clinical signs of ischemia during the test occlusion will develop an infarction with permanent occlusion [2–4].

Various techniques have been described to identify those patients who tolerate the balloon test occlusion clinically but who then may develop an infarction after permanent occlusion. Measurement of stump pressures has been shown to be inaccurate [5]. A positron emission tomography (PET) scan during the balloon test occlusion would give information about cerebral blood flow, oxygen extraction, and metabolism, but this technique is available only at a few institutions [6]. In addition, performing a PET scan during the test occlusion period would be technically difficult. Xenon CT cerebral blood flow imaging may show areas of ischemia with

Received November 16, 1990; revision requested February 16, 1991; revision received March 26, 1991; accepted April 22, 1991.

<sup>1</sup> All authors: Department of Radiology, Emory University School of Medicine, 1364 Clifton Rd., Atlanta, GA 30322. Address reprint requests to S. B. Peterman.

the balloon test occlusion that are clinically inapparent, but it requires special features on the CT scanner [2, 4, 7]. We describe a new technique using a cerebral perfusion imaging agent,  $^{99m}\text{Tc}$ -hexamethylpropyleneamine oxime (HMPAO) (Ceretek, Amersham, Arlington Heights, IL), for evaluating clinically inapparent cerebral ischemia during internal carotid balloon test occlusion. This radionuclide scan can be performed with equipment readily available in most nuclear medicine departments.

## Materials and Methods

Seventeen patients were evaluated for possible permanent internal carotid artery occlusion from September 1989 to July 1990. Four patients had large internal carotid artery aneurysms, three had internal carotid artery pseudoaneurysms, one had a large carotid/cavernous sinus fistula consequent to a gunshot wound, three had extensive skull base tumors, and six had neck tumors adjacent to the internal carotid artery.

A 7-French sheath was placed in the femoral artery, and common and internal carotid angiograms of the affected side were obtained. The patient was given 5000 units of heparin intravenously. The catheter in the internal carotid artery was then exchanged for a 7-French two-lumen polyethylene occlusion balloon catheter (100 cm long, 11.5 mm balloon diameter) (Meditech, Watertown, MA). The occlusion balloon was placed in the distal common carotid artery in one patient who had atherosclerotic narrowing of the proximal internal carotid artery. Occlusion of the internal carotid artery was verified under fluoroscopy with stasis of contrast material injected through the central lumen of the catheter. This contrast material was then aspirated, and the central lumen was perfused with heparinized saline. The patient was monitored by constant clinical neurologic examination, including evaluation of sensation and motor strength of the face and all four extremities as well as orientation to time, place, and person.

A sheath was placed in the contralateral femoral artery at the beginning of the procedure in 11 patients. This was used for selective angiography of the contralateral internal carotid artery during the balloon test occlusion to verify cross-filling during the occlusion. In the six patients who did not have a second sheath, the contralateral internal carotid artery was evaluated angiographically prior to placement of the occlusion balloon catheter.

The balloon was to be deflated immediately if the patient became symptomatic; however, all the patients in this study tolerated the balloon occlusion clinically. A bolus of 20 mCi of  $^{99m}\text{Tc}$ -HMPAO was injected intravenously 10–15 min after the balloon occlusion. The balloon remained inflated for an additional 15–20 min (a total of 30 min) as long as the patient was without deficit on clinical neurologic examination. The balloon catheter was then deflated while aspirating the central lumen in order to prevent thrombus embolization. The catheter was removed.

Patients were transferred with the femoral arterial sheath(s) in place to the nuclear medicine department for cerebral single-photon emission CT (SPECT) imaging. Data were acquired with a General Electric Starcam system. Acquisition parameters included a high-resolution collimator, circular orbit, 128 views, 12 sec per view, a 1.6 zoom, and a  $128 \times 128$  matrix.

Subsequently, the femoral sheath(s) were removed and hemostasis was achieved. Protamine sulfate (1 mg/100 units heparin) was given intravenously as needed.

Two patients in this series had a repeat  $^{99m}\text{Tc}$ -HMPAO SPECT scan without test occlusion because of evidence of hypoperfusion of the cerebral hemisphere ipsilateral to the test-occluded internal ca-

rotid artery. Owing to the short half-life of  $^{99m}\text{Tc}$ , the repeat scan could be performed 24–48 hr after the initial study.

## Results

None of the 17 patients showed evidence of ischemia on clinical neurologic examination during the 30 min of balloon test occlusion of the internal carotid artery.

Of the 11 patients who had selective angiography of the other internal carotid artery during test occlusion, 10 showed good cross-filling. The one patient with poor angiographic cross-filling from the contralateral internal carotid artery had a normal cerebral perfusion scan with the test occlusion indicating that collateral flow was probably from the posterior circulation. Surgery for her neck mass did not necessitate a permanent internal carotid occlusion.

All the  $^{99m}\text{Tc}$ -HMPAO cerebral perfusion SPECT scans were of diagnostic quality. Fifteen of the 17 patients showed symmetric perfusion on the  $^{99m}\text{Tc}$ -HMPAO cerebral perfusion SPECT scan. Five of these patients had permanent internal carotid artery occlusion. Four of the five patients tolerated the permanent occlusion well without developing new neurologic deficits. One patient had an ipsilateral frontal watershed infarction following permanent intraoperative internal carotid artery occlusion for a large ophthalmic artery aneurysm. The aneurysm ruptured intraoperatively, and the patient was hypotensive due to blood loss, with a blood pressure of 70/30 when the artery was occluded. The intraoperative EEG showed ischemic changes bilaterally during the hypotensive episode. After the patient became normotensive, the EEG on the side contralateral to the internal carotid occlusion returned to normal and the EEG on the ipsilateral side improved but did not return to normal.

The patient who had a balloon test occlusion of the common carotid artery because of internal carotid artery stenosis showed no areas of hypoperfusion on the cerebral perfusion scan. Surgery for his neck mass did not require a permanent internal carotid artery occlusion. The predictive value of the common carotid artery occlusion is unclear.

Two patients showed hypoperfusion of the ipsilateral cerebral hemisphere on the  $^{99m}\text{Tc}$ -HMPAO cerebral perfusion SPECT scan associated with the balloon test occlusion. The repeat cerebral perfusion scan 24 hr later showed symmetric perfusion in both patients. The first patient had an asymptomatic pseudoaneurysm of the distal cervical internal carotid artery (Fig. 1). It was elected to follow the pseudoaneurysm at this time, since the patient was asymptomatic and the natural history of pseudoaneurysms is not well documented. An external carotid–internal carotid arterial bypass is planned prior to permanent internal carotid artery occlusion if the pseudoaneurysm begins to enlarge or symptoms develop.

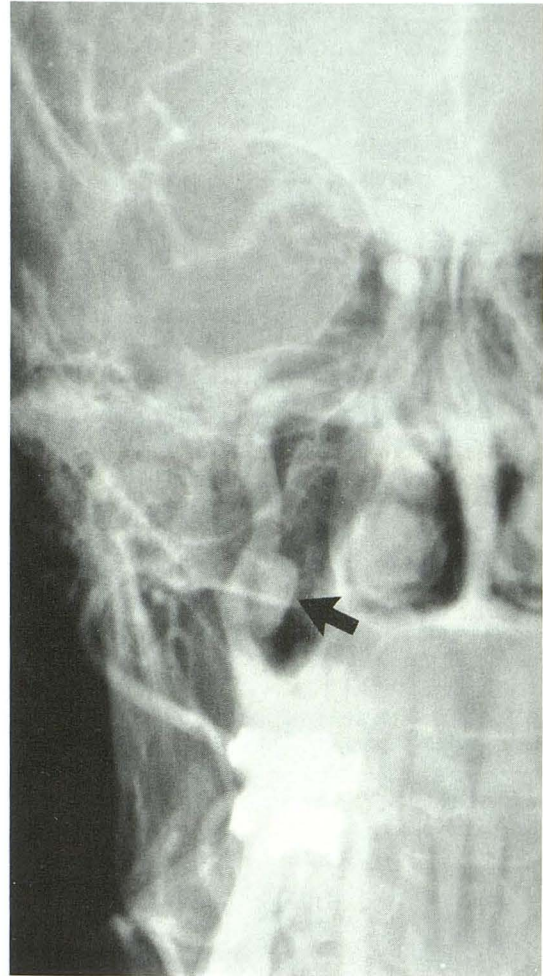
The second patient had a test occlusion because of the possibility that the internal carotid artery would have to be permanently occluded intraoperatively during an attempt to clip an aneurysm of the cavernous carotid artery (Fig. 2). Temporary vascular clips were placed on the internal carotid artery intraoperatively while the systemic blood pressure was being elevated. Intraoperative EEG monitoring showed ipsilateral slowing during the temporary occlusion. The clips were

Fig. 1.—55-year-old man with right eye pain and right-sided Horner syndrome 4 years after a severe skiing accident.

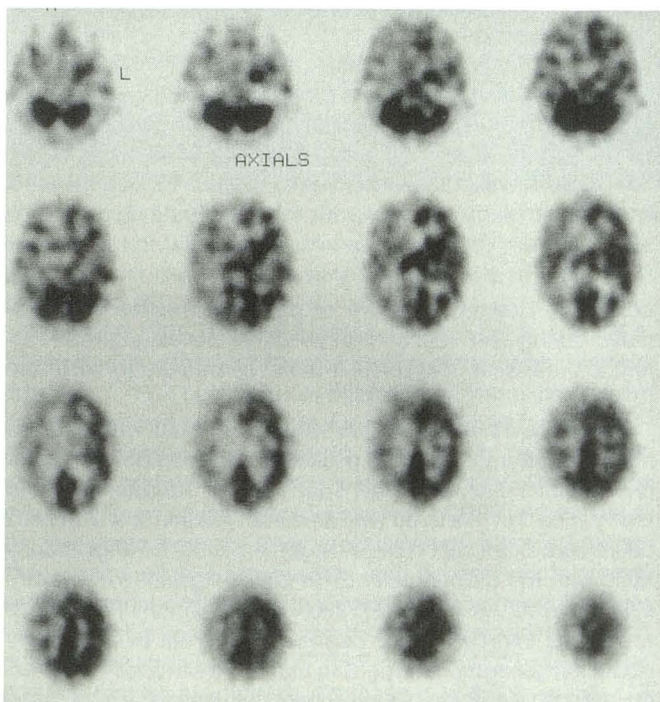
A, Anteroposterior view of right common carotid angiogram shows a pseudoaneurysm (arrow) of the medial cervical internal carotid artery.

B,  $^{99m}\text{Tc}$ -HMPAO SPECT scan done with a balloon test occlusion of the right internal carotid artery shows hypoperfusion of the right cerebral hemisphere, although the neurologic examination was normal during the test occlusion. The SPECT images are displayed from the skull base to the vertex in the transaxial plane. Regional cerebral blood flow is a function of the darkness on the images.

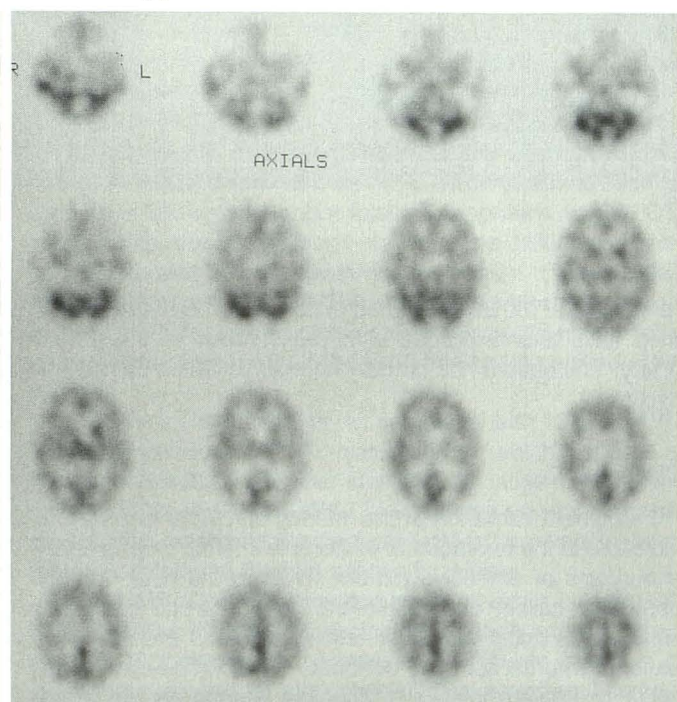
C, Cerebral perfusion is symmetric on  $^{99m}\text{Tc}$ -HMPAO SPECT scan done the next day. The pseudoaneurysm is being followed.



A



B



C

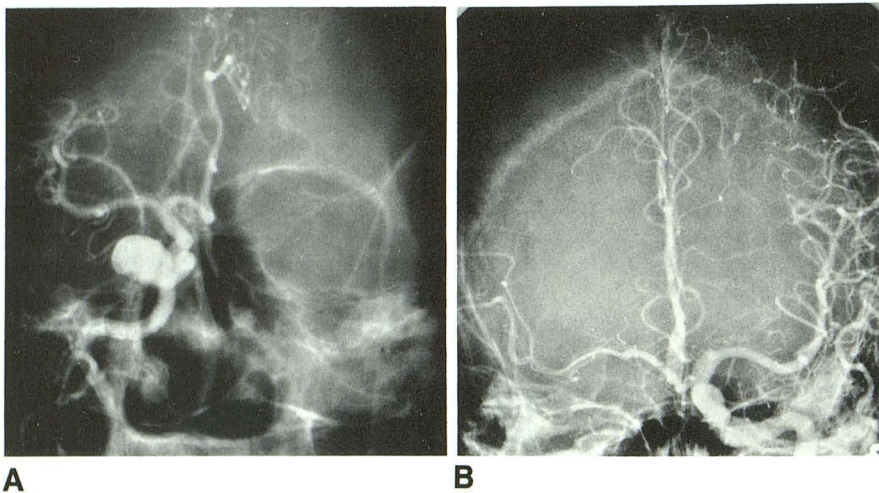


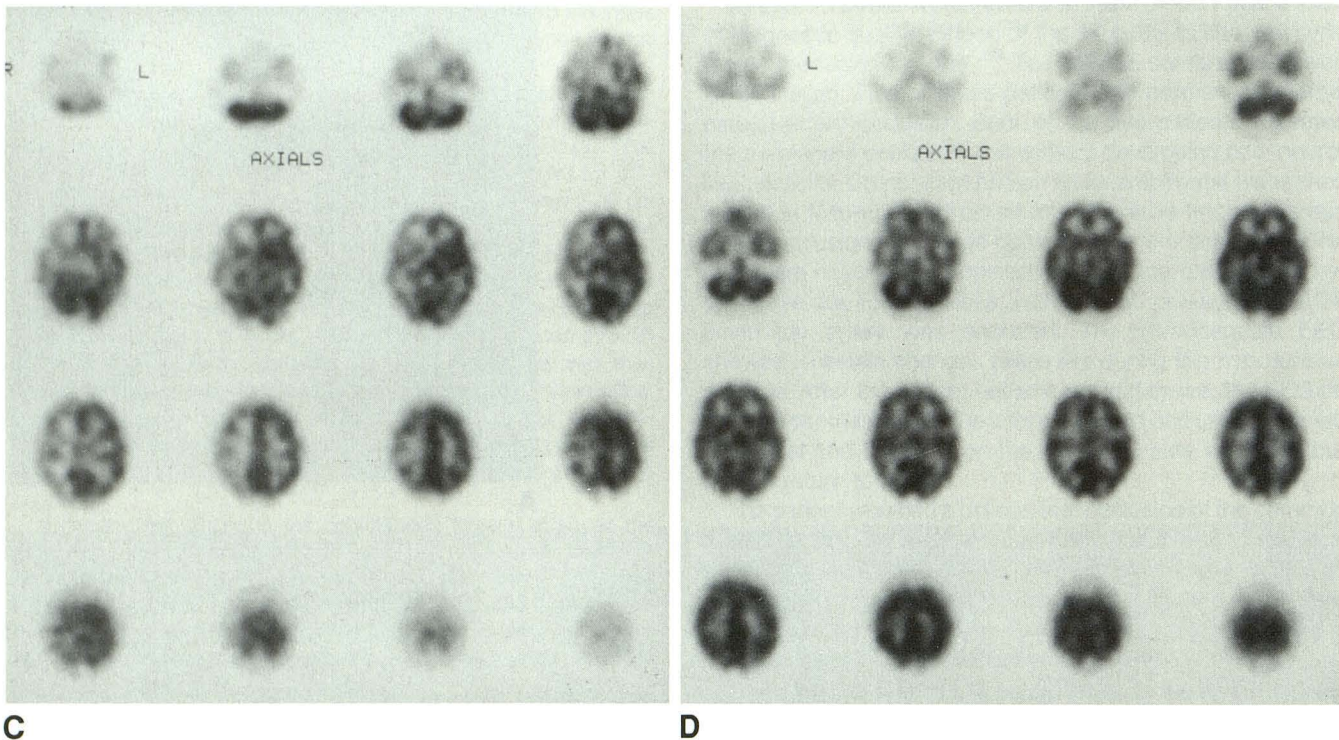
Fig. 2.—39-year-old man with headache and diplopia.

A, Anteroposterior view of right common carotid angiogram shows a large cavernous carotid artery aneurysm.

B, During balloon test occlusion, the neurologic examination was normal; and this anteroposterior left common carotid angiogram shows good cross-filling.

C,  $^{99m}\text{Tc}$ -HMPAO SPECT scan done with balloon test occlusion shows right cerebral hemisphere hypoperfusion. The SPECT images are displayed from the skull base to the vertex in the transaxial plane.

D,  $^{99m}\text{Tc}$ -HMPAO SPECT scan done the next day shows symmetric perfusion. Temporary intraoperative vascular clipping of the internal carotid artery produced ipsilateral ischemic EEG changes that resolved on removal of the clips.



removed and the EEG returned to normal. The aneurysm was then satisfactorily clipped with preservation of the parent artery. The patient had no new neurologic deficit postoperatively.

#### Discussion

Permanent occlusion of the internal carotid artery may be indicated in the treatment of inoperable internal carotid artery aneurysms or extensive tumors involving the neck or skull base. Test balloon occlusion of the internal carotid artery with concurrent clinical neurologic testing is able to exclude some patients who do not have adequate collateral cerebral circulation to prevent infarction following internal carotid artery

occlusion. However, 5–20% of patients who are asymptomatic during test balloon occlusion will develop cerebral infarction following permanent internal carotid artery occlusion [2–4].

There are several possible ways to explain why patients may tolerate a test balloon occlusion and then develop cerebral infarction after permanent occlusion of the internal carotid artery. The first has to do with an inability to perform a detailed neurologic examination while the patient is on the angiography table with the balloon catheter in place. Against this hypothesis, however, is the observation that patients who develop a cerebral infarction after permanent internal carotid artery occlusion generally have deficits that could be readily detected on a basic neurologic examination. A second explanation

involves the formation of a thrombus distal to the site of occlusion, which then breaks free to embolize more distally and thus produce a cerebral infarction. This is a theoretical possibility but does not seem to be supported by autopsy studies. A third explanation, and perhaps the most likely, is that regional cerebral blood flow (rCBF) may be near the threshold for maintaining cerebral function during the test internal carotid artery occlusion. If the patient experiences hypotension or blood loss after permanent internal carotid artery occlusion, then the rCBF drops below the threshold and cerebral infarction occurs.

Such a threshold for rCBF below which infarction results has been demonstrated in monkeys in whom cerebral infarction occurred with rCBF below 17–18 ml/100 g/min after permanent occlusion [8]. If, for example, this concept is extrapolated to a patient in whom the rCBF during test occlusion of the internal carotid artery was 25 ml/100 g/min, the patient would maintain normal cerebral function and would have a negative neurologic examination during the test occlusion. If the patient had permanent occlusion of the internal carotid artery and subsequently had a decrease in systemic blood pressure secondary to blood loss, diuresis, sedation, or cardiac arrhythmia, then the rCBF might decrease below 17–18 ml/100 g/min, resulting in focal cerebral infarction.

With this hypothesis, the problem then becomes that of identifying borderline cerebral blood flow that is clinically inapparent during test internal carotid artery occlusion. Carotid stump pressures have been shown to correlate with intracranial blood flow, but the wide range of normal values precludes its use as an absolute indicator of borderline cerebral blood flow [4, 5]. EEG has been used to identify early cerebral ischemic changes; however, patients with a normal EEG during temporary internal carotid occlusion have developed cerebral infarctions [5, 9]. These were attributed to thromboembolic events, although none was proved. Angiographic evidence of cross-filling from the nonoccluded side to the occluded side is a poor predictor of whether the patient will tolerate permanent occlusion [10]. This was true in our second patient, who had reversible asymmetric cerebral hypoperfusion on the SPECT scan with good angiographic cross-filling. PET would provide a more sensitive indicator of decreased cerebral perfusion; however, the equipment is very expensive, not widely available, and the study may be logistically difficult owing to the very short half-life of most PET radiotracers [6].

Xenon CT CBF imaging is able to detect borderline rCBF in association with balloon test occlusion of the internal carotid artery [2, 4, 7]. Focal areas of decreased cerebral blood flow can be identified by the CT technique. Symmetric and asymmetric decreases in rCBF were identified in patients with normal neurologic examinations during test occlusion. One patient with an asymmetric decrease in rCBF on the side of the test internal carotid artery occlusion and a normal neurologic examination subsequently had a permanent internal carotid arterial occlusion. He developed a postoperative cerebral infarction in the distribution of the decreased rCBF seen on the preoperative xenon CT CBF images [7]. These studies suggest that an asymmetric decrease in rCBF on xenon CT

CBF imaging in patients with a normal neurologic examination with test balloon occlusion indicates that such patients are at high risk for developing a cerebral infarction after permanent internal carotid artery occlusion. Furthermore, these studies point out the importance of evaluating cerebral perfusion and suggest that the origin of the cerebral infarction is hypoperfusion rather than embolus.

Nevertheless, xenon CT CBF imaging has certain disadvantages. It requires special features to be added to the CT scanner. These features are not available for all types of CT scanners and are not commonly present in most radiology departments. The technique of xenon CT CBF imaging with test balloon occlusion requires the patient to be transported to the CT scanner with the deflated balloon catheter in the internal carotid artery. The balloon must then be inflated on the CT table without fluoroscopic guidance so that incomplete occlusion or balloon overinflation may occur. Only three slices of the brain are obtained with the xenon CT CBF imaging. Transcranial Doppler studies show that inhalation of xenon itself can raise the cerebral blood velocity and thus affect the test results [11].

Several radionuclides, *N*-isopropyl- $p$ - $^{123}\text{I}$ -iodoamphetamine (IMP) and  $^{99\text{m}}\text{Tc}$ -HMPAO, have been developed for evaluating cerebral blood flow or perfusion with SPECT imaging. We chose  $^{99\text{m}}\text{Tc}$ -HMPAO SPECT imaging for several reasons. It is immediately available as an off-the-shelf kit using readily available  $^{99\text{m}}\text{Tc}$ -pertechnetate. The  $^{123}\text{I}$ -IMP must be specially ordered. Three of our 17 cases were done urgently without the advance warning that would be needed to order the  $^{123}\text{I}$ -IMP.

$^{99\text{m}}\text{Tc}$ -HMPAO is a lipophilic tracer with an extraction across the blood-brain barrier of about 0.75. Once inside the brain, it is rapidly converted to a hydrophilic form that is retained for hours. Pharmacokinetic studies show the brain activity peaking at 40–50 sec with a 10% decrease in the first 10 min, presumably from back-diffusion [12–14]. Thereafter, the count rate changes little for the next several hours. The contrast between normal and abnormal brain remains constant between 10 min and 2 hr [12]. The background tracer is cleared by the urinary and hepatobiliary systems and is negligible within a few minutes [12]. These pharmacokinetic properties allow for a more leisurely approach to SPECT imaging after the test balloon occlusion. The balloon catheter can be removed before transferring the patient to the nuclear medicine department.  $^{123}\text{I}$ -IMP is associated with some degree of redistribution; conceivably, redistribution might partially mask a flow abnormality if the scan had to be delayed after injection.

$^{99\text{m}}\text{Tc}$  has a half-life of 6 hr, as compared with 13 hr for  $^{123}\text{I}$ . Thus, a larger dose of  $^{99\text{m}}\text{Tc}$  may be given, which results in a higher photon flux with better statistics. Because of this short half-life,  $^{99\text{m}}\text{Tc}$ -HMPAO SPECT studies may be repeated the next day to determine if a perfusion defect is reversible and therefore related to the test balloon occlusion.

$^{99\text{m}}\text{Tc}$ -HMPAO SPECT imaging is not an exact measure of rCBF because of the 0.75 extraction fraction and the small amount of back-diffusion. However, we believe that it is a reasonable method for evaluating rCBF with internal carotid

balloon test occlusion. The regional cerebral distribution of  $^{99m}\text{Tc}$ -HMPAO is qualitatively the same as  $^{14}\text{C}$ -labeled iodoantipyrine (IAP), which is a reference tracer for rCBF [14]. The relationship between changes in activity seen with  $^{99m}\text{Tc}$ -HMPAO and with  $^{133}\text{Xe}$  rCBF studies is mildly curvilinear and may be made linear with the appropriate correction factors [12]. However, it appears that a linear relationship between the cerebral uptake of  $^{99m}\text{Tc}$ -HMPAO and rCBF may not be necessary. Studies describing xenon CT CBF imaging with internal carotid artery test balloon occlusion classify patients with no clinical findings as those with normal rCBF, those with symmetric decreases in rCBF, and those with asymmetric decrease in rCBF [2, 4, 7]. Only the latter group of patients was shown to have a high risk of cerebral infarction with permanent internal carotid occlusion. Thus, the qualitative determination of asymmetric perfusion rather than the quantitative characteristics of the xenon CT CBF imaging were used in predicting the clinical outcome of patients undergoing permanent internal carotid occlusion.

Our study was able to correctly predict a good outcome with permanent internal carotid artery occlusion in four of five patients with symmetric cerebral perfusion with test occlusion who subsequently had permanent occlusion. One patient with symmetric cerebral perfusion with test occlusion had a watershed infarction after permanent internal carotid artery occlusion during severe intraoperative hypotension associated with rapid blood loss. This protocol is designed to evaluate areas of regional hypoperfusion secondary to test occlusion of the internal carotid artery. Symmetric cerebral perfusion during test occlusion suggests that no new neurologic deficit will result after permanent internal carotid artery occlusion under typical clinical conditions. However, it is reasonable to suspect that with enough hypotension and/or blood loss, decreases in rCBF may occur that are not detected with use of this protocol. Thus, care must still be taken in maintaining systemic blood pressure after permanent occlusion in all patients.

Our study was able to demonstrate clinically inapparent cerebral hypoperfusion associated with internal carotid balloon test occlusion in two patients. The previous report of the patient who had an infarction following permanent internal carotid artery occlusion in the same region of decreased rCBF seen on the xenon CT CBF study with test occlusion [7] and the close correlation between xenon CBF studies and  $^{99m}\text{Tc}$ -HMPAO SPECT imaging [12] made the likelihood of a post-occlusion infarction too high to electively occlude the internal carotid artery without a prior external carotid–internal carotid arterial bypass. The unilateral slowing of the EEG of the second patient in association with the intraoperative placement of temporary vascular clips on the internal carotid artery tended to confirm the hypothesis that reversible cerebral hypoperfusion associated with balloon test occlusion as demonstrated by the  $^{99m}\text{Tc}$ -HMPAO scan indicates that the patient is in the high risk category for cerebral infarction following permanent internal carotid occlusion.

Our study protocol produced no complications. It was adequately performed by a rotating team of neuroradiologists and neuroradiology fellows. Thus, it is a safe procedure that

may be performed in most hospitals that have an angiographic suite and a nuclear medicine section.

Matsuda et al. [15] described three cases of  $^{99m}\text{Tc}$ -HMPAO brain SPECT imaging with manual compression of the common carotid artery. The  $^{99m}\text{Tc}$ -HMPAO cerebral perfusion scan was performed without compression, the common carotid artery was compressed manually for 5 min without the patient moving his or her head, and then the cerebral perfusion scan was repeated. The first scan was subtracted from the second to demonstrate asymmetric decrease in cerebral perfusion associated with the compression. Two of the three cases showed asymmetric decreases in rCBF; however, none of the three patients went on to permanent carotid artery occlusion.

The protocol described by Matsuda et al. differs from our protocol in several ways. Manual compression of the common carotid artery does not produce internal carotid artery occlusion as well as balloon test occlusion of the internal carotid artery. Clinical neurologic deficits may not occur until after 15 min of test occlusion [16], suggesting that the changes in collateral cerebral circulation may not be stable until that time. This is why we waited at least 15 min after the start of the test balloon occlusion before injecting the  $^{99m}\text{Tc}$ -HMPAO. The protocol described by Matsuda et al. requires every patient to have two  $^{99m}\text{Tc}$ -HMPAO cerebral perfusion scans. The vast majority of our patients (88%) had symmetric cerebral perfusion with internal carotid test balloon occlusion; consequently only two patients (12%) needed a second scan to evaluate for reversibility of the focal hypoperfusion.

In conclusion, our study suggests that  $^{99m}\text{Tc}$ -HMPAO cerebral perfusion SPECT imaging in association with test balloon occlusion of the internal carotid artery may be a safe method that is readily available in most radiology departments for detecting clinically inapparent focal cerebral hypoperfusion that may result in cerebral infarction after permanent internal carotid artery occlusion. While the number of patients we studied is small, our results suggest that a symmetric  $^{99m}\text{Tc}$ -HMPAO cerebral perfusion scan with test balloon occlusion predicts a good outcome after permanent internal carotid artery occlusion. It is a more sensitive test for focal cerebral hypoperfusion than balloon test occlusion and clinical neurologic evaluation alone. Preliminary data suggest that reversible asymmetric cerebral hypoperfusion demonstrated by  $^{99m}\text{Tc}$ -HMPAO SPECT imaging performed with internal carotid artery test balloon occlusion indicates that the patient is in a high risk category for cerebral infarction following permanent occlusion of the internal carotid artery unless preceded by external carotid–internal carotid or internal carotid–internal carotid arterial bypass.

#### ACKNOWLEDGMENT

We thank Michael White for his enthusiasm and his assistance in carrying out this study.

#### REFERENCES

1. Riggs HE, Rupp C. Variation in form of circle of Willis. *Arch Neurol* 1963;8:24–30
2. de Vries EJ, Sekhar LN, Horton JA, et al. A new method to predict safe resection of the internal carotid artery. *Laryngoscope* 1990;100:85–88

3. Gonzalez CF, Moret J. Balloon occlusion of the carotid artery prior to surgery for neck tumors. *AJNR* **1990**;11:649-652
4. Steed DL, Webster MW, DeVries EJ, et al. Clinical observations on the effect of carotid artery occlusion on cerebral blood flow mapped by xenon computed tomography and its correlation with carotid artery back pressure. *J Vasc Surg* **1990**;11:38-44
5. Kelly JJ, Callow AD, O'Donnell TF, et al. Failure of carotid stump pressures. Its incidence as a predictor for a temporary shunt during carotid endarterectomy. *Arch Surg* **1979**;114:1361-1366
6. Lenzi GL, Frackowiak RSJ, Jones T. Cerebral oxygen metabolism and blood flow in human cerebral ischemic infarction. *J Cereb Blood Flow Metab* **1982**;2:321-335
7. Erba SM, Horton JA, Latchaw RE, et al. Balloon test occlusion of the internal carotid artery with stable xenon/CT cerebral blood flow imaging. *AJNR* **1988**;9:533-538
8. Jones TH, Morawetz RB, Crowell RM, et al. Thresholds of focal cerebral ischemia in awake monkeys. *J Neurosurg* **1981**;54:773-782
9. Morioka T, Matsushima T, Fujii K, Fukui M, Hasuo K, Hisashi K. Balloon test occlusion of the internal carotid artery with monitoring of compressed spectral arrays (CSAs) of electroencephalogram. *Acta Neurochir* **1989**;101:29-34
10. Jawad K, Miller JD, Wyper DJ, Rowan JO. Measurement of CBF and carotid artery pressure compared with cerebral angiography in assessing collateral blood supply after carotid ligation. *J Neurosurg* **1977**;46:185-196
11. Giller CA, Purdy P, Lindstrom WW. Effects of inhaled stable xenon on cerebral blood flow velocity. *AJNR* **1990**;11:177-182
12. Andersen AR, Friberg HH, Schmidt JF, Hasselbalch SG. Quantitative measurements of cerebral blood flow using SPECT and Tc-99m-d,l-HM-PAO compared to xenon-133. *J Cereb Blood Flow Metab* **1988**;8 (Suppl 1):S69-S81
13. Sharp PF, Smith FW, Gemmell HG, et al. Technetium-99m HM-PAO stereoisomers as potential agents for imaging regional cerebral blood flow: human volunteer studies. *J Nucl Med* **1986**;27:171-177
14. Neirinckx RD, Canning LR, Piper IM, et al. Technetium-99m d,l-HM-PAO: a new radiopharmaceutical for SPECT imaging of regional cerebral blood perfusion. *J Nucl Med* **1987**;28:191-202
15. Matsuda H, Higashi S, Asli IN, et al. Evaluation of cerebral collateral circulation by technetium-99m HM-PAO brain SPECT during Matas test: report of three cases. *J Nucl Med* **1988**;29:1724-1729
16. Meinig G, Gunther R, Ulrich P, et al. Reduced risk of ICA ligation after balloon occlusion test. *Neurosurg Rev* **1982**;5:95-98

The reader's attention is directed to the commentary on this article, which appears on pages 1053-1054.