

Are your **MRI contrast agents** cost-effective?

Learn more about generic **Gadolinium-Based Contrast Agents**.



FRESENIUS  
KABI

caring for life

# AJNR

## **Micro-arteriovenous malformations of the brain: superselective angiography in diagnosis and treatment.**

R Willinsky, K TerBrugge, W Montanera, C Wallace and S  
Aggarwal

This information is current as  
of April 19, 2024.

*AJNR Am J Neuroradiol* 1992, 13 (1) 325-330  
<http://www.ajnr.org/content/13/1/325>

# Micro-Arteriovenous Malformations of the Brain: Superselective Angiography in Diagnosis and Treatment

Robert Willinsky,<sup>1,3</sup> Karel TerBrugge,<sup>1,3</sup> Walter Montanera,<sup>1</sup> Chris Wallace,<sup>2,3</sup> and Shashi Aggarwal<sup>1</sup>

**Purpose:** We assessed the usefulness of superselective angiography in patients with micro-arteriovenous malformations. **Patients and Methods:** Five patients had superselective angiography for either diagnosis or treatment of brain arteriovenous malformations having a nidus of less than 1 cm. All patients presented with an intracerebral hematoma. **Results:** In one patient superselective angiography confirmed the presence of a shunt that was suspected due to visualization of an early vein on the follow-up angiogram; in another patient superselective angiography was helpful in defining the topography of the malformation; in the remaining three patients, superselective angiography was used for embolization of the malformation. We were unsuccessful in achieving a complete angiographic cure in these 3; however, superselective angiography revealed an aneurysm in one that was obliterated by the liquid adhesive embolic agent. **Conclusion:** With the recent advances in microcatheters, superselective angiography has a promising role in defining the topography and angioarchitecture of micro-arteriovenous malformations. Micro-arteriovenous malformations may not be angiographically evident at the time of initial hemorrhage due to the hematoma. With future technical advances it may be possible to completely obliterate these malformations by embolization alone.

**Index terms:** Arteriovenous malformations, cerebellar; Arteries, therapeutic blockade; Cerebral angiography, indications

AJNR 13:325-330, January/February 1992

Micro-arteriovenous malformations (mAVMs) of the brain have been defined as those AVMs with a nidus less than a centimeter in size (1). They usually present with an intracerebral hematoma (ICH) (1, 2). Early angiography may not show the AVM but when the hematoma has resolved the AVM may become evident on repeat angiography (1). Often the nidus itself is not perceptible, but an early draining vein is evident at the site of the hematoma (1).

From a series of 150 patients with brain AVMs explored and/or treated at our institution between 1984 and 1990, 15 patients had mAVMs. We

have used superselective angiography (SA) in four of these 15 patients for the purpose of either confirming the diagnosis or performing embolization. SA was also used in an additional patient with an AVM having a 1-cm residual nidus after incomplete surgical resection of an initially larger AVM. This report will analyze the usefulness of SA in these five patients.

## Methods

Five patients with brain AVMs having a nidus of less than 1 cm had SA of the main feeding pedicle to the AVM. All patients presented with an ICH at the site of the AVM. The age of the patients ranged from 16 to 66 years (mean of 38) and all were male. The locations of the AVMs included superior vermis (two patients), posterior temporal (one patient), medial occipital (one patient), and frontal-opercular (one patient). SA was done using a femoral approach with a 5-French thin-walled guiding catheter (Ingenor, Paris, France) placed in either the internal carotid artery or the vertebral artery. Full systemic heparinization was used with reversal by protamine at the end of the procedure. All patients were sedated using neuroleptic anesthesia. A Tracker-18 catheter (Target Therapeutics,

Received February 27, 1991; revision requested May 20; revision received July 19; final acceptance August 7.

<sup>1</sup> Department of Radiology, Toronto Western Hospital, 399 Bathurst St, Toronto, Ontario, Canada M5T 2S8. Address reprint requests to R. A. Willinsky, MD.

<sup>2</sup> Department of Surgery, Division of Neurosurgery, Toronto Western Hospital, Toronto, Canada.

<sup>3</sup> University of Toronto Brain Vascular Malformation Study Group, Toronto, Canada.

AJNR 13, 325-330, Jan/Feb 1992 0195-6108/92/1301-0325

© American Society of Neuroradiology



San Francisco, CA) was used in one patient while in four Mini-Torquer catheters (Ingenor) were used. Taper (0.016/0.013 inches) or Seeker (0.014/0.014 inches) guidewires (Target Therapeutics) were used. Three patients were embolized with a mixture of *N*-butyl cyanoacrylate (NBCA), lipiodol, and tantalum powder (0.5 g). Slight adjustments were made in the NBCA:lipiodol ratios in an attempt to vary the polymerization times. During fluoroscopy, if the flow through the AVM was assessed as relatively slow, we increased the proportion of lipiodol to try to lengthen the time of polymerization.

## Results

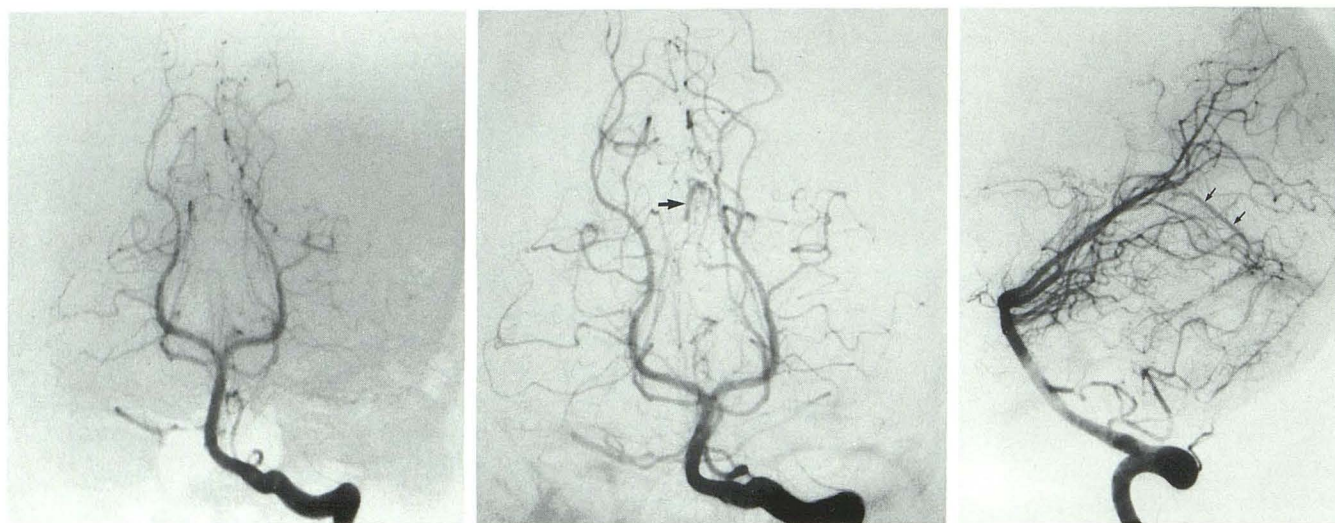
### Case 1

A 29-year-old man presented with an acute cerebellar syndrome. Computed tomography (CT) showed a 3-cm cerebellar hematoma and hydrocephalus. Cerebral angiography failed to show a cause for the bleed (Fig. 1A). Magnetic resonance (MR) imaging 2 months later, showed that the hematoma cavity had become a cleft

and there was no sign of either enlarged vessels or cavernoma. A repeat vertebral angiogram at this time suggested an early vein over the superior vermis that was not evident on the initial angiogram (Figs. 1B and 1C). SA with a Tracker-18 confirmed the presence of a shunt (Fig. 1D). Clinically, the patient was asymptomatic and neurologically normal. Embolization, microneurosurgery, and stereotactic radiosurgery were discussed with the patient but he initially refused any treatment. He was asymptomatic at his 9-month clinic visit and now wants to undergo an attempt at embolization treatment.

### Case 2

A 66-year-old man presented acutely with a headache that prompted a CT scan that revealed a 3-cm ICH medial to the atria of the lateral ventricle. Flow-enhanced images on the MR suggested an enlarged vessel in the wall of the



**A**

Fig. 1. Case 1, early angiography negative.

A, AP vertebral angiogram is normal at the time of the hematoma.

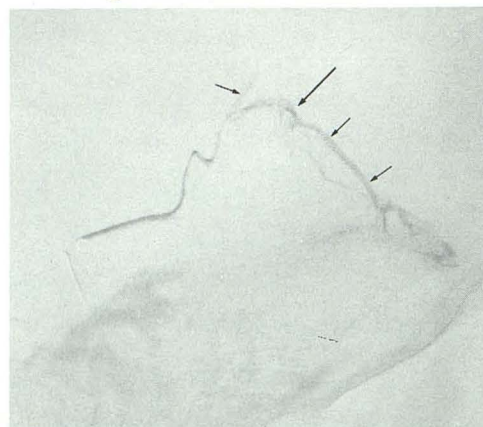
B, Repeat AP vertebral angiogram 2 months later shows an early draining superior vermian vein (*arrow*).

C, Lateral left vertebral angiogram at this time shows the early draining vein (*arrows*).

D, Superselective angiography in the lateral projection further defines the site of the shunt (*long arrow*) with its inferior and superior drainage (*short arrows*).

**B**

**C**



**D**



hematoma cavity. Cerebral angiography 3 weeks after the ictus revealed a medial occipital mAVM (Fig. 2A). At that time the patient was clinically asymptomatic and neurologically intact. Treatment options were discussed and an attempt at embolization was elected. SA with a Mini-torquer revealed an aneurysm on the feeding pedicle (Figs. 2B, 2C, and 2D). A mixture of NBCA:lipiodol (34:66) was injected into the feeding pedicle. Part of the nidus, the aneurysm, and the feeding artery were occluded. Six weeks later, angiography showed a small residual nidus (Fig. 2E). Stereotactic radiosurgery was proposed but the patient refused any further treatment. He was clinically asymptomatic at a 9-month follow-up visit.

### Case 3

A 38-year-old man presented with a 4-cm ICH in the left temporal lobe. Clinically the patient had alexia without agraphia and a superior quadrantanopsia. Angiography showed a mAVM in the left posterior temporal lobe. MR clearly showed the topography of the bleed and the flow-enhanced sequences detected prominent vessels in the inferior wall of the hematoma cavity. At our multidiscipline Brain AVM clinic it was decided to try embolization as the initial treatment. Using the Mini-torquer, we were able to select the feeding branch to the AVM. A mixture of NBCA:lipiodol (40:60) was injected with good penetration of the nidus. Angiography 2 months later showed 90% obliteration of the AVM. Stereotactic radiosurgery was then proposed.

### Case 4

A 42-year-old man presented with a 3-cm ICH in the right frontal lobe adjacent to the sylvian fissure. Angiography detected a mAVM in the anterior aspect of the sylvian fissure. It was decided to explore this AVM with SA. Selective catheterization with the Mini-torquer better defined the topography of the AVM. Embolization was not performed since branches to healthy brain could not be avoided. The mAVM was successfully surgically removed.

### Case 5

A 16-year-old boy initially presented at age 15 with a cerebellar hemorrhage that required emer-

gency evacuation of the clot. At the time of surgery a 3- to 4-cm vermian AVM was resected. Angiography 2 weeks later showed no residual AVM. Fourteen months later he suffered a second intracerebellar bleed. Angiography showed a residual AVM with a nidus less than 1 cm (Figs. 3A and 3B). SA using a Mini-torquer was done (Figs. 3C and 3D) and the AVM was embolized with NBCA:lipiodol (40:60). Mild spasm at the time of injection prevented good penetration of the nidus. A residual nidus was evident at this time. The patient was sent for stereotactic radiosurgery.

## Discussion

The diagnostic value of SA in brain AVMs is related to analysis of the angioarchitecture (3, 4). In particular, SA clarifies the presence or absence of dysplastic aneurysms on feeding vessels, differentiates intralesional aneurysms from venous ectasias, and delineates arteriovenous fistulae within the nidus (3, 4). In this report, we used SA in five patients with small AVMs (nidus less than 1 cm) to determine the site of the shunt in one patient and for the purpose of possible embolization in four patients. Of the three patients who had MR, the AVM was not evident in one case. In the other two cases, MR showed prominent vessels in the wall of the hematoma cavity on spin-echo and gradient-echo sequences. In all cases SA was useful to better define the angioarchitecture of the AVM.

Brain AVMs associated with flow-related, intralesional, or dysplastic aneurysms have an increased incidence of hemorrhage (5, 6). In one of our five patients (case 5), SA discovered an aneurysm on the feeding pedicle that was not suspected on the initial vertebral angiogram. In treating this patient with embolization we were able to obliterate the aneurysm immediately and thus may have eliminated the major risk factor for rebleed.

In four of the five patients the mAVM was evident on the initial angiogram following the diagnosis of an ICH. In one patient, the AVM was only evident at the repeat angiogram 2 months following the bleed. For follow-up of an unexplained ICH, we suggest an MR at 6–8 weeks to rule out a cavernoma or small tumor not evident at the initial MR. If only a hemosiderin cleft (slit-like cavity lined by hemosiderin) is evident, then a repeat angiogram should be done.

Embolization is an integral part of the treat-



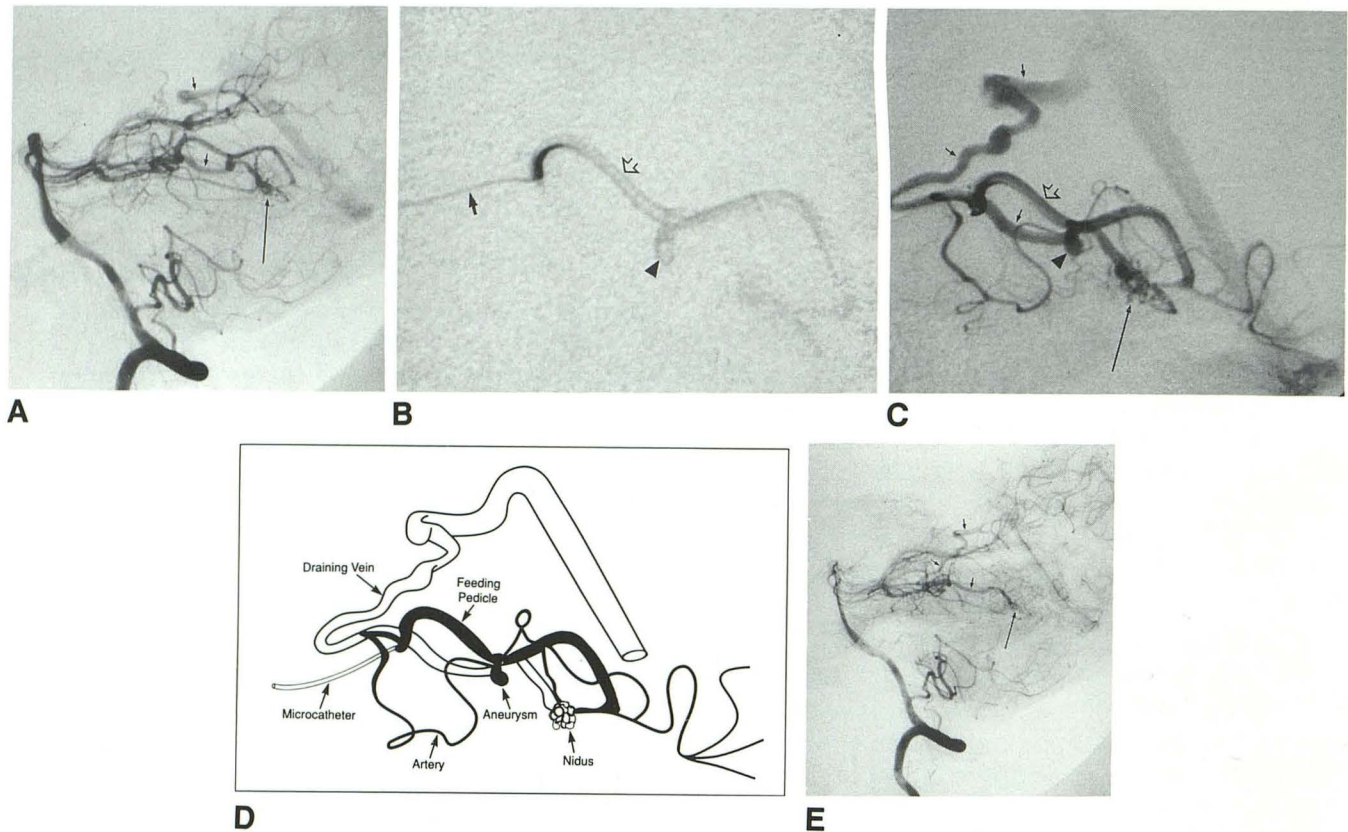


Fig. 2. Case 2, Aneurysm confirmed on SA.

A, Lateral left vertebral angiogram shows the nidus of the mAVM (*long arrow*) in the temporal-occipital region with its early draining vein (*short arrows*).

B, SA demonstrates an aneurysm (*arrowhead*) on the feeding pedicle (*open arrow*) and position of microcatheter (*arrow*).

C, Later phase of SA shows the feeding pedicle (*open arrow*), aneurysm (*arrowhead*), the nidus (*long arrow*), and the draining vein (*small arrows*).

D, Schematic of C illustrates the angioarchitecture with an aneurysm on the dominant arterial feeder and an additional smaller artery also supplying the malformation.

E, Postembolization lateral left vertebral angiogram shows that the nidus (*long arrow*) still fills, as well as the early vein (*small arrows*), but the dominant feeding pedicle with its aneurysm has been occluded.

ment armamentarium of brain AVMs (7). It can be used as the sole treatment or in conjunction with microneurosurgery or stereotactic radiosurgery (8, 9). Stereotactic radiosurgery may have a delayed protective effect against rebleed for up to 2 years, during which time the risk for rebleeding is highest (10). Small AVMs, especially those that are superficial, have been traditionally dealt with by surgery. Up until recently, mAVMs were usually discovered only at the time of surgery when a small nidus was evident in the wall of the hematoma cavity that was being decompressed (11, 12). When a mAVM is discovered at angiography to be the cause of an ICH, the best treatment modality has not been established. In patients with mAVM who have ICH, our multidiscipline team will strongly recommend treatment. Embolization was proposed for four of the five

patients in this report. A SA was possible in all four cases. In case 4, an embolization was not attempted since branches to brain would have been blocked in addition to the nidus. This patient was successfully operated on. In the other three patients embolization did not achieve a complete angiographic obliteration. This lack of success relates to the inability to place the tip of the microcatheter close to the nidus while preserving good flow. Thus residual nidus allowed other arterial branches to keep the AVM open. Two of these patients are undergoing radiosurgery and the third refused any additional treatment. No complications occurred in our five patients studied by SA or in the three patients embolized. Embolization can be done without complications as long as the feeding pedicle does not nourish a functional area of the brain. Branches to healthy



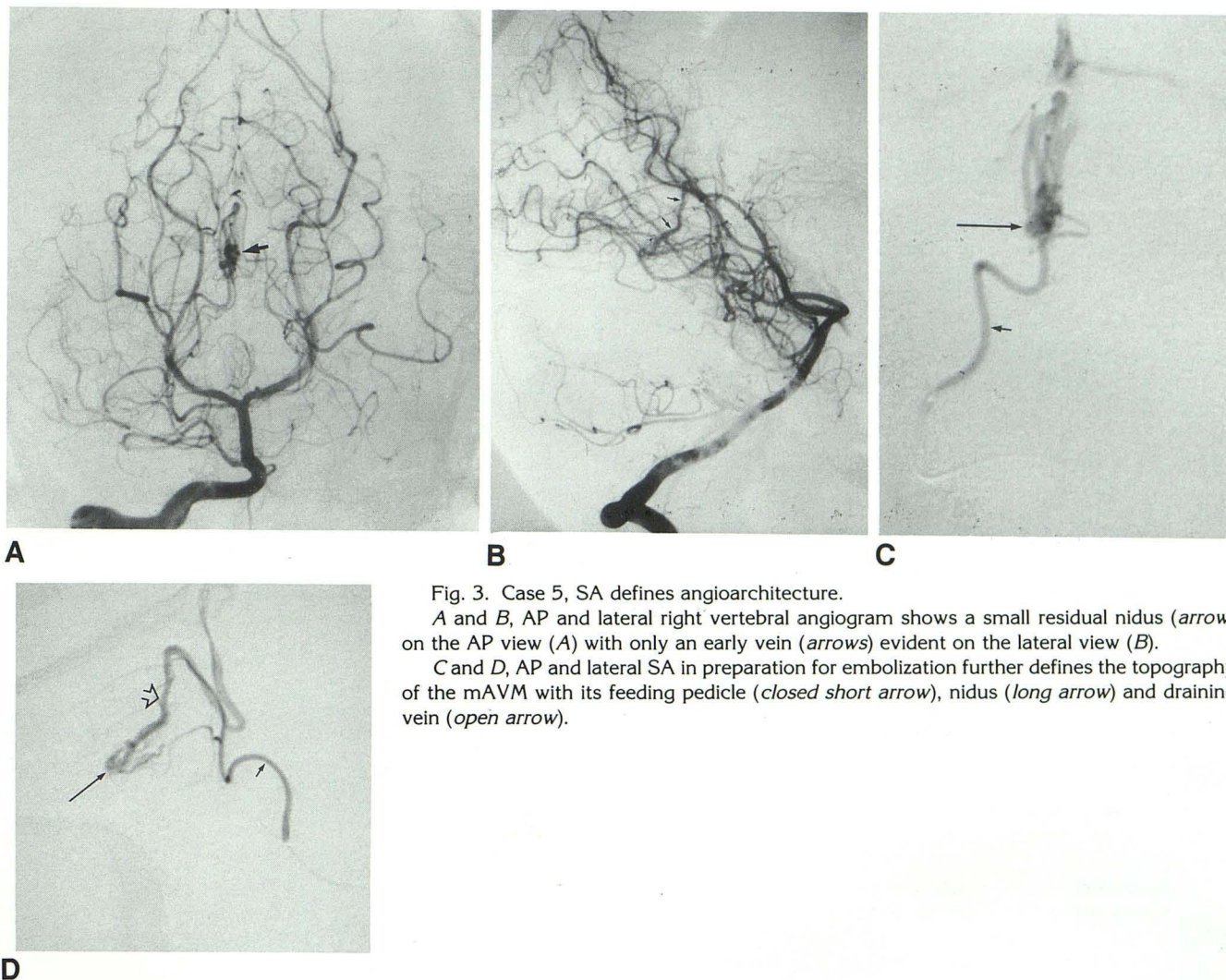


Fig. 3. Case 5, SA defines angioarchitecture.

A and B, AP and lateral right vertebral angiogram shows a small residual nidus (*arrow*) on the AP view (A) with only an early vein (*arrows*) evident on the lateral view (B).

C and D, AP and lateral SA in preparation for embolization further defines the topography of the mAVM with its feeding pedicle (*closed short arrow*), nidus (*long arrow*) and draining vein (*open arrow*).

brain can be recognized on the superselective angiogram.

Eleven of our 15 patients with mAVMs have presented with an ICH. We have found that mAVMs account for approximately 15% of our brain AVMs that have bled. We suspect that some of the previously described "angiographically occult" AVMs described in the literature were actually mAVMs that were overlooked or not evident due to the hematoma.

In summary, superselective angiography is possible in brain mAVMs. In our experience, SA's main uses are to confirm the presence of a mAVM and outline the topography of the AVM. At the present time, surgery would be the preferred treatment for those mAVMs that have bled and are accessible. When surgery is not appropriate, embolization may be useful as an adjunct to

stereotactic radiosurgery, possibly stabilizing an unstable lesion. Hopefully, with further advances in catheter technology and embolic materials, embolization alone can treat this subgroup of AVMs.

## References

1. Willinsky R, Lasjaunias P, Comoy J, Pruvost P. Cerebral micro arteriovenous malformations (mAVMs): review of 13 cases. *Acta Neurochir Wien* 1988;91:29-36
2. Yasargil MG. *Microneurosurgery*, Vol 3B. Stuttgart: Thieme, 1987:18-19
3. Lasjaunias P, Manelfe C, Chiu M. Angiographic architecture of intracranial vascular malformations and fistulas: pretherapeutic aspects. *Neurosurg Rev* 1986;9:253-263
4. Vinuela F, Fox A, Debrun G, Pelz D. Preembolization superselective angiography role in the treatment of brain arteriovenous malformations with isobutyl-2 cyanoacrylate. *AJNR* 1984;5:765-769
5. Lasjaunias P, Piske R, TerBrugge K, Willinsky R. Cerebral arteriove-

- nous malformations (mAVM) and associated arterial aneurysms (AA): analysis of 101 C.AVM cases, with 37 AA in 23 patients. *Acta Neurochir (Wien)* 1988;91:29-36
6. Willinsky R, Lasjaunias P, TerBrugge K, Pruvost P. Brain arteriovenous malformations: analysis of the angio-architecture in relationship to hemorrhage (based on 152 patients explored and/or treated at the hospital de Bicetre between 1981 and 1986). *J Neuroradiol* 1990;15:225-237
  7. Fox A, Pelz D, Lee D. Arteriovenous malformations of the brain: recent results of endovascular therapy. *Radiology* 1990;177:51-57
  8. Andrews B, Wilson C. Staged treatment of arteriovenous malformations of the brain. *Neurosurgery* 1987;21:314-323
  9. Dawson R, Tarr R, Hecht S, Jungreis C, et al. Treatment of arteriovenous malformations of the brain with combined embolization and radiosurgery: results after 1 and 2 years. *AJNR* 1990;11:857-864
  10. Steiner L. Radiosurgery in cerebral arteriovenous malformations. In: Flamm E, Fein J, eds. *Textbook of cerebrovascular surgery*. Vol 4. New York: Springer Verlag, 1986:1161-1215
  11. Margolis G, Odom G, Woodhall B, et al. The role of small angiomatous malformations in the production of intracerebral hematomas. *J Neurosurg* 1951;8:564-575
  12. Krayenbuhl H, Siebenman R. Small vascular malformations as a cause of primary intracerebral hemorrhage. *J Neurosurg* 1965;22:7-20