

Are your **MRI contrast agents** cost-effective?

Learn more about generic **Gadolinium-Based Contrast Agents**.



**FRESENIUS
KABI**

caring for life

AJNR

Treatment of carotid cavernous fistulas: a new balloon delivery system.

F Wessbecher, R P Hartling, M Nieves and J M Eskridge

AJNR Am J Neuroradiol 1992, 13 (1) 331-332

<http://www.ajnr.org/content/13/1/331.citation>

This information is current as
of April 17, 2024.

Treatment of Carotid Cavernous Fistulas: A New Balloon Delivery System

Francis Wessbecher,¹ Ross P. Hartling,¹ Miguel Nieves,¹ and Joseph M. Eskridge¹

Summary: A new catheter/guidewire detachable balloon delivery system is described that has proved helpful in the treatment of inaccessible carotid cavernous fistulas.

Index terms: Fistula, carotid-cavernous; Fistula, therapeutic blockade; Interventional instrumentation, guidewires

Direct carotid cavernous fistulas (CCFs) have been successfully treated with detachable flow-directed balloons for many years (1, 2). However, there remains a significant number of fistulas that cannot be entered with these flow-directed balloons. Usually this is because the fistula orifice is small or the orifice is located at such an angle to preclude balloon entry. In such instances, difficult transvenous approaches may be attempted (3). In other cases, carotid occlusion may be the only alternative, and has been reported in 20%–60% of cases (2, 4, 6). Recently, we began using a

new catheter/guidewire system to deliver detachable balloons and successfully treat previously inaccessible fistulas.

Materials and Methods

Ten post-traumatic CCFs in nine patients were referred for balloon occlusion. In each case, a 7.3 French coaxial Hieshima catheter was placed in the carotid artery. In each patient, multiple attempts to place flow-directed detachable balloons into the fistula with a standard 4.0–2.0 French coaxial catheter were unsuccessful.

After the flow-directed technique had failed in each of these cases, these CCFs were treated using detachable balloons which were delivered by the catheter/guidewire system. An extended tip 2.2 French Tracker™-18 catheter (Target Therapeutics, Inc) was steamed into a C-shaped or S-shaped curve to conform to the anatomy of the cavernous internal carotid artery (Fig. 1). This was subsequently filled with isosmolar contrast medium. A J-shaped or C-shaped curve was formed on the distal end of a .016 guidewire, and advanced to the end of the catheter (Fig. 1). A 1.5 or 1.8 silicone elastomer balloon (Interventional Therapeutics) of low or medium detachable resistance was pretested with isomolar contrast medium and placed on the tip of the catheter. The wire was advanced a few millimeters to the very tip of the balloon and locked into position with a proximal torque device.

The catheter/wire/balloon system was advanced through the Hieshima catheter to the level of the fistula. Using the torque device, the fistula orifice was searched for, and once found, the system was advanced into the fistula. The guidewire was then withdrawn slowly while dripping metrizamide into the hub of the catheter. The balloon was inflated (Fig. 2) and detached.

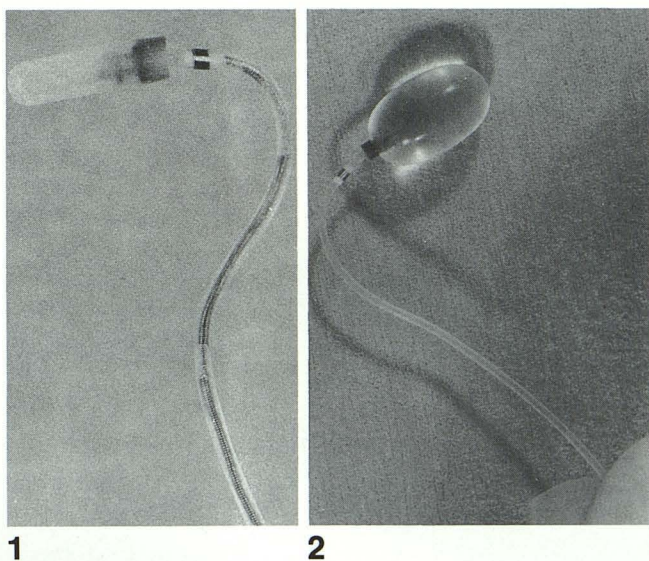


Fig. 1. Catheter has been steamed and wire shaped into an S-curve.

Fig. 2. ITC balloon attached to Tracker catheter.

Results

All 10 CCFs were successfully closed with this new technique. All patients have done well without recurrent symptoms with at least 12-month

Received October 30, 1990; revision requested March 9, 1991; revision received June 28, final acceptance July 23.

Presented at the 28th Annual Meeting of the ASNR, Los Angeles, California, March 19–23, 1990.

¹ All authors: Department of Radiology, University of Washington Medical Center, Seattle, WA 98195. Address reprint requests to J. M. Eskridge.

follow-up. The final patient had bilateral fistulas requiring three separate procedures and multiple balloons but these were also successfully closed.

Discussion

Treatment of the carotid cavernous fistulas was revolutionized with development of endovascular detachable balloons. However, there remains a significant number of fistulas that cannot be entered with flow-directed balloons. By utilizing new catheter/guidewire systems, previously inaccessible fistulas can be successfully treated, reducing the need for transvenous approaches or carotid occlusion.

The advantages of this technique are the ability to preshape the catheter and wire to conform to the anatomy of the cavernous internal carotid artery, and the ability to use a torque device to search for and direct the balloons into the fistulas.

There are a few important points that we have found helpful with this technique. First, it is important to use an extended tip Tracker catheter, which is a standard Tracker catheter with the radioopaque marker moved 2 cm from the tip of the catheter. The larger distal tip (metal ring) of the regular Tracker catheter makes balloon detachment more difficult. Second, the catheter and wire need to be preshaped to conform to the anatomy of the cavernous internal carotid artery. If initial attempts to enter the fistula are unsuccessful, another shape should be formed until an appropriate shape is achieved. Third, it is important to advance the guidewire to the tip of the balloon before locking it into place with the torque device. This prevents folding of the balloon,

which may prevent fistula entry. In addition, once the torque device is locked into position, it should not be unlocked during the rest of the procedure, as inadvertent advancement of the wire may prematurely dislodge or puncture the balloon. Finally, once the balloon is in the fistula, it is important to slowly withdraw the guidewire by dripping solution into the catheter. This prevents aspiration of air into the catheter dead space that might enter the balloon with subsequent inflations.

Conclusion

The catheter/guidewire detachable balloon delivery system is a new and promising technique in the treatment of carotid cavernous fistulas. We have found this very helpful in treating difficult CCFs that were refractory to flow-directed balloons.

References

1. Serbinenko, SA. Balloon catheterization and occlusion of major cerebral vessels. *J Neurosurg* 1974;41:125-145
2. DeBrun G, Lacour P, Vinuela F, Fox A, Drake CG, Caron JP. Treatment of fifty-four traumatic carotid cavernous fistulas. *J Neurosurg* 1981;55:678-692
3. Halbach VV, Higashida RT, Hieshima GB, Hardin CW, Yang PJ. Transvenous embolization of direct carotid cavernous fistulas. *AJNR* 1988;9:741-747
4. Norman DH, Newton TH, Edwards MS, DeCaprio V. Carotid cavernous fistulas: closure with detachable silicon balloons. *Radiology* 1983;149:149-157
5. Kikuchi Y, Strother CM, Boyer M. New catheter for endovascular interventional procedures. *Radiology* 1987;165:870-871
6. DeBrun G, Vinuela F, Fox A, Davis K, Aikn H. Indications for treatment and classification of 132 carotid cavernous fistulas. *Neurosurgery* 1988;22:285-289