

The **next generation** GBCA
from Guerbet is here

Explore new possibilities >

Guerbet | 

© Guerbet 2024 GUOB220151-A

AJNR

Origin of the right vertebral artery from the left side of the aortic arch proximal to the origin of the left subclavian artery.

B A Wasserman, D J Mikulis and J V Manzione

AJNR Am J Neuroradiol 1992, 13 (1) 355-358

<http://www.ajnr.org/content/13/1/355.citation>

This information is current as
of March 20, 2024.

Origin of the Right Vertebral Artery from the Left Side of the Aortic Arch Proximal to the Origin of the Left Subclavian Artery

Bruce Alan Wasserman,¹ David John Mikulis,² and James V. Manzione³

Summary: The authors describe a patient in whom there was an anomalous origin of the right vertebral artery from the aortic arch, proximal to the origin of the left subclavian artery—another potential vertebral origin anomaly that one may encounter when performing cerebral angiography.

Index terms: Arteries, abnormalities and anomalies; Arteries, vertebral; Cerebral angiography

The right vertebral artery most commonly originates from the right subclavian artery. There are a variety of anomalous origins of the right vertebral artery described throughout the literature (1–14); however, in most cases the artery arises from a vessel on the right side of the aortic arch. There have only been three reports of the right vertebral artery crossing over from an origin on the left side of the aortic arch, and in all cases the origin was distal to the origin of the left subclavian artery (1–3). We report a case in which the right vertebral artery originates from the left side of the arch and crosses to the right, but the origin is proximal to the left subclavian artery (Figs. 1, 2, and 3). An embryologic derivation is described that can adequately account for each variant. Understanding the variations in anatomy of the right vertebral artery can help avoid problems when a variant is present during cerebral angiography or a surgical procedure.

Case Report

An elderly man with a recent history of a cerebrovascular accident was referred to the Massachusetts General Hospital for evaluation of his carotid arteries. Arch aortography in right posterior oblique projection (Fig. 2) was performed and the subsequent selective views of the subclavian arteries (Fig. 3) demonstrated the origin of the right

vertebral artery directly from the aortic arch proximal to the origin of the left subclavian artery. This anomaly prompted a review of the literature and the derivation of an embryologic explanation.

Discussion

Variations in the origin of the vertebral artery usually occur on the left (1, 4); however, a variety of anomalous origins of the right side have been reported. Table 1 lists reported variants of the origin of the right vertebral artery. The references corresponding to a particular variant report significantly different incidences, but this may be due in part to differing sample sizes.

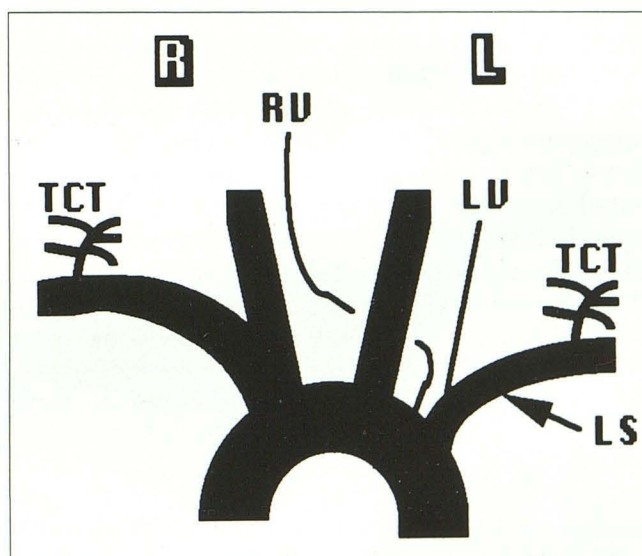


Fig. 1. Illustration of aortic arch, showing the right vertebral artery (RV) crossing from an origin on the left side. The origin is proximal to that of the left subclavian artery (LS). TCT = Thyrocervical trunk; LV = Left vertebral artery.

Received April 5, 1991; revision requested May 9; revision received September 3; final acceptance September 4.

¹ University of Rochester, School of Medicine and Dentistry, 601 Elmwood Avenue, Rochester, NY 14642. Address reprint requests to B.A. Wasserman. Permanent address: 39 Park Hill Drive, New Windsor, NY 12553.

² Department of Radiology, Neuroradiology Section, Massachusetts General Hospital, Boston, MA 02114.

³ Department of Radiology and Surgery, University of Rochester, School of Medicine and Dentistry, Rochester, NY 14642.

AJNR 13:355–358, Jan/Feb 1992 0195-6108/92/1301-0355 © American Society of Neuroradiology

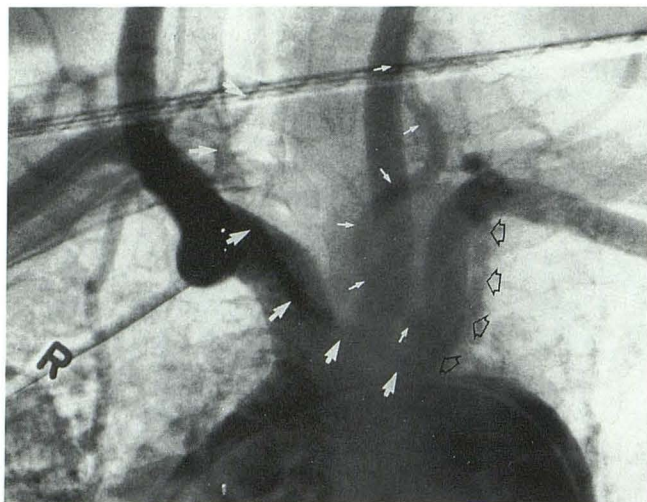


Fig. 2. Sequential images from arch aortogram (RPO projection) at different times during the filming sequence. *Large white arrows* outline the right vertebral artery as it originates just proximal to the left subclavian artery. *Small white arrows* demonstrate the low take off of the left vertebral artery from the left subclavian artery. *Open black arrows* outline the course of the left internal mammary artery.

We were unable to obtain the first report of a right vertebral artery originating from the left side of the aortic arch (Fig. 4-*I*) by Kemmetmüller (1911) (3), nor could we obtain the thesis describing a case in Dakar by Obounou-Akong (1969) (1). The three reports of this anomaly each describe the right vertebral artery originating distal to the left subclavian artery. In our case, it originated proximal to the left subclavian artery (Figs. 1, 2, and 3). Either case can be derived from the same embryologic model. Figures 5-*a* and 5-*b* illustrate the development of the aortic arch vessels. The right vertebral artery develops as a branch of the right seventh intersegmental artery. Migration of this branch onto the dorsal aorta

TABLE 1: References and the reported incidences corresponding with each variant depicted in Figure 4

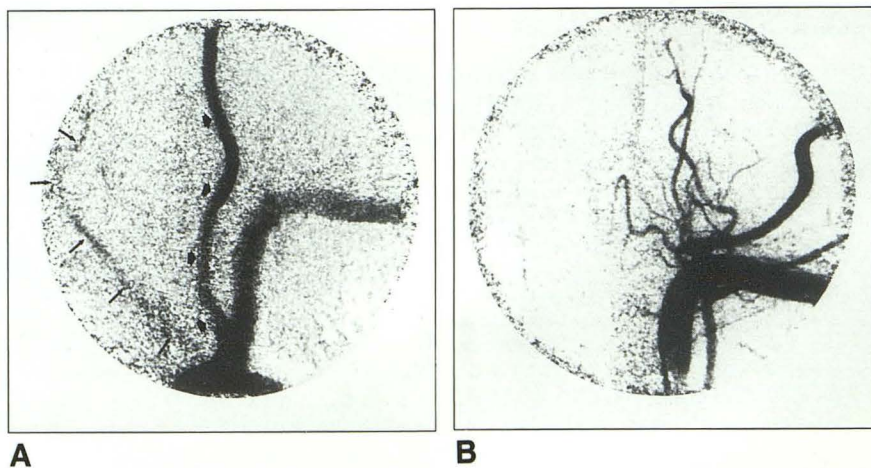
	Reported Incidences (%) / (References)
Figure 4- <i>a</i>	60-90 (1, 5-7)
<i>b</i>	1-4 (1, 5, 6)
<i>c</i>	0-24 (1, 5, 6)
<i>d</i>	0.4-13.5 (1, 5, 6)
<i>e</i>	1.1 (1, 3, 4, 8)
<i>f</i>	<1 (6)
<i>g</i>	<0.1 (6)
<i>h</i>	<1 (5, 6)
<i>i</i>	<0.1-0.8 (1-3, 6, 7, 9-13)
<i>j</i>	<1 (3, 6, 7) ^a
<i>k</i>	(3)
<i>l</i>	(1-3) (see text)

^a High incidence among Down syndrome population (see ref. 14 for additional references).

helps to account for its various origins. Some reports show the right vertebral as always originating from the dorsal aorta with no need for migration (3, 13). Figure 5-*b* shows two possible sites of origin for the right vertebral artery (I and II) and two possible obliteration zones. Various combinations of an origin site with an obliteration zone can account for a number of anomalies shown in Figure 4. For example, normally the right vertebral artery originates from site I and the dorsal aorta obliterates at site *b*, resulting in the anatomy of Figure 4-*a*. If, however, the origin is at site I and the dorsal aorta obliterates at site *a*, then we would arrive at the variant shown in Figure 4-*i*, as described by Windle et al (13). If the origin is at site II and zone *a* obliterates, the anatomy of figure 4-*j* would result. An origin at site II and obliteration of zone *b* would develop into the anatomical configuration of Figure 4-*l*, as described by Lie, after Kemmetmüller (3). If the right vertebral artery continued to migrate

Fig. 3. A, Origin injection of the left subclavian artery (anteroposterior projection) that shows the reflux of contrast material into the aortic arch with partial opacification of the right vertebral artery (*thin black arrows*), demonstrating its origin from the aorta proximal to the left subclavian artery. *Thick black arrows* demonstrate the low take off of the left vertebral artery from the left subclavian artery.

B, Selective injection of the left subclavian artery distal to the origin of the left vertebral artery demonstrates the branches of the thyrocervical trunk.



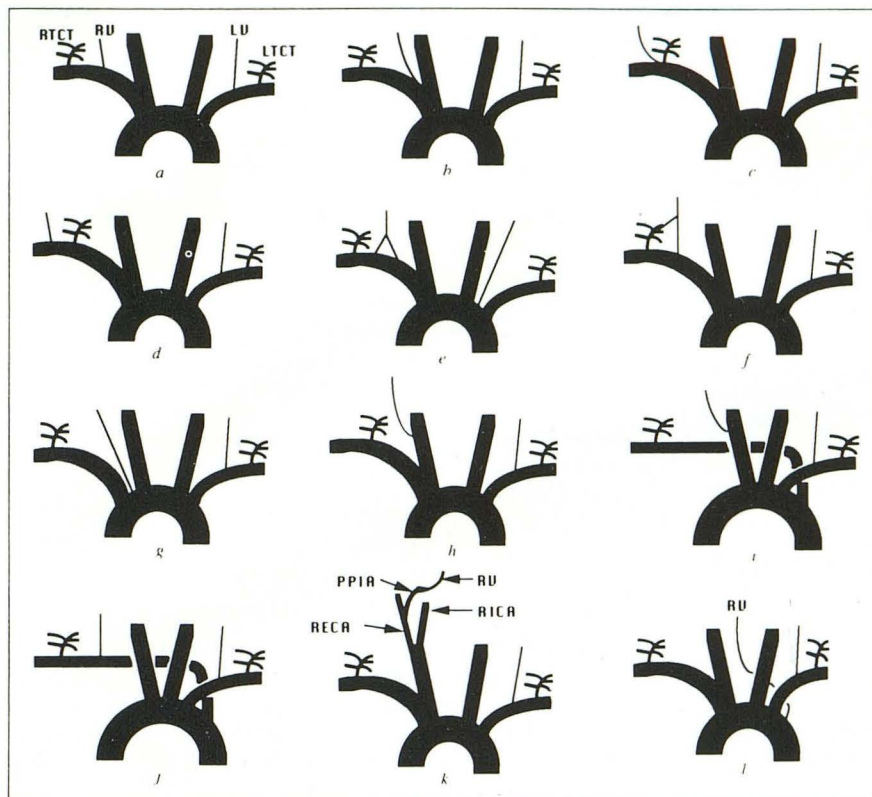


Fig. 4. *a*, Normal variant; *RTCT* = right thyrocervical trunk, *RV* = right vertebral artery, *LV* = left vertebral artery, *LTCT* = left thyrocervical trunk; *b*, origin from bifurcation of brachiocephalic trunk; *c*, originates with *RTCT*; *d*, originates lateral to *RTCT*; *e*, double origin from subclavian artery; *f*, accessory branch from *RTCT*; *g*, origin from aortic arch; *h*, origin from common carotid artery; *i*, origin from common carotid with aberrant origin of right subclavian artery; *j*, originates from normal location on right subclavian but ectopic origin of right subclavian artery; *k*, persistent proatlantal intersegmental artery (*PPIA*) joins the right external carotid artery (*RECA*) to the right vertebral artery; *l*, right vertebral artery originates from the aortic arch distal to the left subclavian artery.

beyond site II and became situated rostral to the left subclavian branch, obliteration of zone *b* would lead to the anatomy seen in our case. The right seventh intersegmental artery eventually

develops into the lateral aspect of the right subclavian artery. The cranial portion of the right dorsal aorta becomes the medial part. Cranial migration of the right vertebral can result in its

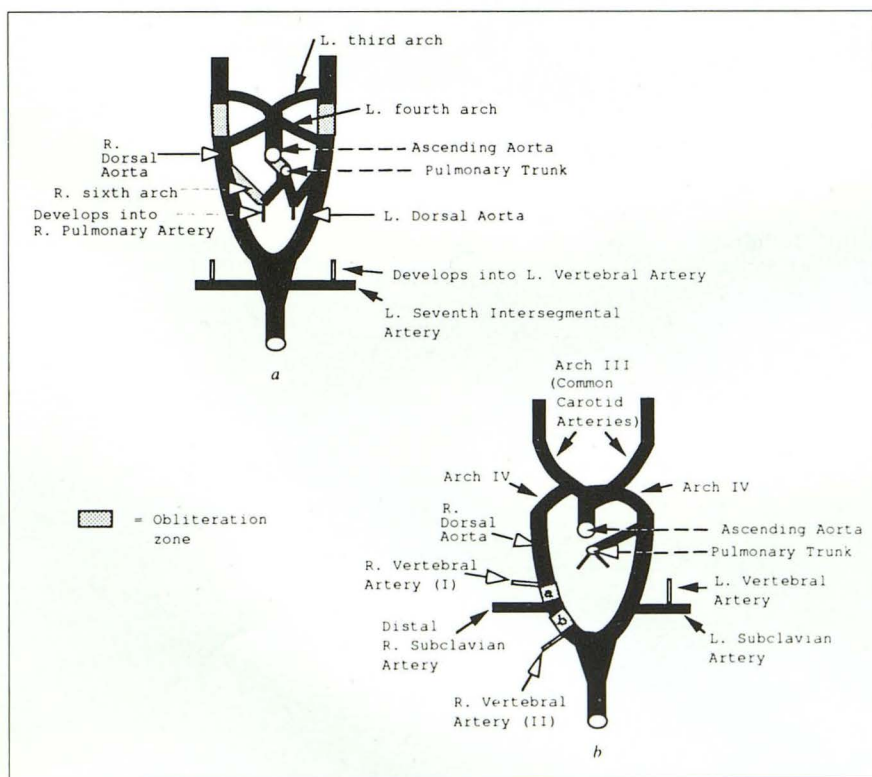


Fig. 5. *a*, Model of fetal circulation in the 10-mm embryonic stage; *b*, 14-mm embryonic stage (see text).

branching directly off the aortic arch. In addition, migration relative to the right thyrocervical trunk can lead to some of the other variants depicted in Figure 4.

Conclusion and Comments

Although reports of anomalous origins of the right vertebral artery are not common, it is likely that many are found during angiographic studies and many may go unnoticed. There is no conclusive evidence that these variants predispose to cerebrovascular disorders. However, some hypothesize that anomalies of origin and distribution of the large vessels of the aortic arch can cause changes in cerebral hemodynamics that may lead to cerebral abnormalities (12). An understanding of the variability of the vertebral artery remains most important in angiography and in surgical procedures where an incomplete knowledge of the anatomy can lead to complications.

References

1. Argenson C, Francke JP, Sylla S, Dintimille H, Papasian S, di Marino V. The vertebral arteries (Segments V1 and V2). *Anat Clin* 1980;2:29-32
2. Newton TH, Mani RL. The vertebral artery. In: Newton TH, Potts DG, eds. *Radiology of the skull and brain: angiography*. Vol 2. Book 2. St. Louis: Mosby, 1974;1659-1672
3. Lie TA. *Congenital anomalies of the carotid arteries*. The Netherlands: Excerpta Medica Foundation, 1968;30, 84-93
4. Çavdar S, Arisan E. Variations in the extracranial origin of the human vertebral artery. *Acta Anat (Basel)* 1989;135:236-238
5. Daseler EH, Anson BJ. Surgical anatomy of the subclavian artery and its branches. *Surg Gynecol Obstet* 1959;108:149-174
6. Lippert H, Pabst R. *Arterial variations in man*. Germany: JF Bergmann Verlag München, 1985; 6, 82
7. Palmer FJ. Origin of the right vertebral artery from the right common carotid artery: angiographic demonstration of three cases. *Br J Radiol* 1977;50:185-187
8. Rath G, Prakash R. Double vertebral artery in an Indian cadaver. *Clin Anat* 1984;6:117-119
9. Ananthanarayana IA. Some anomalies of origin of the vertebral artery. *J Anat* 1928;62:121-122
10. Tan WS, Spigos DG. Right vertebral artery originating from the right common carotid. *Radiology* 1979;19:155-156
11. Stein BM, McCormic WF, Rodriguez JN, Taveras JM. Radiography of atheromatous disease involving the extracranial arteries as seen at postmortem. *Acta Radiol* 1963;1:455
12. Bernardi L, Dettori P. Angiographic study of a rare anomalous origin of the vertebral artery. *Neuroradiology* 1975;9:43-47
13. Windle WF, Zeiss FR, Adamski MS. Note on a case of anomalous right vertebral and subclavian arteries. *J Anat* 1928;62:512-514
14. Rathore MH, Sreenivasan VV. Vertebral and right subclavian artery abnormalities in the Down Syndrome. *Am J Cardiol* 1989;63:1528-1529