

Are your **MRI contrast agents** cost-effective?

Learn more about generic **Gadolinium-Based Contrast Agents**.



FRESENIUS
KABI

caring for life

AJNR

Simultaneous neurofibroma and schwannoma of the sciatic nerve.

S A Sintzoff, Jr, W O Bank, P A Gevenois, C Matos, J Noterman, J Flament-Durand and J Struyven

AJNR Am J Neuroradiol 1992, 13 (4) 1249-1252

<http://www.ajnr.org/content/13/4/1249>

This information is current as of April 19, 2024.

Simultaneous Neurofibroma and Schwannoma of the Sciatic Nerve

S. A. Sintzoff, Jr.,^{1,5} W. O. Bank,^{1,4} P. A. Gevenois,¹ C. Matos,¹ J. Noterman,² J. Flament-Durand,³ and J. Struyven¹

Summary: The authors report a case of simultaneously occurring neurofibroma and schwannoma of the sciatic nerve and discuss the complementary aspects of MR and US. The schwannoma was well-defined and showed distal enhancement on sonographic evaluation, whereas the neurofibroma was ill-defined; both tumors were hypoechoic. T1- and T2-weighted MR images revealed similar signal characteristics of the two tumors, but intense enhancement following administration of gadolinium-DTPA distinguished the schwannoma from the neurofibroma.

Index terms: Nerves, sciatic; Neuroma; Schwannoma

Schwannomas and neurofibromas are common peripheral nerve neoplasms (1, 2). Ultrasound (US) (3, 4) and magnetic resonance (MR) (5–7) have been used previously for the evaluation of such lesions. These two techniques provided complementary information in a case with the simultaneous occurrence of these two histologically different tumors on the same peripheral nerve of a patient with neither historical background nor clinical stigmata of neurofibromatosis.

Case Report

A 53-year-old woman was admitted for nonspecific, right-sided sciatic pain. Percussion of the popliteal area evoked acute pain in the territory of the external popliteal nerve (Tinel sign). US of the popliteal area was performed with an Acuson 128 computed sonography unit equipped with a 5-mHz transducer. The sonogram demonstrated two masses on the external popliteal nerve. The proximal mass was approximately 2 × 1 × 1 cm and ovoid in shape. The distal mass was rounded with a diameter of approximately 2 cm. Both tumors were hypoechoic and both showed distal sound enhancement (Fig. 1).

MR imaging was performed on a 0.5-T system (Gyrosan T5, Philips Medical Systems, Eindhoven, The Netherlands) using a wrap-around knee surface coil in order to better define the relationships between the tumors and the nerve. Each tumor was isointense to the normal nerve on T1-weighted images and hyperintense to it on proton density and T2-weighted images (Fig. 2A–2C). After intravenous gadolinium-DTPA injection, the distal mass showed intense enhancement, conserving a thin hypointense border (Fig. 2D). Physical and neurologic examination, MR of the central nervous system and skeletal radiographs failed to demonstrate any additional lesions, permitting the reasonable exclusion of neurofibromatosis types 1 and 2.

Surgical exposure demonstrated the two tumors on the external popliteal nerve (Fig. 3). The distal tumor could be enucleated easily. The proximal one, however, was infiltrative and could only be biopsied.

Histologic studies of the larger tumor revealed compact bundles of elongated cells forming tissue of the Antoni A type, with palisading of nuclei forming Verocay bodies, typical of schwannoma (Fig. 4A). The biopsy specimen of

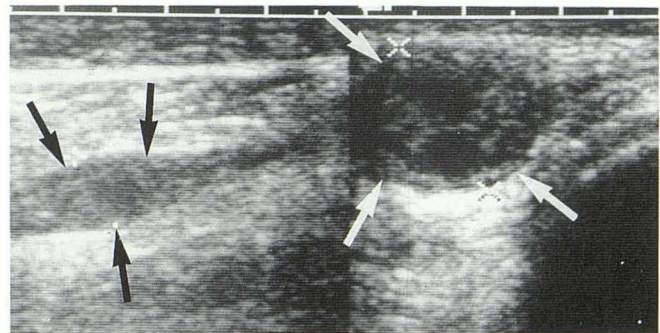


Fig. 1. Sagittal ultrasound images of the lateral aspect of the popliteal area demonstrate two masses (arrows) in connection with a nerve trunk. Both show distal sound enhancement.

Received October 8, 1991; accepted and revisions requested November 29; revisions received December 24.

¹Departments of Radiology, ²Neurosurgery, and ³Pathology, Cliniques Universitaires de Bruxelles, Hôpital Érasme, Université Libre de Bruxelles, Brussels, Belgium.

⁴Departments of Radiology and Neurosurgery, George Washington University Medical Center, Washington, DC.

⁵Address reprint requests to S. A. Sintzoff, Jr., MD, Service de Radiologie, Hôpital Érasme, 808 Route de Lennik, B 1070 Brussels, Belgium.

AJNR 13:1249-1252, Jul/Aug 1992 0195-6108/92/1304-1249 © American Society of Neuroradiology

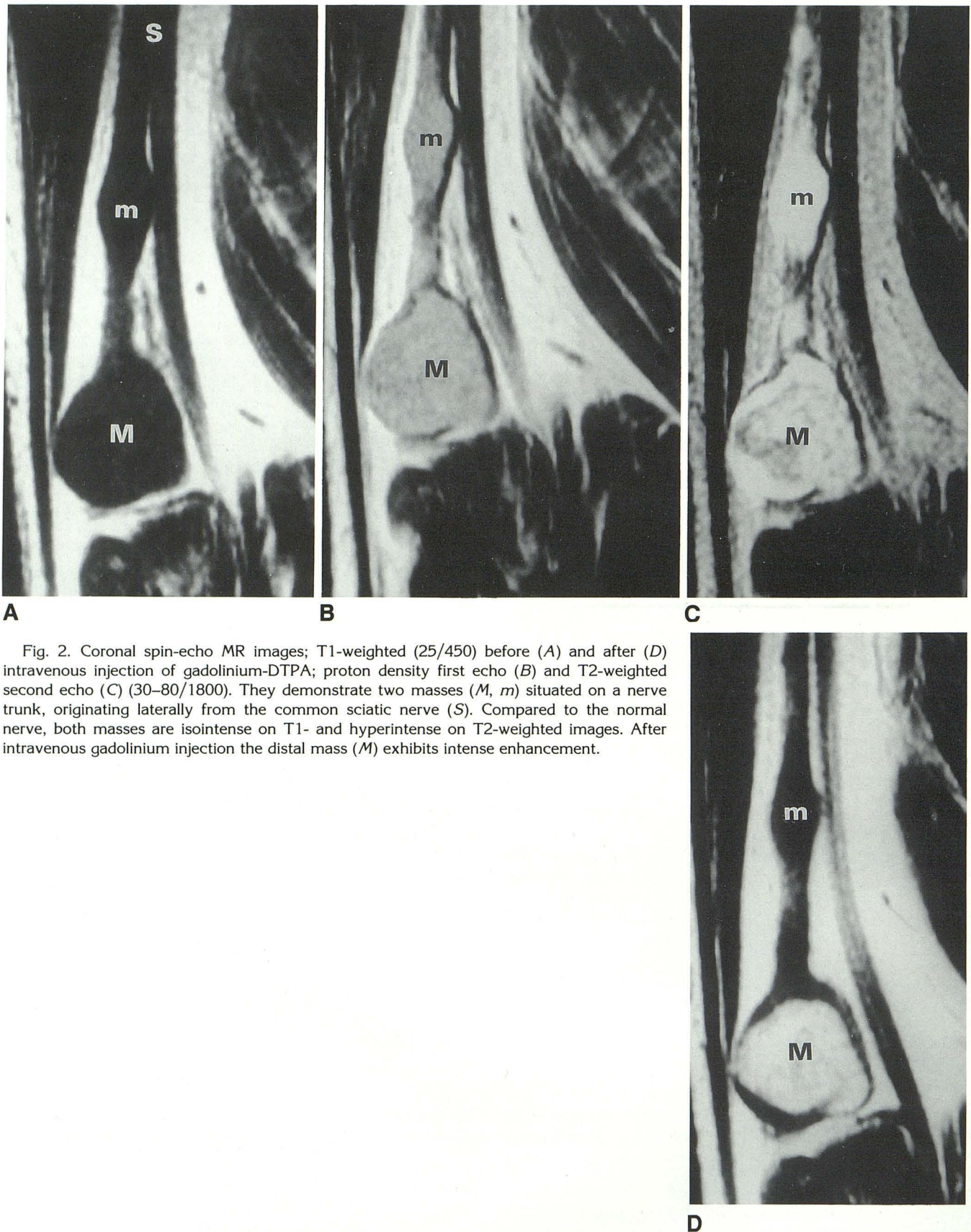


Fig. 2. Coronal spin-echo MR images; T1-weighted (25/450) before (A) and after (D) intravenous injection of gadolinium-DTPA; proton density first echo (B) and T2-weighted second echo (C) (30–80/1800). They demonstrate two masses (M, m) situated on a nerve trunk, originating laterally from the common sciatic nerve (S). Compared to the normal nerve, both masses are isointense on T1- and hyperintense on T2-weighted images. After intravenous gadolinium injection the distal mass (M) exhibits intense enhancement.

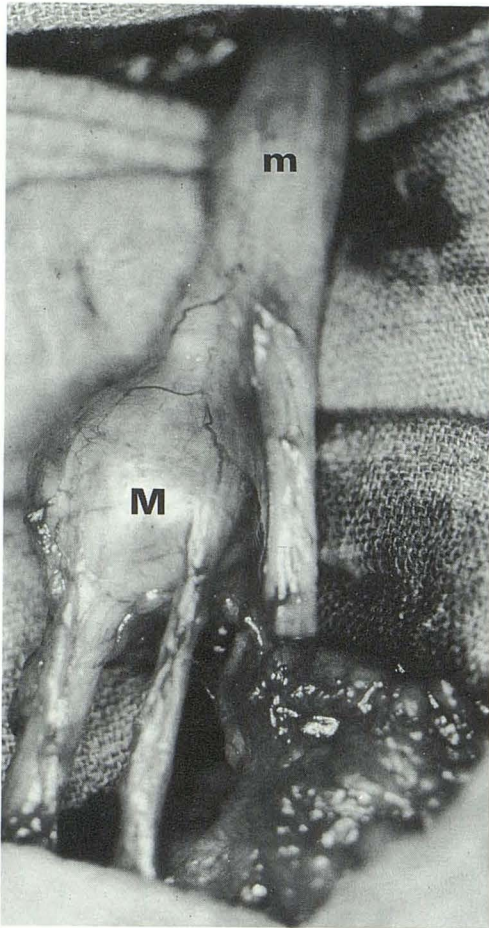


Fig. 3. Intraoperative photograph demonstrates both masses (*m*, *M*) on the external popliteal nerve.

the other tumor showed elongated cells extending along numerous thick collagen fibers, often collected in loose bundles, as seen in true neurofibromas (Fig. 4B).

Discussion

Schwannoma and neurofibroma are distinctly different benign tumors that arise from the peripheral nerve sheath. While schwannomas typically occur in patients between 20 and 50 years of age, most solitary neurofibromas occur in younger adults between 20 and 30 years of age. Most schwannomas occur on the large nerves of the flexor areas, as in our patient. The anatomical distribution of solitary neurofibromas is usually different, most frequently arising in cutaneous nerves of the dermis or subcutis without any area of predilection (1, 2). Simultaneous occurrence of

these two different tumors on the same nerve is rare.

US has proven to be a useful method in the initial evaluation of suspected peripheral nerve tumors (2) and pseudotumors (3). As in our case, schwannomas are usually well-defined, hypoechoic, and show distal sound enhancement in 50% of the cases (3). Neurofibromas are usually ill-defined and hypoechoic (3). In our case, the neurofibroma was seen as a fusiform enlargement of the nerve trunk from which it could not be differentiated. The presence of nerve tumors was diagnosed by sonography in this case, illustrating once again the usefulness of sonography in the detection of soft tissue masses.

MR was performed to better evaluate the extension of the tumors and their relationship to the nerve trunk. MR has been shown to be useful in the evaluation of soft-tissue masses (5), particularly peripheral nerve sheath tumors (6, 7). As in our case, most benign peripheral nerve sheath tumors show an intermediate signal intensity on T1-weighted images, while exhibiting a bright signal on T2-weighted images.

A recent study (7) proposed criteria to differentiate schwannomas from neurofibromas. The authors found that a peripheral location of the nerve of origin and the presence of a capsule were features that favored the diagnosis of schwannomas. These criteria were both present in our case.

The use of a paramagnetic contrast medium proved to be a valuable adjunct to the differential diagnosis in this case. Whereas the neurofibroma showed no enhancement after injection of the gadolinium-DTPA, the schwannoma demonstrated intense enhancement, leaving a peripheral layer of unenhanced tissue that corresponded to the normal nerve at surgery. Contrast-enhanced MR has been used in the evaluation of cranial nerve sheath tumors, particularly schwannomas (neurinomas) of the acousticofacial bundle (8). The schwannoma in our patient showed intense enhancement after intravenous gadolinium administration, identical to that seen in acoustic schwannomas.

Further studies would be needed before one could generalize from our isolated finding, that peripheral neurofibromas do not exhibit enhancement after intravenous gadolinium. This case, however, suggests that intravenous gadolinium could facilitate the differential diagnosis between peripheral schwannoma and neurofibroma.

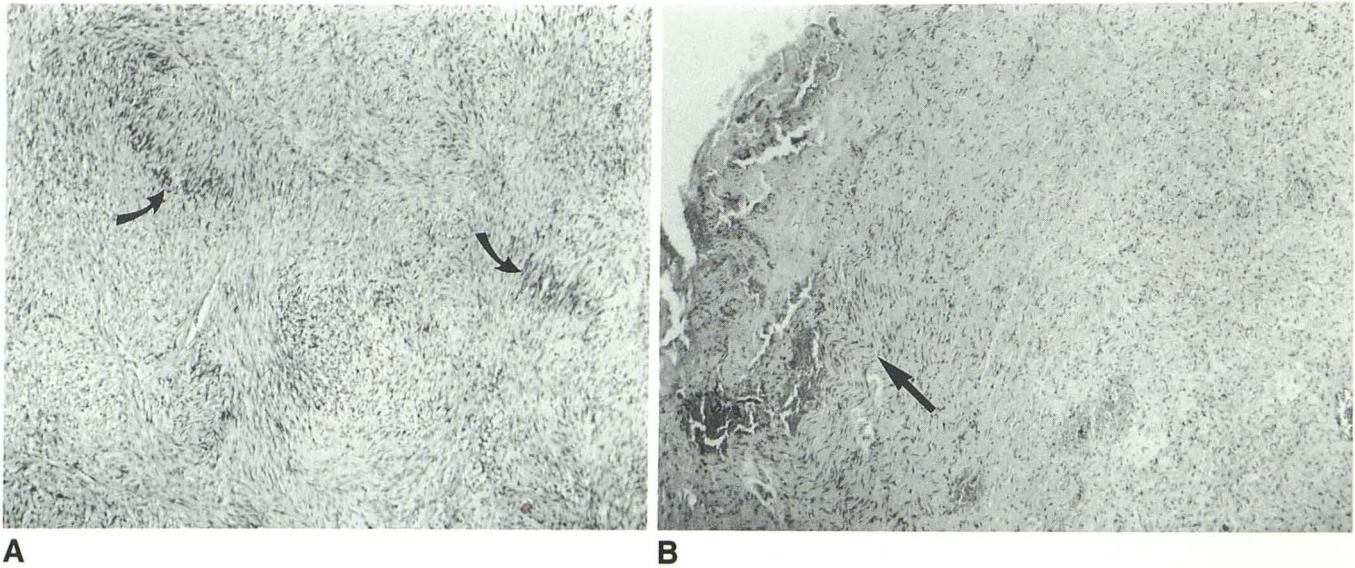


Fig. 4. A, Microscopic section of the large tumor reveals compact bundles of elongated cells forming tissue of the Antoni A type, with palisading of nuclei forming Verocay bodies (arrows) typical of schwannoma.

B, Microscopic section of the biopsy specimen from the smaller tumor shows elongated cells extending along numerous thick collagen fibers, often collected in loose bundles (arrows), as seen in true neurofibromas.

References

1. Russell DS, Rubinstein LJ. Tumours of the cranial, spinal and peripheral nerve sheaths. In: Russell DS, Rubinstein LJ, eds. *Pathology of tumours of the nervous system*. 5th ed. London: Edward Arnold, 1989:533-589
2. Enzinger FM, Weiss SW. Benign tumors of peripheral nerves. In: Enzinger FM, Weiss SW, eds. *Soft tissue tumors*. 2nd ed. St. Louis: Mosby, 1988:719-780
3. Fornage BD. Peripheral nerves of the extremities: imaging with US. *Radiology* 1988;167:179-182
4. Redd RA, Peters VJ, Emery SF, Branch HM, Rifkin MD. Morton neuroma: sonographic evaluation. *Radiology* 1989;171:415-417
5. Sundaram M, McGuire MH, Herbold DR. Magnetic resonance imaging of soft tissue masses: an evaluation of fifty-three histologically proven tumors. *Magn Reson Imaging* 1988;6:237-248
6. Stull MA, Moser RP Jr, Kransdorf MJ, Bogumill GP, Nelson MC. Magnetic resonance appearance of peripheral nerve sheath tumors. *Skeletal Radiol* 1991;20:9-14
7. Cerofolini E, Landi A, DeSantis G, Maiorana A, Canossi G, Romagnoli R. MR of benign peripheral nerve sheath tumors. *J Comput Assist Tomogr* 1991;15:593-597
8. Stack JP, Ramsden RT, Antoun NM, Lye RH, Isherwood I, Jenkins JPR. Magnetic resonance imaging of acoustic neuromas: the role of gadolinium-DTPA. *Br J Radiol* 1988;61:800-805