

Are your **MRI contrast agents** cost-effective?

Learn more about generic **Gadolinium-Based Contrast Agents**.



FRESENIUS  
KABI

caring for life

**AJNR**

**Systemic lupus erythematosus associated with marked intracranial calcification.**

K Yamamoto, H Nogaki, Y Takase and M Morimatsu

*AJNR Am J Neuroradiol* 1992, 13 (5) 1340-1342

<http://www.ajnr.org/content/13/5/1340>

This information is current as  
of April 18, 2024.

## Systemic Lupus Erythematosus Associated with Marked Intracranial Calcification

Kiyoshi Yamamoto,<sup>1</sup> Hiroshi Nogaki, Yoshitaka Takase, and Mitsunori Morimatsu

**Summary:** The authors describe a case of systemic lupus erythematosus associated with marked intracerebral calcification. The distribution of high signal on T1-weighted MR images was almost identical to the distribution of calcification on CT; however, the bodies of caudate nuclei with little calcification on CT also showed high intensities on T1-weighted images.

**Index terms:** Basal ganglia; Lupus erythematosus; Brain, calcification

Systemic lupus erythematosus (SLE) is frequently associated with neuropsychiatric disorders. Although x-ray computed tomography (CT) and magnetic resonance (MR) in SLE have often revealed brain atrophy, cerebral infarction, or

bleeding (1–5), extensive bilateral intracerebral symmetric calcification is rare (2, 6, 7).

We describe a case of SLE associated with marked intracerebral calcification shown by MR and CT.

### Case Report

A 32-year-old woman with a 14-year history of SLE was admitted to the hospital because of fever, visual disturbance, right hemiparesis, and dysarthria in September 1985. She had no family history of extrapyramidal disease or other neurologic disorders. On admission, neurologic examination revealed dysarthria, moderate right hemiparesis with positive right Babinski sign, and sensory disturb-

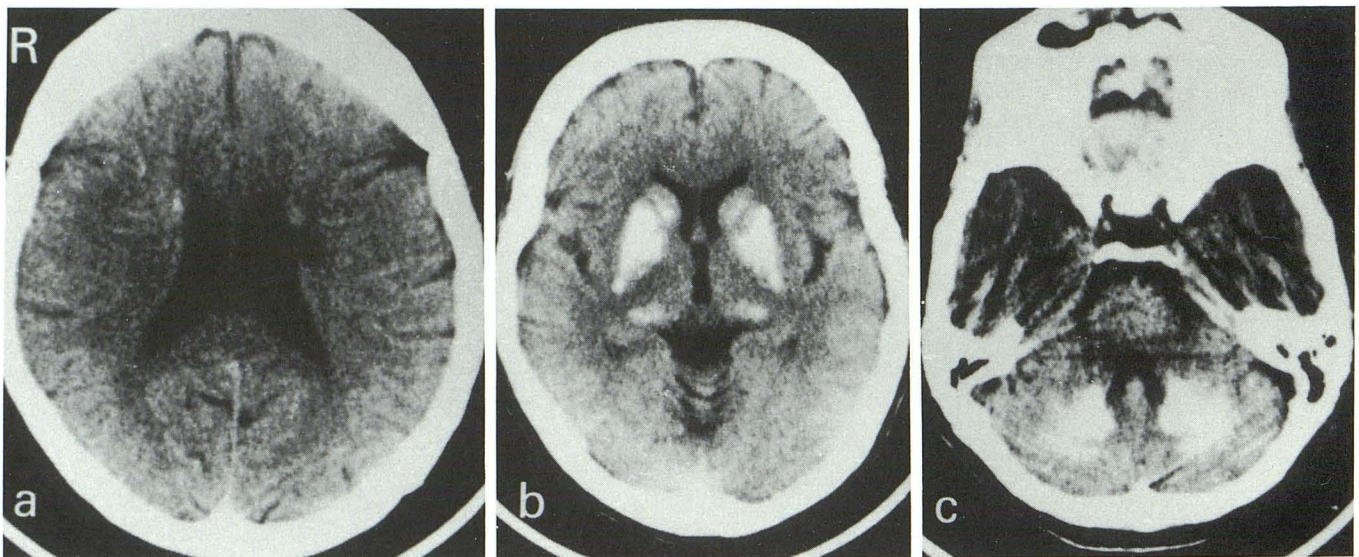


Fig. 1. CT in June 1989 demonstrated bilateral calcifications in the lentiform nuclei, caudate nuclei, thalamus, dentate nuclei, and the white matter of the cerebellar hemispheres. Low density areas were noted in the left corona radiata and internal capsule.

Received October 19, 1991; revision requested December 16; accepted on February 12, 1992.

All authors from the Department of Neurology, Yamaguchi University School of Medicine, Japan

<sup>1</sup> Address reprint requests to K. Yamamoto, Department of Neurology, Yamaguchi University School of Medicine, Kogushi 1144, Ube City, Yamaguchi 755, Japan.

AJNR 13:1340–1342, Sep/Oct 1992 0195-6108/92/1305-1340 © American Society of Neuroradiology

ance in the right half of her body. Abnormal laboratory studies included erythrocyte sedimentation rate of 30 mm/hour and an antinuclear antibody titer of 1:640. Blood calcium, inorganic phosphorus concentration, vitamin D level, and thyroid and parathyroid function studies were all normal. The cerebrospinal fluid was normal except for 60 mg protein/dl.

CT demonstrated bilateral calcifications in the lentiform nuclei, caudate nuclei, thalamus, dentate nuclei, and the white matter of the cerebellar hemispheres. Low-density areas were noted in the left corona radiata and internal capsule. Cerebral angiography revealed no abnormality. She recovered gradually with oral corticosteroid therapy.

CT in June 1989 showed no remarkable changes as compared with that in September 1985. A subsequent MR study obtained in April 1990 showed old cerebral infarctions in the left corona radiata, internal capsule, and the bilateral frontal deep white matter. On T1-weighted images, abnormal high signal intensity areas were seen bilaterally in the putamina, caudate nuclei, pulvinar, dentate nuclei, and cerebellar white matter. The distribution of high signal was almost identical to the distribution of calcification on CT obtained in June 1989 (Figures 1a, 1b, and 1c). However, the bodies of caudate nuclei with little calcification on CT showed apparently high intensities on T1-weighted images (Figs. 2a, 2b, and 2c). T2-weighted images showed

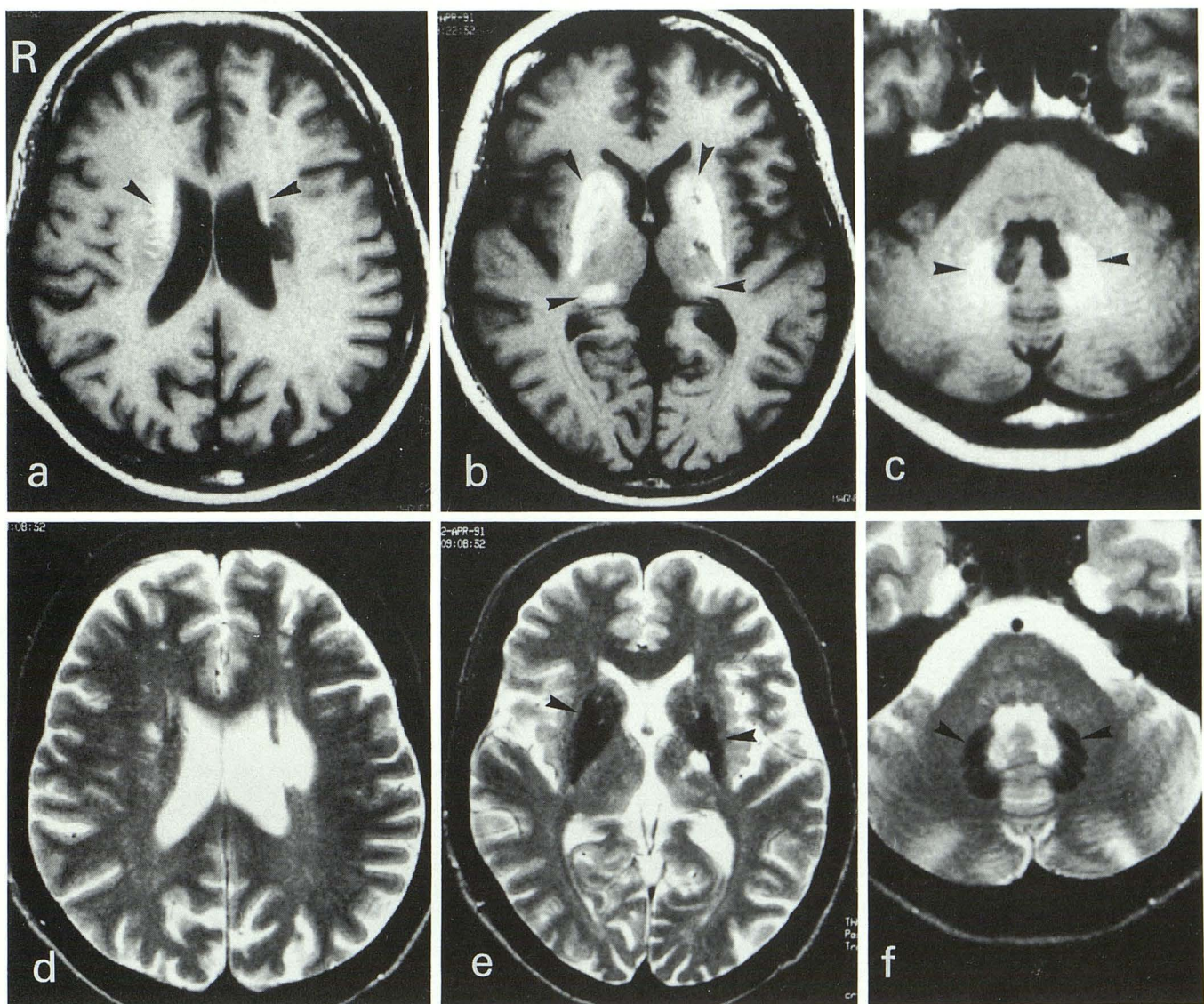


Fig. 2. MR in April 1990 showed old cerebral infarctions in the left corona radiata, internal capsule, and the bilateral frontal deep white matter. T1-weighted images (a, b, c) showed abnormal high signal intensity areas in the putamina, caudate nuclei, pulvinar, cerebellar white matter, and dentate nuclei bilaterally (arrowheads). The distribution of high signal was almost identical to the distribution of calcification on CT. However, the bodies of caudate nuclei with little calcification on CT showed apparently high intensities (a, arrowheads). T2-weighted images (d, e, f) showed abnormal decreased-intensity areas in the putamina, caudate nuclei, and dentate nuclei bilaterally (arrowheads).

abnormal decreased intensities in the putamina, caudate nuclei, and dentate nuclei bilaterally (Figs. 2d, 2e, and 2f).

## Discussion

Extensive intracerebral bilateral symmetric calcification is known to occur in idiopathic hypoparathyroidism and related endocrine disorders, anoxic encephalopathy, and Fahr disease (8–10). This patient did not have abnormal electrolytes, endocrine functions, or a family history of any of these diseases. On the basis of these observations, it is assumed that the marked intracranial calcifications in this patient resulted from SLE.

The common CT and MR findings in SLE are sulcal enlargement with or without ventricular enlargement, infarction, and intracranial hemorrhage (1–5). Extensive intracerebral bilateral symmetric calcification in SLE is rare (2, 6, 7). Nagaoka et al reported five cases of SLE with intracranial calcification (6). Since three of their five patients had neuropsychiatric manifestations and four of the five cases had evidence of high disease activity, such as hypocomplementemia and high levels of serum anti-DNA antibody, they suggested that severe angitis and/or autoimmune mechanism may be the cause of intracranial calcifications in SLE. Anderson reported a case of SLE with multiple infarcts and bilateral calcification in the basal ganglia (7). He suggested that immunologic vascular injury caused multiple infarcts that resulted in vascular calcification.

The effect of calcium on signal intensity in MR was generally found to be either a null effect or a reduction in signal intensity. Recently, there have been some people who have made the observation that often there is increased signal on the T1-weighted images in regions of calcifications in such disorders as pseudohypoparathyroidism, hypoparathyroidism, brain tumor, and others (9, 10). Although the mechanism is poorly understood, this finding of increased T1 signal and decreased T2 signal is now well recognized as one of the presentations of intraparenchymal calcification. In this patient, T1-weighted images showed high signal intensities in the putamina,

caudate nuclei, pulvinar, and dentate nuclei. The distribution of high signal was almost identical to the distribution of calcification on CT. However, the bodies of caudate nuclei with little calcification on CT showed apparently high intensities on T1-weighted images. This suggests that the calcification might be laid down in small microscopic particles that are below the level of resolution of CT and thus not visible as calcification on CT. Araki et al reported that, in a case of pseudohypoparathyroidism, the dentate nuclei without calcifications showed increased signal intensities on T1 images, whereas bilateral deep white matter calcifications presented no remarkable changes of signal intensities on T1-weighted images (10). They suggest the presence of another factor in addition to calcium deposit causing changes of signal intensities.

The mechanism of intracranial calcification in SLE remains unknown. However, it should be born in mind that marked intracranial calcification can be found in SLE.

## References

1. Bilaniuk LT, Patel S, Zimmerman RA. Computed tomography of systemic lupus erythematosus. *Radiology* 1977;124:119–121
2. Gonzalez-Scarano F, Lisak RP, Bilaniuk LT, Zimmerman RA, Atkins PC, Zweiman B. Cranial computed tomography in the diagnosis of systemic lupus erythematosus. *Ann Neurol* 1979;5:158–165
3. Aisen AM, Gabrielsen TO, McCune WJ. MR imaging of systemic lupus erythematosus involving the brain. *AJNR* 1985;6:197–201
4. McCune WJ, MacGuire A, Aisen A, Gebarski S. Identification of brain lesions in neuropsychiatric systemic lupus erythematosus by magnetic resonance scanning. *Arthritis Rheum* 1988;31:159–166
5. Kitagawa Y, Gotoh F, Koto A, Okayasu H. Stroke in systemic lupus erythematosus. *Stroke* 1990;21:1533–1539
6. Nagaoka S, Matsunaga K, Chiba J, Ishigatsubo Y, Tani K. Five cases of systemic lupus erythematosus with intracranial calcification. *Clin Neurol* 1982;22:635–643
7. Anderson JR. Intracerebral calcification in a case of systemic lupus erythematosus with neurological manifestations. *Neuropathol Appl Neurobiol* 1981;7:161–166
8. Scotti G, Scialfa G, Tampieri D, Landoni L. MR imaging in Fahr disease. *J Comput Assist Tomogr* 1985;9:790–792
9. Henkelman RM, Watts JF, Kucharczyk W. High signal intensity in MR images of calcified brain tissue. *Radiology* 1991;179:199–206
10. Araki Y, Furukawa T, Tsuda K, Yamamoto T, Tsukaguchi I. High field MR imaging of the brain in pseudohypoparathyroidism. *Neuroradiology* 1990;32:325–327