

Are your **MRI contrast agents** cost-effective?

Learn more about generic **Gadolinium-Based Contrast Agents**.



FRESENIUS
KABI

caring for life

AJNR

Delayed neurologic deterioration in the patient with spinal trauma: role of MR imaging.

M Silberstein, B M Tress and O Hennessy

AJNR Am J Neuroradiol 1992, 13 (5) 1373-1381

<http://www.ajnr.org/content/13/5/1373>

This information is current as
of April 17, 2024.

Delayed Neurologic Deterioration in the Patient with Spinal Trauma: Role of MR Imaging

Morry Silberstein,¹ Brian M. Tress,² and Oliver Hennessy¹

PURPOSE: To 1) correlate spinal MR features and modes of clinical presentation associated with symptomatic neurologic deterioration following longstanding spinal trauma; 2) correlate degree of neurologic deficit with spinal MR appearance in these patients; and 3) determine the relationship between new symptoms and ongoing cord compression. **METHODS:** Retrospective examination of MR images, and correlation with clinical data, in 94 consecutive patients. **RESULTS:** Sixty-seven patients presented with either an increase in degree of myelopathy or ascending neurologic level. Spinal cord atrophy (43%), syrinx (41%), and cord compression (24%) were found most frequently. Whereas in patients with complete motor and sensory deficit cord atrophy was the most frequent finding (52%), 75% of patients with useful motor function had normal spinal cords. There was a significant association ($P < .05$) between cord compression and the MR findings of cord atrophy and myelomalacia, whereas a normal cord was over twice as frequent in patients without spinal cord compression. MR imaging led to an active change in management in 15% of patients, with improvement following surgery in all operated cases. **CONCLUSION:** Although syrinx is a frequent, and treatable cause of delayed neurologic deterioration, MR will frequently show other abnormalities such as ongoing cord compression. MR imaging should be performed urgently in all patients with new symptoms to enable early treatment to prevent irreversible loss of function.

Index terms: Spinal cord, trauma; Spinal cord, compression; Spinal cord, magnetic resonance

AJNR 13:1373-1381, Sep/Oct 1992

Many patients in whom a significant neurologic deficit develops (either quadriplegia or paraplegia) following spinal cord injury remain neurologically stable for many years, but a number will deteriorate at a variable time from injury, a syndrome known as posttraumatic progressive myelopathy (PTPM) (1). Posttraumatic syringomyelia, or intramedullary cyst formation, is the most important cause for this syndrome, as it is potentially treatable, resulting in either cessation or reversal in deterioration following treatment (2). This diagnosis has, in the past, been made with myelography, or computed tomography following myelography (CTM) (2-4), but more recently, magnetic resonance (MR) imaging has become the technique of choice for this diagnosis (5). MR can also identify other spinal cord abnormalities in patients with long-standing spinal trauma, such as cord atrophy and myelomalacia (6). However, all previous studies of MR in patients following long-standing spinal trauma have included relatively small numbers of patients with symptomatic deterioration. The largest study to date, consisting of 76 patients with long-standing spinal trauma, included only 14 patients with new symptoms (6).

The aims of this study were to: 1) identify the specific spinal cord features associated with symptomatic neurologic deterioration following spinal cord injury of long-standing; 2) correlate the degree of neurologic deficit with spinal cord appearance, in this group of patients; and 3) identify the clinical features most frequently associated with posttraumatic syringomyelia.

Received September 24, 1991; accepted and revision requested November 19; revision accepted January 24, 1992.

This work was supported in part with the financial assistance of the Edith and Viola Reid Trust of the University of Melbourne.

¹ Department of Radiology, Austin Hospital, Heidelberg, Victoria, Australia 3084. Address reprint requests to Dr. Morry Silberstein.

² Department of Radiology, Royal Melbourne Hospital, Parkville, Victoria, Australia 3020.

AJNR 13:1373-1381, Sep/Oct 1992 0195-6108/92/1305-1373

© American Society of Neuroradiology

Materials and Methods

Ninety-four patients (74 men and 20 women) aged between 18 and 78 years (mean of 40 years) who developed new symptoms following a previous spinal cord injury were examined with MR between December 1987 and December 1990. The original mode of injury was motor vehicle accident in 58 patients, fall in 12, diving injury in 12, and miscellaneous, including assault and recreational sports, in 12. Fifty-seven patients had injuries to the cervical spine at original presentation, and 37 to the thoracic spine. The neurologic pattern of injury at presentation was transverse in 75 patients, central cord in 11, and Brown-Sequard in 8. The most frequent neurologic levels at presentation were C6 and C7 (17 patients each) in the cervical region, and T12 (13 patients) in the thoracic region.

For inclusion in the study, patients had a single neurologic level at original presentation with clinical deficit above the level of the conus medullaris, admission to the Hospital's Spinal Injuries Unit at first presentation, and subsequent presentation with new clinical symptoms following neurologic stabilization. Clinical status was assessed according to the system of Frankel et al (7) at original presentation and at time of new symptoms: grade A, no neurologic function below the level of injury; grade B, preserved sensation only; grade C, nonfunctional motor power present; grade D, functional motor power but less than normal; and grade E, no neurologic symptoms. The pattern of clinical presentation was classified as one of: increasing myelopathy, defined as an alteration in Frankel grade; ascending level, where the level of cord injury rose; presentation with pain; hyperhidrosis, where there was recent alteration in sweating; and an increase in muscular spasm. Patients presented between 4 months and 408 months from original injury (mean of 114 months).

MR imaging was performed with a 0.3-T resistive magnet (Fonar, B3000) on all patients within 3 weeks of clinical presentation. Images were obtained with a spin-echo (SE) technique consisting of 2 sagittal sequences (repetition time msec/echo time msec = 500/16 for T1-weighted images, and 2500/80 for T2-weighted images) and 2 axial sequences (500/16 and 2500/80). Slice thickness was 5 mm with 2-mm interslice gap.

The images were analyzed for: the presence of spinal cord compression, defined as indentation or displacement of the spinal cord, or complete obliteration of the cerebrospinal fluid (CSF) space around the cord; cord atrophy, an anteroposterior diameter of less than 6 mm in the cervical cord, and 5 mm in the thoracic cord on a midline sagittal slice (6); myelomalacia, cord hyperintensity on T2-weighted images with either normal or low signal intensity on T1-weighted images, and ill-defined margins of the area of abnormal signal; cystic myelomalacia, an area of CSF intensity within the cord on T1-weighted images of less than 5 mm diameter with well-defined margins, and surrounding hyperintensity on T2-weighted images; and syrinx, a well-defined area of CSF intensity within the cord on T1-weighted images, including lesions with surrounding hyperintensity, if the cystic region was greater than 5 mm

diameter. The 5-mm cutoff was used because surgery would not be performed for cysts of less than this size, and, in previously published work, this size criterion was used to distinguish between small and large cysts (1).

A number of patients had multiple MR abnormalities, and these were recorded relative to location and severity. Thus, the presence or absence of cord compression and cord atrophy were recorded in all patients, regardless of other findings. Individual cord cystic lesions were categorized as syrinx if greater than 5 mm, regardless of the presence of myelomalacia, but if a separate area of myelomalacia was present at a different level, both diagnoses were recorded.

Fourteen patients underwent surgery following MR imaging, including 12 who underwent syrinx shunting, and two who had spinal cord decompression.

Results

Cord atrophy (43% of patients) and syrinx (41%) were the most frequent imaging findings in the 94 patients. Cord compression was found in 24%, cystic myelomalacia in 15%, myelomalacia in 11%, and in 18% the spinal cord was normal.

Clinical Presentation and MR Findings

The presenting symptoms are related to the MR imaging findings in Table 1. Increasing myelopathy was the most frequent presenting symptom (36%), followed by ascending level (31%) and pain (16%). Hyperhidrosis (9%) and increasing spasms (6%) were infrequent modes of presentation. One patient presented with recent onset of ataxia, and one with intermittent trunk parasthesiae.

In patients with increasing myelopathy, the most frequent finding was posttraumatic syrinx (47%), with cord atrophy (41%) slightly less frequent. In patients with ascending level, syrinx (52%) was also the most frequent finding, followed by cord atrophy (38%).

TABLE 1: MR findings in each type of clinical presentation

	Increased Myelopathy	Ascending Level	Pain	Hyperhidrosis	Increase Spasm	Other
Normal cord	3	8	4	1	0	1
Cord compress	10	4	2	0	5	2
Cord atrophy	14	11	7	3	4	1
Myelomalacia	2	1	5	0	2	0
Cystic malacia	8	2	1	2	2	0
Syrinx	16	15	3	4	1	0
Total	34	29	15	8	6	2

Note.—"Other" included one patient with ataxia, and one with intermittent trunk parasthesiae.

The most frequent symptoms in patients found to have a posttraumatic syrinx were increasing myelopathy and ascending level. Seventy-nine percent of patients with a syrinx presented with one or other of these symptoms (Figs. 1 and 2). Pain, hyperhidrosis, and increasing spasms were found infrequently in patients with a syrinx.

In contrast to patients with myelomalacia (Fig. 3), where 50% of patients presented with pain, 57% of patients with cystic myelomalacia (Fig. 4), presented with increasing myelopathy.

The most frequent presentation in patients with cord compression was increasing myelopathy (43%). However, only 29% of the patients with this presentation were found to have cord compression. In contrast, although presentation with increasing spasms was infrequent in patients with cord compression (22%), 88% of patients

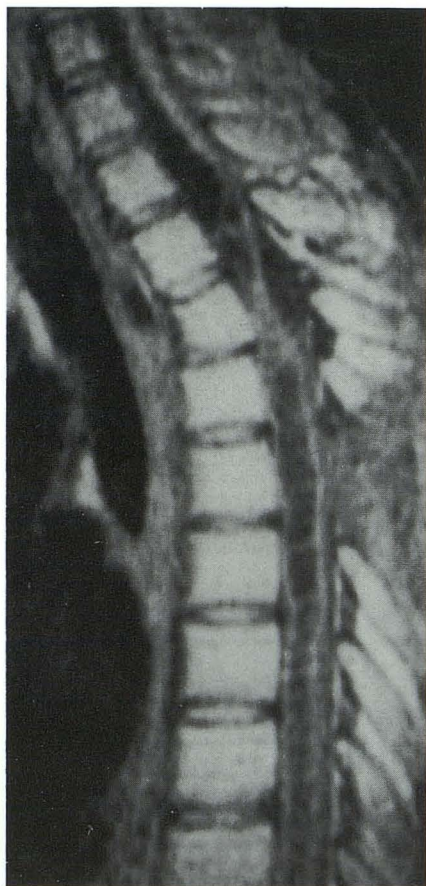

Fig. 1. Thoracic syrinx. Sagittal MR image (SE 600/15) on a 28-year-old man whose Frankel grade increased from C to A 10 months following a motor vehicle accident. A large syrinx extends caudally from the original site of injury at T3-T4, and a smaller, septated syrinx extends cranially. The spinal cord is adherent to the theca posteriorly. The findings were confirmed at surgery, and the patient improved to grade B following drainage of both syrinxes.

who presented with increasing spasms had cord compression.

Degree of Neurologic Deficit and MR Findings

The initial Frankel grades, when neurologic recovery following injury had reached a plateau (stabilization), and the Frankel grades at the time of presentation with new symptoms, are presented relative to the MR spinal cord diagnoses in Tables 2 and 3. Deterioration in neurologic function was present in 38% of patients, including two patients who had presented for the investigation of ascending level, and at examination were found to have increased deficit. The most frequent findings in this group were syrinx (50%) and spinal cord compression (28%). Sixty percent of patients were grade A at symptomatic presentation, with the most frequent MR finding of cord atrophy (Fig. 3).

Nineteen patients were grade B at symptomatic presentation, with syrinx (50%) found most frequently.

Thirteen percent of patients were grade C at symptomatic presentation, with normal cord (33%) found most frequently.

Only 9% had useful motor function (grade D or E) at symptomatic presentation, with 75% of these having normal cords.

Whereas 43% of patients later found to have a syrinx were grade A at time of clinical stabilization, 69% of patients with a syrinx were grade A at symptomatic presentation. Similarly, 48% of patients with cord compression were grade A at time of clinical stabilization, compared to 61% at the time of symptomatic presentation.

Effect of Cord Compression

The MR spinal cord findings are presented relative to the presence of cord compression in Table 4. There was a strong correlation between the presence of cord compression and the MR findings of cord atrophy, myelomalacia, and cystic myelomalacia (Fig. 5). This was confirmed using a χ^2 statistic, which yielded an association between each of these MR diagnoses and cord compression at $P < .005$. Both posttraumatic syrinx and a normal cord were more than twice as frequent in patients without cord compression, than in patients with cord compression.

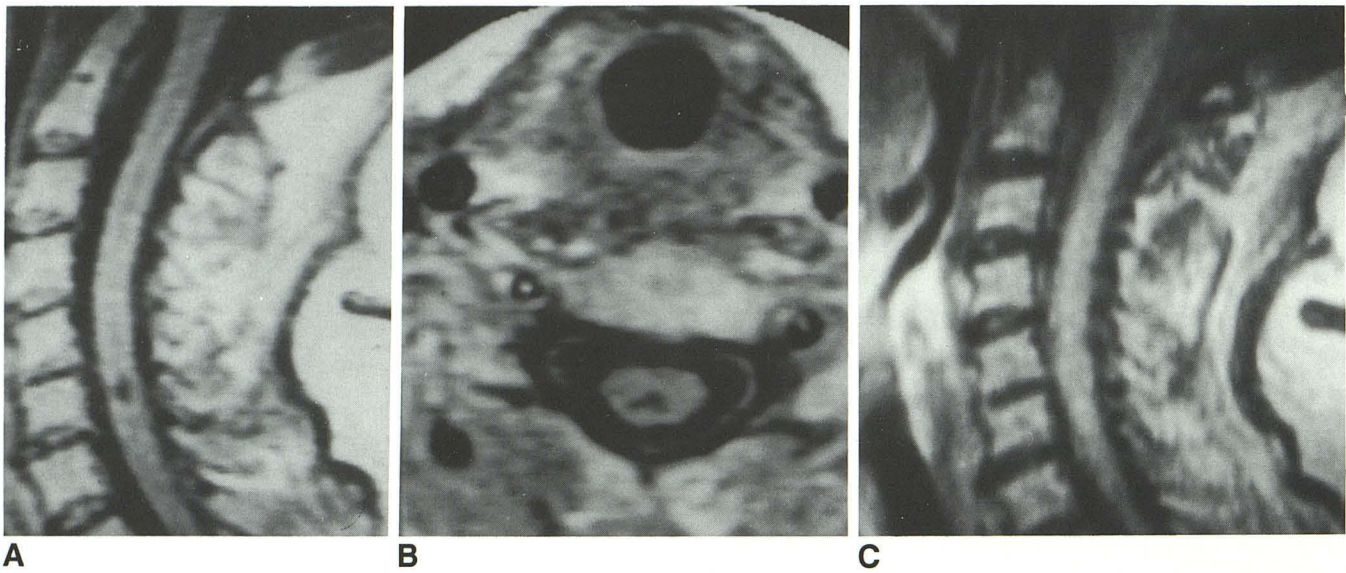


Fig. 2. Small cervical syrinx.

A, Sagittal MR (SE 600/15) on a 51-year-old woman with Frankel grade A whose level of dysfunction ascended from T1 to C6 4 months following initial injury in a fall resulting in a C6–C7 subluxation. A small syrinx is identified at C6.

B, Axial SE 600/15 image confirms intramedullary cystic lesion.

C, Sagittal SE 2500/80 image. The syrinx is slightly hyperintense to CSF.

Time from Injury and MR Findings

The mean and sample standard deviations for each MR category were: normal cord, 116.2 ± 23.7 months; cord atrophy, 118.0 ± 34.8 months; cystic myelomalacia, 87.1 ± 11.7 months; and syrinx, 104.9 ± 16.3 months.

Results of Treatment

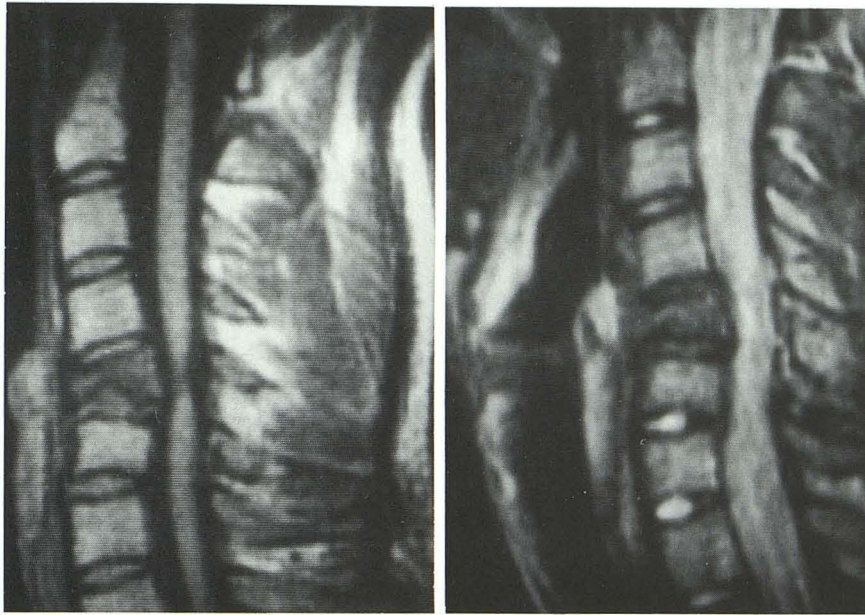
Of the 39 patients who were classified as having a syrinx, 12 (31%) underwent surgery, including four syringocisternal, four syringopleural, and four syringoperitoneal shunts. In all 12 cases, the MR findings of syrinx were confirmed. Seven of these patients presented with ascending level, with descent to the original level following surgery in all seven. The other five patients presented with increasing myelopathy, with clinical improvement in all five following surgery. In four of these, the postoperative Frankel grades improved to the grades at neurologic stabilization, but in one patient, improvement was incomplete following shunting.

Only two patients with spinal cord compression underwent surgery following MR imaging, with both patients having postoperative improvement.

Discussion

PTPM has, in the past, been thought to be an uncommon problem in patients with previous

spinal trauma, with a reported incidence of between 0.5% and 2% (4, 8, 9). However, the majority of descriptions have concentrated on the specific entity of posttraumatic syrinx, and equated this with the presenting syndrome of PTPM (4, 10). In the largest reported series, 40 patients in a group of 6,800 admissions were described, and, although only 26 had confirmed diagnoses of syrinx, by either CTM or operation, all were ascribed to posttraumatic syrinx on the basis of clinical features (4). With the advent of MR imaging, the diagnosis of other conditions associated with deterioration in patients with long-standing spinal trauma has been greatly improved (6). In the past, distinction between myelomalacia and treatable syrinx was frequently difficult on the basis of CTM where contrast could accumulate within the spinal cord in either condition (2). Definitive diagnosis of myelomalacia is now possible based on MR criteria, but previous reports have only evaluated small numbers of patients presenting for investigation of PTPM (1, 3, 11). In one series of nine patients, eight had large cysts ($> .5$ cm), and one had small cysts with myelomalacia (1), and in another of 13 patients, the MR diagnosis was cyst in seven patients, myelomalacia in five, and normal in one (11). Hence, the overall incidence of syrinx in patients presenting with PTPM has been uncertain in the past. In our study, 41% of patients

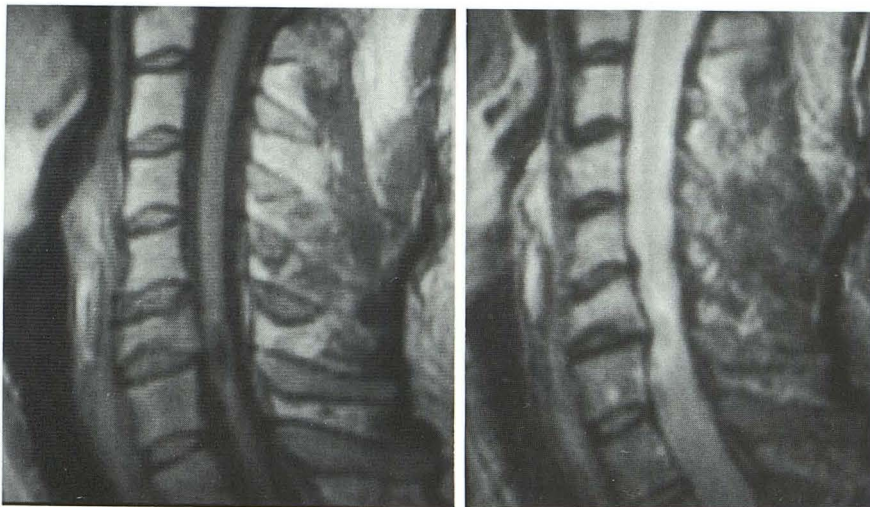

A

B

Fig. 3. Myelomalacia and cord atrophy.
 A, Sagittal MR (SE 600/15) on a 21-year-old Frankel grade A man who developed severe upper limb pain 16 months following original injury in a motor vehicle accident. The cord is atrophic opposite the C5 burst fracture.

B, Sagittal (SE 2500/80) image. The atrophic segment is now hyperintense to the cord elsewhere.



A

B

Fig. 4. Cystic myelomalacia.

A, Sagittal MR (SE 600/15) on a 37-year-old man examined 17 years following a diving injury, whose Frankel grade had increased from B to A. A small area of CSF signal intensity, surrounded by a rim of slightly greater intensity, is present at C6-C7.

B, Sagittal SE 2500/80 image. The central area is hypointense to the cord elsewhere, whereas the peripheral rim is hyperintense.

TABLE 2: Patient numbers with initial and subsequent Frankel grade, by MR category

	Frankel Grade									
	A		B		C		D		E	
	INI	MR	INI	MR	INI	MR	INI	MR	INI	MR
Normal cord	6	6	1	1	1	4	7	4	2	2
Cord compress	11	14	3	7	5	2	4	0	0	0
Cord atrophy	23	29	6	7	4	3	7	1	0	0
Myelomalacia	7	8	1	1	1	0	1	1	0	0
Cystic malacia	5	7	3	4	1	3	5	0	0	0
Syrinx	17	27	8	9	7	3	7	0	0	0
Total	43	56	13	18	12	12	24	6	2	2

Note.—INI = Number of patients with this Frankel grade when neurologic status has stabilized. MR = Number of patients with this Frankel grade at time of presentation for MR imaging. Note that some patients had more than one MR diagnosis.

TABLE 3: Initial and subsequent Frankel grades and MR findings

INI	MR	Normal Cord	Cord Compress	Cord Atrophy	Myelomalacia	Cystic Malacia	Syrinx	Total No.
A	A	6	11	23	7	5	17	43
B	A	0	2	4	1	2	5	8
	B	1	1	2	0	1	3	5
C	A	0	1	2	0	0	5	5
	B	0	3	2	1	1	1	5
	C	1	1	0	0	0	1	2
D	A	0	0	0	0	0	0	0
	B	0	3	3	0	2	5	5
	C	3	1	3	0	3	2	10
	D	4	0	1	1	0	0	6
E	E	2	0	0	0	0	0	2
Total		17	23	40	10	14	39	94

Note.—See footnote for Table 2.

TABLE 4: Percentage of patients with cord compression in each MR category

	Normal Cord (%)	Cord Atrophy (%)	Myelo-malacia (%)	Cystic Malacia (%)	Syrinx (%)	Total No.
Cord compress	9	61	22	35	22	23
No cord compress	21	37	7	8	48	71

had a syrinx based on MR criteria of isointensity with CSF on T1-weighted images and sharply defined margins. Only 12 of these cases had surgery, although the presumptive preoperative diagnosis of syrinx was confirmed in all 12. In some patients, syrinx intensity on T2-weighted images will be lower than CSF because of flow phenomena, while in others, the presence of proteinaceous fluid in the syrinx may result in higher intensity on T1-weighted images (2, 5). The latter group may be missed on MR and only proven with intraoperative spinal sonography (IOSS) (5, 12), which was not performed in our patients, so that our overall results may have underestimated the proportion of patients with a syrinx. The ability of MR to demonstrate cord atrophy (present in 43% of our patients) also supports the use of MR in the investigation of PTPM since the clinical presentations (63%) had either increasing myelopathy or ascending level) were very similar to patients found to have a syrinx.

The role of cord compression in patients with PTPM also requires consideration. A significant proportion of patients (24%) had cord compression on MR, and there was a statistically significant association with cord atrophy, myelomalacia, and cystic myelomalacia. Similarly, a normal

cord was twice as frequent in patients without cord compression.

We have previously shown that acute cord compression has a significant association with a worse long-term prognosis (unpublished data), suggesting that patients with early surgical decompression may have a better outcome. The association of cord compression with PTPM in the chronic stages of spinal trauma raises the issue of whether late surgical decompression can improve patient outcome, a topic of some controversy (5).

Previous authors have suggested that pain is the most important clinical predictor of the presence of a posttraumatic syrinx (2, 8). However, only 8% of patients with a syrinx presented with pain in our series, and in patients presenting with pain, only 20% were found to have a syrinx. Increasing muscular spasm has not been considered to be a significant feature of PTPM in the past, and, although infrequent in our series (6%), 88% of patients with this presentation had cord compression.

How do the patterns of MR cord abnormality relate to the degree of neurologic deficit? In the largest study to date, of 76 patients, only 14 presented with new symptoms (6). Cord abnormalities were grouped into several patterns including atrophy, longitudinal syrinx, N/Hi and Lo/Hi. The N/Hi pattern corresponds to our myelomalacia category, while the Lo/Hi pattern (marked hypointensity on T1-weighted images and hyperintensity on T2-weighted images) fulfills our inclusion criteria for syrinx. Our category of cystic myelomalacia was not specifically described in that study (6).

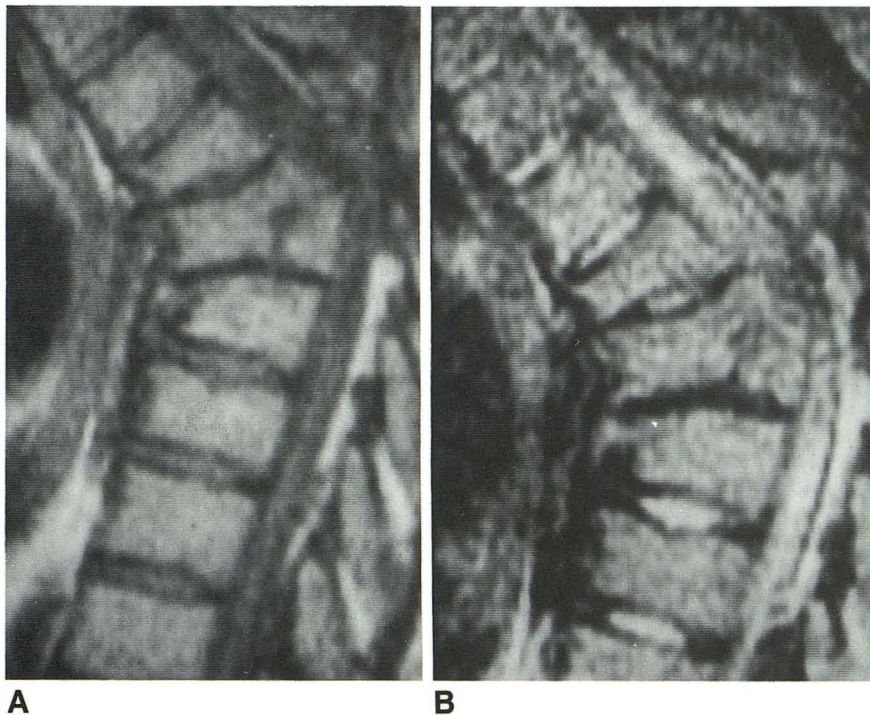


Fig. 5. Cord compression.

A, Sagittal MR (SE 500/16) on a 26-year-old man who presented with increasing muscular spasms 4 years following a motor vehicle accident in which he became a grade A paraplegic. marked spinal canal compression by the T7 burst fracture is present. The spinal cord is not clearly identified within the canal.

B, Sagittal 2500/80 image. Marked compression of the subarachnoid space is confirmed.

The MR diagnosis of syrinx in our series was associated with a delayed significant increase in neurologic deficit. In this group, 46% of patients had increased their degree of deficit by the time of symptomatic presentation, with 69% grade A and 23% grade B. In contrast, none of the eight patients with syrinx in the study of Yamashita et al (6) had developed an increase in degree of neurologic deficit. Similarly, none of the patients in that study with pattern Lo/Hi had increased their degree of deficit at time of MR, and only four out of the 17 patients with this pattern were grade A or B at time of MR. Of patients with cord atrophy in our series, 35% had increased their Frankel grade by the time of symptomatic presentation, with 73% grade A and 18% grade B. This contrasts with the findings of Yamashita et al (6), where none of the patients had increased their Frankel grade at time of MR, and only two of the five patients with cord atrophy were grade A or B.

Similarly, nine out of the 10 patients with myelomalacia in our series were grade A or B at time of MR, compared to only one of 18 in the series of Yamashita et al. A normal cord was associated with grade D or E in only 35% of our patients, yet 86% of patients with a normal cord in the series of Yamashita et al were grade D or E (6).

These findings suggest that we have studied a different population to Yamashita et al (6), and

this is confirmed when the proportions in any given MR category are compared. Forty percent of the patients in the series of Yamashita et al had normal cords compared to 18% of our patients. Of the 62 patients who did not present with new symptoms in the series of Yamashita et al, only 3% had a longitudinal syrinx, and 23% pattern Lo/Hi, compared to 41% with syrinx in our series of acutely symptomatic patients.

Adding the 15% of our patients with cystic myelomalacia results in cystic cord lesions being demonstrated almost twice as frequently in our acutely symptomatic patients than in the patients in Yamashita et al's series who did not present with new symptoms. While they found cord atrophy in only 6% of patients, 43% of our patients were found to have cord atrophy.

The next, and most important, question, is, why do patients become symptomatic with longstanding spinal trauma?

The majority of patients with longitudinal syrinx are likely to develop new symptoms. Six of eight patients in Yamashita et al's series were in this category, and there have been several other published studies giving details of PTPM and posttraumatic syrinx formation (1-4). The mechanism, as in patients who have idiopathic syringomyelia, is related to pressure on the long tracts resulting in motor and sensory symptoms, and with longitudinal extension, ascending level of impairment (4).

This fails to explain the reason for symptomatic presentation in patients with smaller cysts, included in Yamashita et al's pattern Lo/Hi, and in our syrinx category. The exact pathogenesis of cyst formation following spinal cord injury is not known with certainty, but probably involves a number of mechanisms (3, 13). These include liquefactive necrosis due to the release of enzymes in the cord substance (14), infarction within the cord due to direct vascular trauma at the time of injury (15, 16), and the sequel of central hemorrhagic necrosis (13). The cavity then enlarges by secretion of fluid from lining cells or entry of fluid through Virchow-Robin spaces, and pressure changes transmitted from the subarachnoid space (3, 17, 18). Since symptomatic presentation is likely to reflect pressure effects, the larger the cyst becomes, the greater the likelihood of symptoms. Yamashita et al wondered whether pattern Lo/Hi, which had a relatively poor prognosis, was a precursor of "frank posttraumatic syrinx" (6). Patients with that pattern (82% of whom had developed new symptoms) had MR at a mean of 10.3 months from injury (6). In contrast, our patients with syrinx were seen at a mean of 104.9 months, and cystic myelomalacia at 87.1 months, from injury. In addition, the presenting symptoms in both of these conditions were similar in our series. It may well be that these entities represent a continuous spectrum of progressive cavitation, and, just as in patients with external cord compression, symptomatic presentation is related to the duration of compression (4, 13).

Why patients with other MR patterns become symptomatic is uncertain. Cord compression may play a part, as it was present in 50% of our patients with myelomalacia and 35% of patients with cord atrophy. Of the six patients presenting with increasing muscular spasms, the five with cord compression all had anterior compression by vertebral body, osteophyte, or disk. Chronic delayed myelopathy has a recognized association with recurrent cord compression, although it has been thought previously to be rare (13).

There still remains a subset of patients with PTPM in our series where the presence of symptoms requires explanation. In one series of 64 patients examined with myelography, 30% were not thought to have a posttraumatic syrinx and were not operated upon, but 8% (five patients) were thought to have a syrinx, but at operation, no cyst was found (2). Four of these had an atrophic cord at operation, including two with

necrotic material in the cord at biopsy. An additional patient was described as having "gelatinous material" in the cord (2). The clinical features were no different in patients with, or without, spinal cord cysts. The authors of that study postulated prolonged or delayed necrosis as the mechanism for this phenomenon (2).

One other possibility, that of the false negative MR, requires consideration. In one series of 12 patients with acute cervical spinal trauma who had MR and IOSS, two patients were found to have cysts with IOSS where MR suggested spinal cord contusion (19). In another series of 10 patients who had CTM for the investigation of PTPM, IOSS found no sonographic evidence of a syrinx in two patients with positive CTM studies (12). Although no large studies of patients with PTPM employing IOSS and MR have been performed, there is a possibility of missing patients with proteinaceous cysts by using MR, due to isointensity with adjacent myelomalacia or normal cord.

Finally, it is worthwhile noting the relatively recent anecdotal report of a patient who developed PTPM 3 months following cervical cord injury and was found to have myelomalacia at both MR and operation, with dramatic improvement following myelotomy (20).

In summary, the most frequent MR findings in patients with posttraumatic progressive myelopathy were cord atrophy and syrinx, with the most frequent clinical presentations of syrinx being increasing myelopathy or ascending level. Cord atrophy and myelomalacia were frequently associated with cord compression, whereas patients with a normal cord at symptomatic presentation frequently had no cord compression and useful motor function. MR imaging led to an active change in management in 15% of patients, with confirmation of MR findings at surgery and postoperative improvement in all operated cases. MR imaging should be performed urgently in all patients with new symptoms to enable early treatment to prevent irreversible loss of function.

References

1. Gebarski SS, Maynard FW, Gabrielsen TO, Knake JE, Latack JT. Posttraumatic progressive myelopathy. *Radiology* 1985;157:379-385
2. Stevens, Olney JS, Kendall BE. Post-traumatic cystic and non-cystic myelopathy. *Neuroradiology* 1985;27:48-56
3. Quencer RM, Green BA, Eismont FK. Posttraumatic spinal cord cysts: clinical features and characterization with metrizamide computed tomography. *Radiology* 1983;146:415-423

4. Vernon JD, Silver JR, Ohry A. Post-traumatic syringomyelia. *Paraplegia* 1982;20:339-364
5. Quencer RM. The injured spinal cord: evaluation with magnetic resonance and intraoperative sonography. *Radiol Clin North Am* 1988;26:1025-1045
6. Yamashita Y, Takahashi M, Matsuno Y, et al. Chronic injuries of the spinal cord: assessment with MR imaging. *Radiology* 1990;175:849-854
7. Frankel HL, Hancock DO, Hyslop G, et al. The value of postural reduction in the initial management of closed injuries of the spine with paraplegia and tetraplegia. *Paraplegia* 1969;7:179-192
8. Griffiths ER, McCormick CC. Posttraumatic syringomyelia (cystic myelopathy). *Paraplegia* 1981;19:81-88
9. Rossier AB, Foo D, Shillito, et al. Progressive late posttraumatic syringomyelia. *Paraplegia* 1981;19:96-97
10. Barnett HJM, Bottrell EH, Jousse AT, Wynne Jones M. Progressive myelopathy as a sequel to traumatic paraplegia. *Brain* 1966;89:147-159
11. Quencer RM, Sheldon JJ, Donovan Post MJ, et al. Magnetic resonance imaging of the chronically injured spinal cord. *AJNR* 1986;7:457-464
12. Quencer RM, Morse BMM, Green BA, Eismont FJ, Brost P. Intraoperative spinal sonography: adjunct to metrizamide CT in the assessment and surgical decompression of posttraumatic spinal cord cysts. *AJNR* 1984;5:71-79
13. Jellinger K. Pathology of spinal cord trauma. In: Enrico TJ, Bauer RD, Waugh T, eds. *Spinal trauma*. Philadelphia: JB Lippincott, 1991:455-495
14. Kao CC, Chang LW. The mechanism of spinal cord cavitation following spinal cord transection. I. A correlated histochemical study. *J Neurosurg* 1977;46:197-209
15. Osterholm JL, Mathews GG. Altered norepinephrine metabolism following experimental spinal cord injury. I. Relationship to hemorrhagic necrosis and post-wounding neurological deficits. *J Neurosurg* 1982;36:386-394
16. Wolman L. The disturbance of circulation in traumatic paraplegia in acute and late stages. *Paraplegia* 1965;2:231-236
17. Ball MJ, Dayan AD. pathogenesis of syringomyelia. *Lancet* 1972;2:799-801
18. Williams B, Terry AF, Jones F, McSweeney T. Syringomyelia as a sequel to traumatic paraplegia. *Paraplegia* 1981;19:67-80
19. Mirvis SE, Geisler FH. Intraoperative sonography of cervical spinal cord injury: results in 30 patients. *AJR* 1990;155:603-609
20. Fox JL, Wener L, Drennan DC, Manz HJ, Won DH, Al-Mefty O. Central spinal cord injury: magnetic resonance imaging confirmation and operative considerations. *Neurosurgery* 1988;22:340-346