AJNR

Determination of blood flow direction using velocity-phase image display with 3-D phase-contrast MR angiography.

J R Pernicone, J E Siebert, T A Laird, T L Rosenbaum and E J Potchen

AJNR Am J Neuroradiol 1992, 13 (5) 1435-1438
http://www.ajnr.org/content/13/5/1435

Determination of Blood Flow Direction Using Velocity-Phase Image Display with 3-D Phase-Contrast MR Angiography

Joseph R. Pernicone,[1] James E. Siebert, Thad A. Laird, Terry L. Rosenbaum, and E. James Potchen

Summary: The authors describe their use of phase-contrast MRA to depict vascular anatomy and to define the direction of blood flow. Documentation of flow reversal can provide information regarding prognosis and can facilitate surgical planning. The technique requires no additional scan-time.

Index terms: Cerebral blood, flow; Magnetic resonance, 3-D; Magnetic resonance angiography (MRA)

Magnetic resonance angiography (MRA) is rapidly becoming a clinically useful modality (1–4). One difficulty, however, has been that to determine direction of flow in a vessel requires additional acquisitions that include carefully positioned saturation slabs (5). Recently, Pelc et al (6) enhanced the 3-D phase contrast method (7). In addition to total speed images—images with intensity related to the magnitude of the vector sum of the velocity in each primary direction—three sets of phase images can be calculated that contain both directional information and speed information along the three primary axes. The purpose of this report is to describe a method based on the work of Pelc et al to create images with flow directional information and illustrate its clinical utility.

Methods and Materials

As one part of our intracranial MRA protocol, data was acquired by using a 3-D gradient-refocused spin-warp velocity-compensated scan technique that incorporates nonzero first moment magnetic gradient sequences for phase-sensitive flow (phase-contrast MRA) (6). Acquisition parameters were 29/8.7/20° (TR/TE/flip angle), 60 contiguous 0.8-mm sections with a field of view of 20 cm, and acquisition matrix size of 256 × 192.

The 3-D phase-contrast acquisition method can provide four sets of images represented by the following equations:

$$v = \sqrt{v_x^2 + v_y^2 + v_z^2} \quad \text{Total speed} \qquad (A)$$

$$\phi_x - \phi_r \propto v_x f(G_x) \quad \text{X velocity component} \qquad (B)$$

$$\phi_y - \phi_r \propto v_y f(G_y) \quad \text{Y velocity component} \qquad (C)$$

$$\phi_z - \phi_r \propto v_z f(G_z) \quad \text{Z velocity component} \qquad (D)$$

ϕ_{xyz} represent the phase shifts in the primary directions caused by the flow encode gradient, ϕ_r represents the background phase shifts of a phase-reference acquisition; $f(G_{xyz})$ represent functions of the flow encode gradients, v_{xyz} are the velocity components, and v represents the magnitude of the total flow velocity vector. Equation A represents the total speed image. Equations B, C, and D represent phase images and state that the differences in phase shifts caused by the flow encode gradients along a primary axis are proportional to the speed of the flow along that primary axis scaled by a function of the flow encode gradient moment.

A phase shift difference from 0 to +180° represents flow with a velocity component in the given direction that is proportional to the phase shift difference. A phase-shift difference from 0 to −180° represents flow with velocity in the opposite direction. The speed that gives ±180° phase-shift difference depends upon the strength of the gradient flow encoding. Velocity components greater than these ±180° limits will be misrepresented due to "velocity aliasing." For instance, a phase-shift difference of +270° would be encoded as one of −90° and will appear in the image as flow in the opposite direction of ⅓ the speed. Hence, correct phase images require gradient flow encoding having a sufficiently high velocity range to prevent aliasing in the vessels of interest. The velocity range is set by the V_{ENC} value entered at acquisition time. For the cases illustrated in this report, the flow encode gradient chosen (V_{ENC}) is such that maximum signal will be given to a flow speed equal to 25 cm/sec. The V_{ENC} value was chosen by experience: high enough to visualize flow in major intracranial vessels, while still low enough to see relevant vessels with slower flow. This flow encoding would cause information obtained from larger vessels during systole to be

Received April 24, 1991; revision requested July 1; revision received on September 12 and accepted on November 27.

All authors: Department of Radiology Michigan State University, East Lansing, Michigan 48824.

[1] Address reprint requests to Joseph R. Pernicone, Michigan State University, B220 Clinical Center, East Lansing, MI 48824.

AJNR 13:1435–1438, Sep/Oct 1992 0195-6108/92/1305-1435 © American Society of Neuroradiology

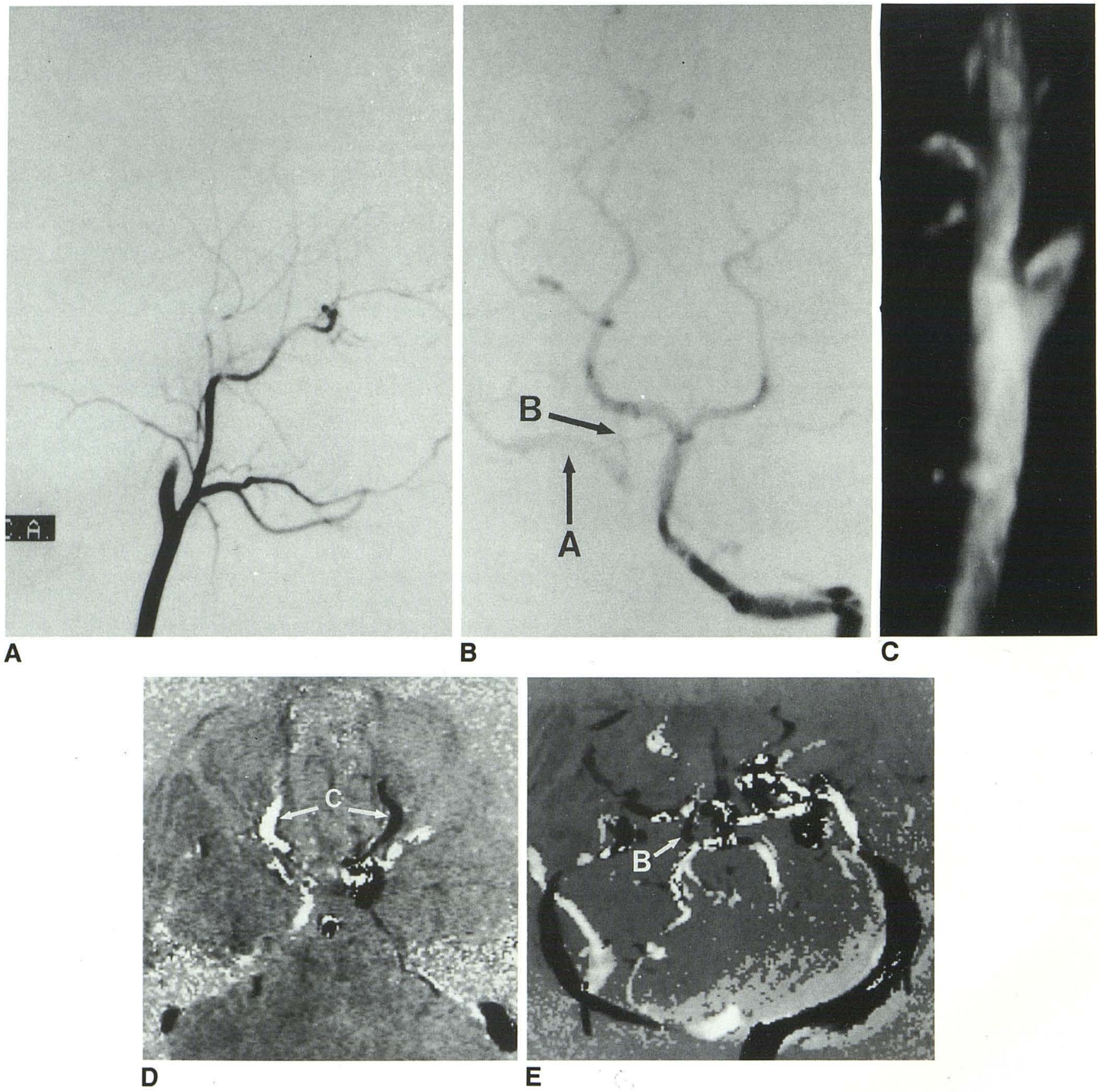

Fig. 1. Total occlusion of the right internal carotid artery secondary to a dissection (7-year-old boy).

A, DSA with right common carotid artery injection showing total occlusion of the right internal carotid artery proximally.

B, Contrast angiogram left vertebral injection. Reversal of flow in the tortuous right posterior communicating artery (*arrow B*) supplies the middle cerebral artery on the right side (*arrow A*).

C, Magnitude MRA MIP image through the right internal carotid artery correlates with the DSA exam.

D and *E*, Phase images velocity encoded for anterior-posterior flow information, maximum absolute value superior-inferior projection. Flow having a velocity component towards the anterior direction is represented by black vessel, while flow in a posterior direction is represented by white vessel. Retrograde flow in the right ophthalmic (*arrows C* indicate ophthalmic arteries) and right posterior communicating arteries (*arrow B*) is demonstrated.

velocity aliased; however, this did not appear to be a major problem.

When acquiring data with the General Electric Signa MRA package, phase-contrast technique, the option is given to obtain, in addition to the total speed images, three sets of phase images for anterior-posterior, right-left, and superior-inferior flow velocity components. Note that quantitative estimates of the flow in vessels can be made by multiplying the average pixel intensity within a vessel times its cross-sectional area.

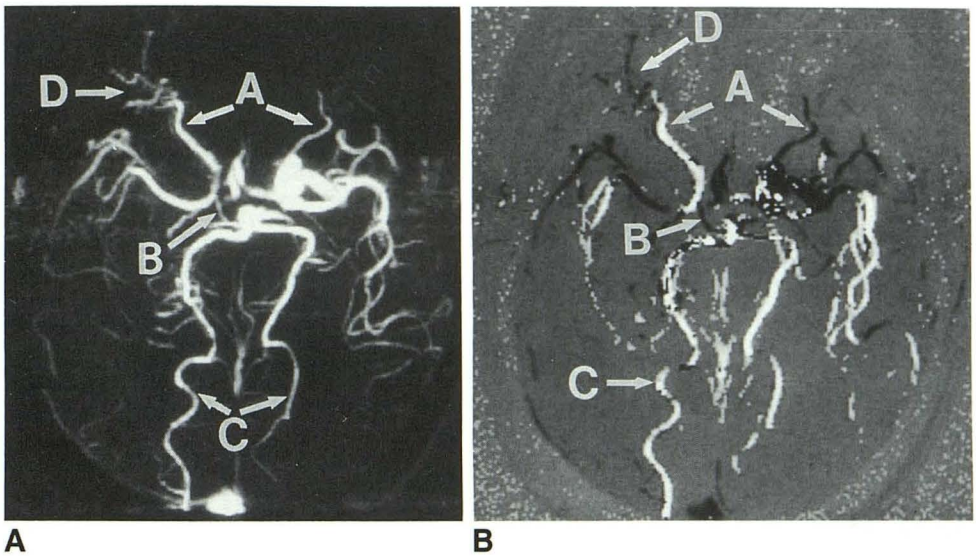

Fig. 2. Total occlusion of the right internal carotid artery (58-year-old woman).

A, Phase-contrast MRA total speed image, superior-inferior MIP.

B, Phase image demonstrating anterior-posterior flow information. Black vessels represent flow toward the anterior direction, while white vessels represent flow in a posterior direction.

Arrow A = ophthalmic arteries, *arrow B* = posterior communicating artery, *arrow C* = posterior cerebral arteries, *arrow D* = external carotid artery branches. Note that some vessels have both black and white appearance superimposed on each other. This is believed to be secondary to mismapping and aliasing artifacts arising from helical flow induced by artery curvature.

Projection images were produced from the total speed image data by the usual maximum intensity projection (MIP) method (8). Projection images from the phase images, however, were computed by using a new maximum absolute value algorithm. Conventional MIP of phase-image data would remove flow features having a negative sign. We determined that an effective projection method is to select the voxel having the maximum absolute value along a given projection ray path and then use that voxel's actual signed value for the projection image pixel. Thus, all flow features having sufficient magnitude velocity are represented in the maximum absolute value projection image. Direction of flow along a primary axis can be demonstrated in images by making background gray and allowing flow in one direction to be represented by varying grades of lighter gray levels and flow in the opposite direction by varying grades of darker gray levels. Projections of the entire data set or subvolumes of data could be viewed from any arbitrary angle about a primary axis.

Illustrative Cases

A 7-year-old boy, following a fall from a bicycle, presented with a right internal carotid artery occlusion secondary to an internal carotid artery dissection (Fig. 1). Digital subtraction angiography (DSA) demonstrated total occlusion of the right internal carotid artery just distal to the common carotid artery bifurcation. Contrast angiography demonstrated reversal of flow in the right posterior communicating artery. Six months later, 3-D phase-contrast MRA speed images demonstrated lack of flow in the right internal carotid artery proximal to the level of the right posterior communicating artery and increased flow in the right external carotid artery branches. The velocity phase images demonstrated reversed direction of flow in the right posterior communicating artery. In addition to the findings of 6 months previous, the velocity phase images demonstrated reversed direction of flow in the right ophthalmic artery as additional source for collateral flow to the distal right internal carotid and right middle cerebral arteries.

A similar example of flow reversal was demonstrated in a 58-year-old woman who presented after DSA (data not shown) showed lack of flow in the right internal carotid artery. An MRA study was performed (Fig. 2). The total speed images confirm the lack of flow in the right internal carotid artery proximal to the level of the right posterior communicating artery. Also, significantly decreased flow in the branches of the right middle cerebral artery is shown. Increased flow is observed in a prominent right posterior cerebral artery, presumably representing an attempt at collateral flow through the cortical branches on the right side to the right middle cerebral artery. The velocity phase images depicting flow velocity component in the anterior-posterior direction, reveal that the source of flow in the distal right internal carotid artery and right middle cerebral artery is retrograde flow from right external carotid artery collaterals through the right ophthalmic artery and from the right posterior communicating artery.

Discussion

The most common approach for observing flow direction in MRA is to apply saturation pulses

to produce "black blood" (5). The direction of flow in the vessel is determined by the displacement of the tagged blood. But this method requires additional time, only gives information about a limited number of vessels within the imaged volume, and may require the return of the patient. The method illustrated in this report requires no additional acquisition time, can be implemented as a routine protocol, and gives information about all the vessels in the imaged volume.

The direction of blood flow is frequently reversed as collateral vessels fill branches distal to arterial occlusions. Documentation of such flow reversal can be obtained with phase-contrast velocity phase images and can provide important information that may indicate patient prognosis, help plan surgery, as well as monitor response to therapy.

References

1. Pernicone JR, Siebert JE, Pera A, Potchen EJ, Dumoulin CL, Souza SP. Three dimensional phase contrast MR angiography in the head and neck. *AJNR* 1990;11:457–466
2. Masaryk TJ, Modic MT, Ross JS, et al. Intracranial circulation: preliminary clinical results with three-dimensional (volume) MR angiography. *Radiology* 1989;171:793–799
3. Ross JS, Masaryk TJ, Modic MT, Harik SL, Wiznitzer M, Sellman WR. Magnetic resonance angiography of extracranial carotid arteries and intracranial vessels: a review. *Neurology* 1989;39:1369–1376
4. Pernicone JR, Siebert JE. Clinical application of MR vascular angiography. Eighth annual meeting of the SMRM; 1989, Amsterdam, The Netherlands: *Book of abstracts*, p 155
5. Edelman RR, Mattle HP, Kleefield J, Silver MS. Quantification of blood flow with dynamic MR imaging and presaturation bolus tracking. *Radiology* 1989;171:551–556
6. Pelc NJ, Bernstein MA, Shimakawa A, Glover GH. Encoding strategies for three direction phase contrast MRI. *J Magn Reson Imaging* 1991; 4:405–413
7. Dumoulin CL, Souza SP, Walker MF, Wagle W. Three dimensional phase contrast angiography. *Magn Reson Med* 1989;9:139–149
8. Laub GA, Kaiser WA. MR Angiography with gradient motion refocusing. *J Comput Assist Tomogr* 1988;12:377–382