Are your MRI contrast agents cost-effective?
Learn more about generic Gadolinium-Based Contrast Agents.
FRESENIUS KABI
caring for life

AJNR

Severe unilateral white matter involvement on MR: hypothetical association with dental pain and infection.

L Ketonen, J E Riggs and P L Westesson

AJNR Am J Neuroradiol 1992, 13 (5) 1506-1507
http://www.ajnr.org/content/13/5/1506.citation

This information is current as of April 19, 2024.

LETTERS

MR Appearance of Hypertrophic Olivary Degeneration: Temporal Relationships

With regard to the article by Revel et al (1), who described the MR appearance of olivary hypertrophy after contralateral cerebellar hemorrhage, we want to contribute our observations on temporal relationships of MR findings in three patients with olivary hypertrophy of a different etiology.

The first patient was a 21-year-old man with severe closed head trauma. MR examination 3 months after the injury revealed extensive hemorrhagic contusions of the upper brain stem involving the central tegmental tract bilaterally; olivary hypertrophy was not demonstrable. Follow-up examination 15 months later showed symmetrical bilateral olivary hypertrophy. The patient had developed segmental myoclonias 11 months after injury.

The second patient was a 60-year-old woman with arterial hypertension who sustained right hemispheric cerebellar hematoma. Eleven months after the attack, MR disclosed mild enlargement and increased signal intensity of the contralateral olivary nucleus (Fig. 1A). At the same time, she developed palatolaryngeal myoclonus. On follow-up examination 6 months later, the signal abnormality and swelling of the left olivary nucleus was much less obvious (Fig. 1B). Clinically, segmental myoclonias were unchanged.

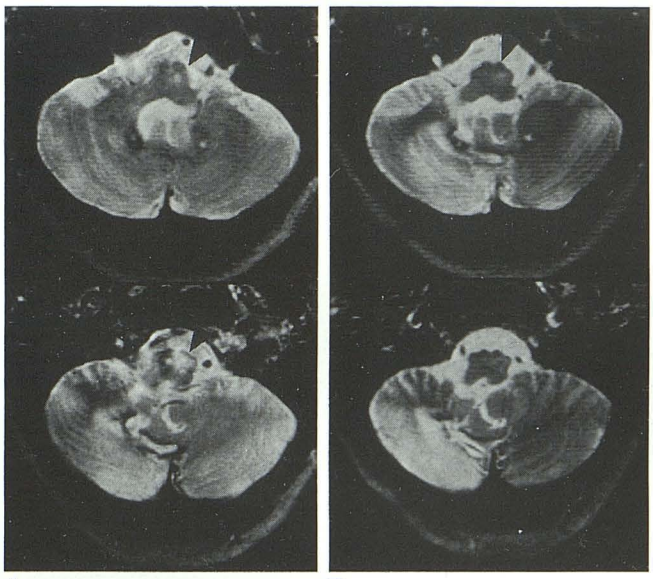

A B

Fig. 1. Olivary hypertrophy.

A, Axial MR images (2400/90/2) obtained 11 months after right cerebellar hemorrhage show mild enlargement of the left olivary nucleus with high signal intensity (*arrowheads*).

B, Axial MR images (2400/90/2) obtained 6 months later show significant decrease in signal intensity (*arrowheads*) as compared to the initial study.

The third patient, a 29-year-old woman, was examined 10 years after tegmental hemorrhage. MR detected increased signal intensity bilaterally in the area of the olivary nuclei, but no evidence of olivary enlargement was present. Segmental myoclonias were absent in this case.

In a chronological study of olivary hypertrophy, Goto and Kaneko (2) performed serial autopsy investigations in patients who had died between 16 hours and 9½ months after primary pontine hemorrhage. They found that hypertrophy of the neurons began about 3 weeks after the hemorrhage, without accompanying glial changes. In a later stage, hypertrophy, but not proliferation of the astrocytes, was noted, while the neurons remained hypertrophied. Later on, a gradual decrease in the number of neurons and persistence of the astrocytic hypertrophy could be observed. In concordance with this study, our observations suggest three stages of olivary hypertrophy. In the acute stage, alterations detectable by MR are usually not present. After a variable time interval, olivary enlargement and increased signal intensity on long TR sequences develop. The changes are usually more significant in proton density-weighted images than in T2-weighted images. Yokota et al (3) supposed that this could be due to an increase in the intracellular water content of enlarged neural bodies in the olivary nucleus. In a late stage, the size of the olivary nucleus may return to normal, whereas some increase in signal intensity can usually be observed. In summary, the time-dependent MR pattern in the inferior olivary nucleus has to be taken into account in the evaluation of patients with segmental myoclonias.

Günther Birbamer
Wolfgang Buchberger
Stefan Felber
Franz Aichner
Department of Magnetic Resonance Imaging and Spectroscopy
University of Innsbruck
Anichstrasse 35
A-6020 Innsbruck
Austria

References

1. Revel MP, Mann M, Brugieres P, Poirer J, Gaston A. MR appearance of hypertrophic olivary degeneration after contralateral cerebellar hemorrhage. *AJNR* 1991;12:71–72
2. Goto N, Kaneko M. Olivary enlargement: chronological and morphometric analyses. *Acta Neuropathol (Berl)* 1981;54:275–282
3. Yokota T, Hirashima F, Furukawa T, Tsukagoshi H, Yoshikawa H. MRI findings of inferior olives in palatal myoclonus. *J Neurol* 1989; 236:115–116

Reply

We would like to thank Dr Birbamer for his contribution to the MR study of hypertrophic olivary degeneration, especially as concerns patterns of evolution. In Dr Birbamer's cases, the MR study performed 3 months after the causal disease failed to disclose any olivary abnormality; the earliest demonstration of olivary hypertrophy was seen 11 months after the onset of disease. Then, olivary nucleus hypertrophy was seen in association with high signal intensity on T2-weighted images.

In a very late stage (10 years), there was no MR hypertrophy while signal changes remained detectable. Our experience is similar.

Since our first published case, we encountered two additional cases in AIDS patients. The first one (case I) was examined for follow-up study, 12 months after a toxoplasma encephalitis. MR showed bilateral post-Gd-DTPA-enhancing lesions involving both dentate nuclei (Fig. 2A). Bilateral high signal areas were demonstrated in the medulla oblongata at the site of the olivary nuclei. In this case, because of the bilateral involvement of the olivary nuclei, hypertrophy could not be assessed (Fig. 2B).

The second case (case II) concerned a unilateral hypertrophic degeneration secondary to a progressive multifocal leucoencephalopathy (PML), involving the dentate nucleus (Fig. 3A). We believe that the dentate nucleus involvement concerned the myelinated fibers, as previously described in a similar case of PML with necrotic lesions of the dentate nucleus and efferent fibers (Gray P, personnal communication).

The MR study showed unilateral high signal intensity in the contralateral olive, with no olivary enlargement (Fig. 3B). MR study performed 5 months earlier was normal.

Follow-up MR examination in our previously reported case (case III) (1), was performed 20 months after the dentate nucleus hemorrhage. High signal was still visible, but olivary hypertrophy had disappeared (Figs. 4A and 4B).

In summary, we believe that MR abnormalities are delayed, and may be seen 3 to 5 months after the causal disease. The degree and nature of the initial disease may also influence the pattern of evolution, but this remains a matter of discussion since no pathologic data support this hypothesis.

We agree with Dr Birbamer that hypertrophy is a tran-

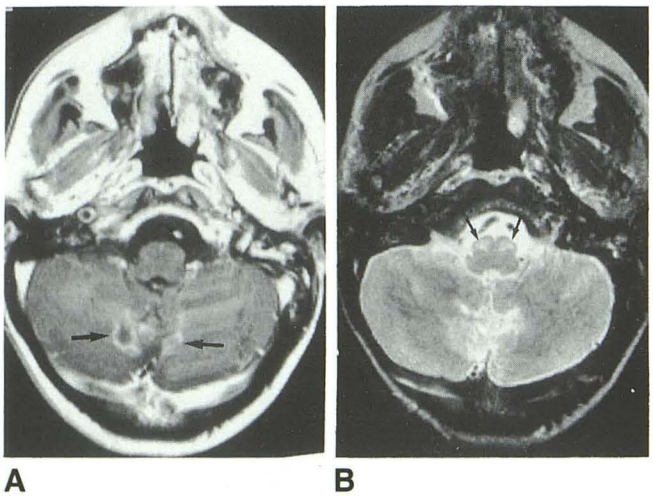

Fig. 2. Case I; patient with AIDS examined 12 months after toxoplasma encephalitis.

A, Axial T1-weighted image (600/20/2) showing enhancing lesions of both dentate nuclei (*arrows*).

B, Axial T2-weighted image (2500/120/2) showing bilateral high signal of the olivary nuclei (*arrows*).

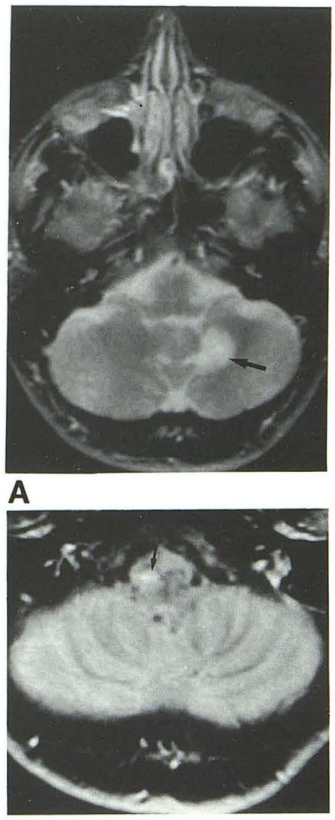

Fig. 3. *A*, Case II; axial T2W image (2500/120/2) demonstrating a high-signal area in the left dentate nucleus (*arrow*).

B, Case II; axial proton density sequence (2000/60/2) showing high signal in the right olivary nucleus (*arrow*). No enlargement is demonstrated.

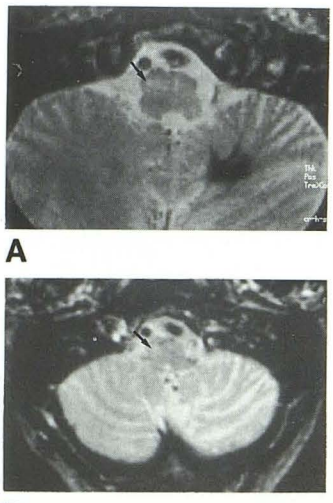

Fig. 4. *A*, Case III; olivary hypertrophy is seen in association with signal changes on T2WI (2500/120/2) (*arrow*).

B, 12 months later (20 months after the causal disease), MR (2500/120/2) shows that hypertrophy has disappeared, while signal changes remain detectable (*arrow*).

sient state in olivary degeneration since our first case showed similar changes (hypertrophy disappearance on 20 months follow-up study).

Marie-Pierre A. Revel, MD
Andre P. Gaston, MD
Francoise Gray, MD
Service de Neuroradiologie
Hôpital Henri Mondor
94000 Creteil
France

Reference

1. Revel MP, Mann M, Brugieres P, Poirier J, Gaston A. MR appearance of hypertrophic olivary degeneration after contralateral cerebellar hemorrhage. *AJNR* 1991;12:71–72

Retroclival Arachnoid Cyst

We read with interest the case report of a retroclival arachnoid cyst by Bourekas et al (1) as we have recently seen a similar case of a large retroclival cyst that extended cephalad into the suprasellar cistern.

A 15-year-old girl presented several weeks after a single episode of "arm and leg jerking" felt to represent a tonic-clonic seizure. Past medical history was remarkable for a lifelong history of headaches, some of which were associated with emesis during the past year. Physical and neurologic examinations were normal. The patient was begun on anticonvulsant therapy and underwent MR scanning (Fig. 1) that demonstrated a large extra-axial lesion anterior to the brain stem extending from the pontomedullary junction cephalad to fill the majority of the suprasellar cistern. The pons and midbrain were posteriorly displaced and flattened, and the tuber cinereum was elevated with stretching of the pituitary stalk by this lesion. Enlargement of the supratentorial ventricular system was seen. The lesion was isointense with cerebrospinal fluid (CSF) on all imaging sequences, did not demonstrate contrast enhancement, and was felt to be most consistent with an arachnoid cyst. On an elective basis, stereotactic cyst puncture with a blunt ventricular catheter was unsuccessfully attempted. At subsequent craniotomy, the cyst was fenestrated (with collection of normal CSF) and decompressed as confirmed by postoperative CT.

Arachnoid cysts are common extra-axial lesions that uncommonly occur along the clivus. It is relatively easy to diagnose an arachnoid cyst on MR if the extra-axial cyst has no internal architecture, does not demonstrate contrast enhancement, and its contents demonstrate CSF signal intensity on all imaging sequences. However, as in Bourekas et al's case (1), arachnoid cysts can be complicated by hemorrhage and, therefore, may not demonstrate imaging characteristics identical to CSF. Similarly, motion artifacts from arterial or CSF pulsations transmitted into an arachnoid cyst can result in abnormal signal from within the cyst.

The entity that most commonly can be difficult to differentiate from an arachnoid cyst is an epidermoid tumor, a congenital lesion that results from inclusion of ectodermal tissue during developmental closure of cranial structures. Epidermoid tumors usually demonstrate a morphologic appearance and MR signal characteristics that allow differentiation from arachnoid cysts. Unlike arachnoid cysts, epidermoids have a greater tendency to envelope rather than displace nearby structures (ie, less mass effect) and these tumors usually do not demonstrate signal intensity similar to CSF on all imaging sequences (ie, the signal on long TR, short TE scans is greater than CSF in epidermoids (2)).

We, and others (3), have noticed that, in some instances, for the reasons mentioned above, it can be difficult to differentiate an arachnoid cyst from an epidermoid tumor. In such instances, diffusion imaging can help differentiate

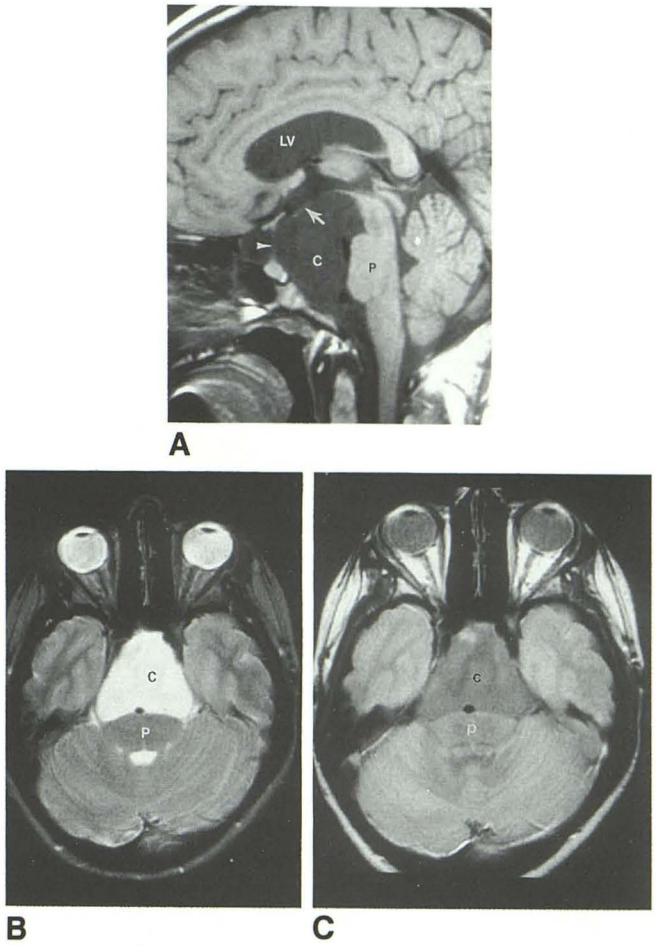

Fig. 1. Sagittal T1-weighted (600/20) (*A*) and axial T2-weighted (2500/90) (*B*) and proton density (2500/30) (*C*) 1.5-T MR scans through the brain stem demonstrate a large retroclival arachnoid cyst (*C*) which is isointense with CSF on all imaging sequences. The cyst posteriorly displaces and flattens the brain stem (*P* = pons) and extends into the suprasellar cistern where it elevates the tuber cinereum (*arrow*) stretching the pituitary stalk (*arrowhead*). Enlargement of the lateral ventricles (*LV*) consistent with obstructive hydrocephalus is also seen.

solid from more cystic lesions. Diffusion imaging involves the measurement of brownian motion of protons within a lesion (3) that will be significantly greater in cystic lesions (eg, arachnoid cysts) than in solid lesions (eg, epidermoid tumors).

Douglas J. Quint, MD
University of Michigan Hospitals
Ann Arbor, MI

References

1. Bourekas EC, Raji MR, Dastur KJ, Francken GJ, Engle DJ, Nayak NT. Retroclival arachnoid cyst. *AJNR* 1992;13:353–354
2. Tampien D, Melanson D, Ethier R. MR imaging of epidermoid cysts. *AJNR* 1989;10:351–356
3. Tsuruda JS, Chew WM, Moseley ME, Norman D. Diffusion-weighted MR imaging of the brain: value of differentiating between extraaxial cysts and epidermoid tumors. *AJNR* 1990;11:925–931

Editor's note: The above letter was forwarded to Dr Bourekas for comment. In Dr Bourekas' opinion, Dr Quint's letter includes an excellent example of a retroclival arachnoid cyst. Since the comments of Dr Quint are in agreement with his own case report, Dr Bourekas did not have any further information to add.

Handgun Control: A Public Health Imperative

The growing problem of violence in our society is recognized by all but especially those of us in the specialty of neuroradiology who deal with emergency room patients with head or spine injuries. Firearms, in particular handguns, are the leading instruments of this violence (1, 2, 3). In 1991, 60% of all suicides and homicides were committed using firearms. Of these homicides committed by firearms, 75% involve handguns. Although the role of handguns in these fatalities is not in question, an essential issue in research on the prevention of handgun related mortality is whether limiting the access to handguns would have any effect on these deaths. The debate surrounding this question has been a political issue with strong arguments on both sides of the question of whether to restrict access to handguns.

Many Americans believe that possession of guns is guaranteed by the Bill of Rights. Guns are felt to be protection for the individual in a crime-ridden society. Guns are also an essential part of several hunting and target sports as well as the hobby of gun collecting. Unlike some countries, firearms are embedded in our American history and are strong cultural icons appealing to our sense of pride in American individuality and a "frontier" spirit.

Other individuals feel that, while violence is ubiquitous throughout society, the availability of firearms and handguns increases the magnitude of personal injury. Although anyone can lose their temper, anger expressed with a frying pan against a spouse or loved one is usually medically less significant than similar anger expressed with a 38-caliber pistol. Suicides also tend to be more successful when attempted with firearms compared to some other methods.

Until very recently, there has been little conclusive scientific evidence either pro or con concerning the effect of restrictive licensing of handguns on homicide and suicide in America. The debate was based almost entirely on emotional and political issues. However, there has been a growing body of scientific medical evidence addressing this area that is most recently represented by a compelling article in the December 1991 issue of the *New England Journal of Medicine*. In this article, Loftin and his coworkers (1) examine the effects of the 1976 law in the District of Columbia that banned the purchase, sale, transfer, or possession of handguns by civilians. All homicides and suicides committed from 1968 to 1987 were then classified according to location either within the District of Columbia or in adjacent metropolitan areas (where the law did not apply), mechanism of death (firearms or other means), cause of death (homicide or suicide), and date of occurrence (either before or after implementation of the restrictive legislation).

In the District of Columbia, the adoption of the handgun licensing law corresponded with a 25% reduction in homicides by firearms and a 23% reduction in suicides by firearms. No similar reductions were present over the same time frame in the number of homicides or suicides committed by other means nor were there similar reductions in the adjacent metropolitan areas. They also noted that there was no compensatory increase in homicides or suicides by other methods. Other lethal means were not merely substituted for the now less available handguns.

What was, prior to the emergence of this strong scientific evidence, merely a controversial political and social debate has now become a clear-cut medical and public health imperative. As physicians, we should acknowledge that the growing epidemic of injury and death from handguns consumes limited health dollars and medical care resources and wastes human life. The medical profession must take a position based on scientific evidence to confront this important public health issue in order to guide legislation. This is not unlike the similar situation of tobacco usage where, as scientific evidence grew, the medical community discarded emotional and political issues to become a single voice united for the public good.

Faced with this evidence, we must persuade our neuroradiological societies to adopt policies advocating the restriction of private ownership of handguns and automatic rifles and encourage these societies to exert additional pressure to influence state and federal legislation. With this growing scientific evidence, the entire issue of restrictive licensing of handguns has been changed from a political to a public health issue and we as neuroradiologists are morally and ethically obligated to act.

Robert B. Lufkin, MD
Associate Professor of Neuroradiology
Chief of Neurosciences Imaging
UCLA School of Medicine
Los Angeles, CA

References

1. Loftin C, McDowall D, Wierscma B, Cottey T. Effects of restricting licensing of handguns on homicide and suicide in the district of Columbia. *N Engl J Med* 1991;325:1615–1620
2. Kassirer J. Firearms and the killing threshold. *N Engl J Med* 1991; 325:1647–1650
3. Department of Health and Human Services, National Center for Health Statistics. Mortality detail file, 1968–1987. Ann Arbor, MI: Inter university consortium for political and social research (distributor), 1990 (computer files)

Biopsy of Vertebral and Paravertabral Structures with a New Coaxial System

The recent article by Geremia et al (1) describes a new coaxial needle system which has proved useful in the biopsy of vertebral and paravertebral lesions. We would like to describe a less expensive means for achieving similar results.

We begin our spinal biopsies in the usual manner, advancing a 22-gauge Greene biopsy needle (Cook Inc, Bloomington, IN) to the surface of the bone. After the periosteal region is infiltrated with lidocaine, the hub of the needle is removed by cutting with sterile stainless steel wire scissors (Stuart Drug and Surgical Supply, Franklin, MA). The needle is easily clipped with this device, creating a clean cut with no fragmentation of the needle. The hubless needle is then left protruding from the skin surface. This hubless needle serves as a stiff metal guide, over which a larger bone biopsy needle is advanced in a coaxial manner. We use an Ackermann 12-gauge bone-cutting needle (Cook Inc).

After the bone biopsy is obtained, the wire scissors and the Ackermann needle set are resterilized for future use. The cost of the disposable Greene needle (approximately $11.00) compares favorably with the cost of the new disposable system described by Geremia et al (currently, about $97.00).

The sterile wire scissors are readily available in our hospital through Central Supply. Alternatively, they may be purchased for about $17.00 and resterilized in the Radiology Department. Other types of sterilizable wire cutters could also be used.

Jennifer Fife, MD
Elizabeth Hawkes, RTR
Matthew D. Ralston, MD
Department of Radiology
Maine Medical Center
22 Bramhall Street
Portland, ME 04102

Reference

1. Geremia GK, Charletta DA, Granato DB, Raju S. Biopsy of vertebral and paravertebral structures with a new coaxial system. *AJNR* 1992; 13:169–170

Reply

Dr Fife and coworkers describe a coaxial technique similar to the one described in our recent article. In their opinion, the use of a 22-gauge Greene needle, Ackermann 12-gauge biopsy needle, and wire scissors "compares favorably with the cost of the new disposable system" we described.

First of all, we believe the overall cost of their system including materials and associated charges for resterilization, makes the price of our system ($97.50) competitive. The price of a disposable Greene needle (Cook Inc, Bloomington, IN), used by them, lists for $21.00, not $11.00 as mentioned by Fife. The Ackermann needle (Cook Inc) sells for $185.00. This needle is reusable. However, the cutting tip is dulled with repeated use in bone and eventually requires resharpening. The cost for resterilization of such a needle system at our institution is about $7.00.

The difference in total expense between the two systems, if any, is hardly significant considering the fact that we believe our system is simpler, safer, and less traumatic for both patient and operator. Cutting a 22-gauge needle with a wire scissors, as recommended by Fife and coworkers, would leave a sharp, irregular metal tip exposed at the skin surface. The potential for infection of the operator therefore is greater, and although unlikely, could be life threatening. This step is unnecessary with the removable hub 22-gauge needle included in our system.

Lastly, the 16-gauge biopsy needle (0.0655 inches) which we use is considerably smaller in outer diameter than the 12-gauge Ackermann needle (0.1100 inches) and thus potentially safer and less likely to induce immediate or postprocedural pain (Fig. 1). The cross-sectional area of a puncture produced by our system is 34% that of the Ackermann needle. The implications for accidental puncture of the pleura, nerve roots, or arteries should be obvious.

We prefer the smaller 16-gauge needle system. We believe it is safer, less traumatic, and associated with less pain and anxiety for the patient.



Fig. 1. Ackermann 12-gauge needle (*top*); Geremia 16-gauge biopsy needle (*bottom*).

Glen K. Geremia, MD
Dale A. Charletta, MD
Subba Raju, MD

David Granato, MD
Tae Woo Kim, MD
Rush-Presbyterian-St. Luke's Medical Center
Department of Diagnostic Radiology
1653 W. Congress Parkway
Chicago, Illinois 60612

Severe Unilateral White Matter Involvement on MR: Hypothetical Association with Dental Pain and Infection

White matter abnormalities in adults are often a diagnostic dilemma because most lesions have somewhat similar MR appearances. Extensive unilateral lesions are rare and suggest a very specific etiology. We saw a patient with extensive unilateral high signal lesions and suggest a possible pathogenetic mechanism. Since the classical ventriculopetal/ventriculofugal vascular border zone theory in the etiology of deep white matter changes may be erroneous (1), a major neuroradiologic issue is left unanswered. The suggested pathogenetic mechanism may provide an explanation for the development of diffuse white matter high-signal changes seen in some elderly people.

A 48-year-old man presented with acute onset of severe continuous pain from a right upper fractured and infected premolar tooth. Two weeks later, he developed severe bifrontal headaches. Neurologic examination, Doppler ultrasound of neck vessels, and cerebrospinal fluid analysis were normal. The MR scan (1.0 T) (Fig. 1) demonstrated extensive high signal lesions limited to the right corona radiata and centrum semiovale on the T2-weighted, 2000/25,90/1 (TR/TE/excitation) images. Intravenous gadolinium revealed no abnormal enhancement. The contrast-enhanced CT showed diffuse white matter low density in the same area. Follow-up CT and MR scans 3 weeks and 1 year later were unchanged.

There are a number of high-signal white matter lesions without specific MR findings. Often the patient's age and clinical history may narrow the differential diagnosis. The broad differential diagnosis of multiple high-signal lesions include vascular lesions, inflammatory and demyelinating diseases, AIDS, PML, Lyme's disease, and acute disseminated encephalitis. Most of these lesions are, however, typically bilateral. Stenosis/occlusion of the carotid artery in combination with hypoxia or hypotension may lead to unilateral watershed infarction.* However, in this case, there was no history or evidence to suggest such an episode.

The pathogenesis may be related to neurogenic regulatory mechanisms of cerebral blood flow. Sato and Suzuki mapped the innervation of intracranial arteries and described dense sympathetic innervation from superior cervical ganglion to the distal internal carotid artery and vessels at the circle of Willis (3). Therefore, pain or inflammation in or above the neck may cause retrograde stimulation of the ipsilateral superior cervical ganglion that could trigger ipsilateral cerebral vasospasm resulting in ischemic changes or, alternatively, resulting in increased ipsilateral intimal permeability (4). The combination of increased permeability and the systemic production of antibodies and immune complexes from the persistent dental infection may result in vascular compromise followed by unilateral ischemic changes in the affected areas.

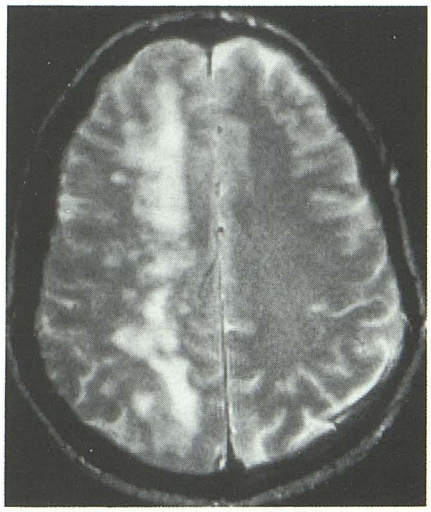

Fig. 1. Axial T2-weighted MR images 2000/90/1 (TR/TE/excitation) through the centrum semiovale shows extensive unilateral deep high-signal foci without mass effect in the right hemisphere.

A combination of the effect of the autonomic nervous system (local factor) and the immune system (systemic factor) has been postulated to be a pathogenetic mechanism in Moya Moya disease (4). Circumstantial evidence of the same mechanism was seen in a case of occlusion of distal internal carotid artery following a wasp sting in the facial area (5). The same mechanism was also postulated to explain the ischemic brain infarction leading to hemiparesis in a series of five previously healthy children with primary varicella zoster virus infection (chickenpox) (6).

It is possible a genetically susceptible population subset may exist who are prone to develop white matter lesions following stimulation of the superior cervical ganglion.

Leena Ketonen, MD, PhD[1]
[1]*University of Rochester*
Rochester, New York 14642

Jack E. Riggs, MD
West Virginia University
Morgantown, WV 26506

Per-Lennart Westesson, DDS, PhD[1]
David H. Halpert, MD
Twin Tier Neurologic Association
Elmira, NY 14905

* Drayer BP. Brain infarction. Syllabus, Categorical Course in Diagnostic Radiology: MR Imaging. RSNA Division for Educational and Publishing Services, 1988:39–52

References

1. Nelson MD, Gonzalez-Gomez I, Gilles FH. The search for human telencephalic ventriculofugal arteries. *AJNR* 1991;12:215–222
2. Sato S, Suzuki J. Anatomical mapping of the cerebral nervi vasorum in the human brain. *J Neurosurg* 1975;43:559–568
3. Suzuki J. *Moyamoya disease.* New York: Springer-Verlag, 1983: 131–143
4. Romano JT, Riggs JE, Bodensteiner JB, Gutmann L. Wasp sting-associated occlusion of the supraclinoid internal carotid artery: implications regarding the pathogenesis of moyamoya syndrome. *Arch Neurol* 1989;46:607–608
5. Bodensteiner JB, Hille MR, Riggs JE. Clinical features of vascular thrombosis following varicella. *Am J Dis Child* 1992;146:100–102

Editor's note: The above letter was referred to Michael A. Moskowitz, MD, Associate Professor of Neurology at Harvard Medical School and Director of the Stroke Research Laboratory in the Department of Neurosurgery at the Massachusetts General Hospital. His reply follows.

Reply

I am aware of the mapping work done by Sato and Suzuki. Functionally, the mechanism proposed by Ketonen et al is most unlikely to be important in the pathophysiology here because: 1) it has not been shown, to my knowledge, that stimulating the superior cervical ganglia will cause focal blood vessel narrowing or reduction in blood flow except under very extreme conditions, and 2) the tissue most likely to be affected, if in fact the superior cervical ganglia did cause such an effect, is the cortical gray matter, and not white matter.

Michael A. Moskowitz, MD
Associate Professor of Neurology
Harvard Medical School
Cambridge, MA

MR Imaging of Various Oxidation States

We read with interest the recent article, "MR Imaging of Various Oxidation States of Intracellular and Extracellular Hemoglobin" (1) and would like to pose two questions to the authors:

1. *What is the accuracy of their technique that uses TE's of 30, 60, 90, and 120 milliseconds to measure T2's of less than 17 milliseconds (ie, relaxation rates of over 60 sec^{-1})?*

Since the data were collected under conditions in which less than 20% of the net magnetization was present during the first (30 msec) echo and less than 3% during the second (60 msec) echo this is an important issue. Thus, noise plays an important role when the signals are this weak. There is an absence of error bars on the graphs and no mention in the text concerning the standard deviation or systematic errors that were encountered. The omission of this information could lead the reader to have undue confidence in the author's data.

2. *Has the observed T2 preferential relaxation enhancement (PRE) been artificially augmented by the addition of extracellular bovine serum albumin to the blood?*

This is an important consideration since the authors have changed the *extracellular* protein concentration from 6–8 g/dL which is present in plasma to a level that approximates the concentration of *intracellular* hemoglobin concentration (37 g/dL). Previously published work indicates that this degree of change (from 6 to 37 g/dL) will reduce the self-diffusion coefficient of water by 50% to 70% (2, 3). A reduction of this magnitude in the self-diffusion coefficient should produce a *three-fold increase* in the time it takes water to diffuse a given distance since these factors are inversely related. According to Luz and Meiboom, a two- to threefold increase in diffusional time will produce a two- to threefold increase in T2 PRE (4). Thus, addition of bovine serum albumin appears to have caused the majority of the authors' R value (60 sec^{-1}). In fact, it is *three* times larger than the R value (20 sec^{-1}) which was measured with an interecho interval of 32 milliseconds at 1.41 T for blood suspended in plasma at hematocrit 45% (5).

To correct for this artificial elevation in R value, one must reduce the authors' observed R value of 15 sec^{-1} at a hematocrit of 90% to about 5 sec^{-1} (ie, a threefold reduction). While 5 sec^{-1} is significant, it is insufficient to fully account for the observed hypointensity of hemorrhage on clinical T2-weighted images.

Thus, it is difficult to accept the authors' conclusion that, "The profound hypointensity of acute and early subacute hemorrhages on long TR/long TE images is a function predominantly of the susceptibility effects of intracellular DeoxyHb or intracellular MetHb."

References

1. Janick PA, Hackney DB, Grossman RI, Asakura T. MR imaging of various oxidation states of intracellular and extracellular hemoglobin. *AJNR* 1991;12:891–897
2. Abetsedarskaya LA, Miftakhutdinova FG, Fedotov VD. State of water in live tissues (results of investigations by the NMR-spin echo method). *Biophysics (USSR)* 1968;13:750–758
3. Finch ED, Harmon JF. Diffusion of water in muscle and blood as measured with pulsed nuclear magnetic resonance. *Cryobiology* 1971;8:379
4. Luz Z, Meiboom S. Nuclear magnetic resonance study of the protolysis of trimethylammonium ion in aqueous solution: order of the reaction with respect to solvent. *J Chem Phys* 1968;39:366–370
5. Gomori JM, Grossman RI, Yu-Ip C, Asakura T. NMR relaxation times of blood: dependence on filed strength, oxidation state, and cell integrity. *J Comput Assist Tomogr* 1987;11:684–690

Joseph J. Ford
Katherine H. Taber
L. Anne Hayman
Department of Radiology
Baylor College of Medicine
Houston, Texas

Reply

Drs Ford et al have raised two questions with regard to our paper concerning the influence of T2 preferential relaxation enhancement (T2 PRE) in magnetic resonance (MR) imaging of hemorrhage (1). Unfortunately, their questions appear to reflect a misunderstanding of the experimental methods we employed and the results we obtained. We believe that the following restatement and clarification of these points should resolve any lingering confusion. Detailed responses to the issues raised by Drs Ford et al are presented below. To summarize, in question 1 we are asked why we have used interecho times of 30 msec to measure T2 values and to provide an indication of the precision of our data. We have used 30 msec interecho times because these are typical of interecho times that are used for clinical imaging. Although much shorter interecho times, on the order of 1–2 msec, are usually employed in spectrometry, these interecho times are *never* employed in routine clinical spin-echo imaging. Since the magnitude of the magnetic susceptibility inhomogeneity contribution to 1/T2 is highly dependent upon the interecho time, a study that attempts a model in vivo T2 behavior in the presence of significant inhomogeneity effects, as observed in clinical imaging, must employ clinical interecho times (2).

Ford and colleagues imply that error bars are the only potential source of information concerning the precision of the relaxation rate determinations. However, they have overlooked the fact that, for all of the linear plots, R squared values were provided in Table 1 (p 893) (1). These R squared values indicate that there are excellent linear fits for all 1/T1 determinations as well as for the 1/T2 determinations for which the model suggests a linear relationship to albumin or hemoglobin concentration. Similarly, for those samples in which the 1/T2 should not be a linear function of hemoglobin concentration, ie, intracellular deoxyhemoglobin and intracellular methemoglobin—the adequacy of the fits to the predicted curve also indicates that these are precise determinations.

In question 2, Ford and colleagues suggest that the PEDD-PRE 90% hematocrit data point must be "corrected" to adjust for the high bovine serum albumin (BSA) concentration present within this sample. Their "correction" results in a substantial decrease in 1/T2. They claim that the "corrected" 1/T2 is "insufficient to fully account for the observed hypointensity of hemorrhage on clinical T2-weighted images". This interpretation is meaningless for several reasons.

1. Ford et al are discussing (we gather) the 90% Hct points, indicated by hollow circles and labeled "Extracellular" on Figure 3B and "Protein + PEDD-PRE" on Figure 3C. These points correspond to the 15 sec^{-1} value cited by Ford et al. These points, as is clearly explained in the text, represent the magnitude of 1/T2 due only to protein concentration and PEDD-PRE. These points *exclude* the contribution of magnetic susceptibility to 1/T2. The statement that PEDD-PRE alone is "insufficient to fully account for the observed hypointensity of hemorrhage on clinical T2-weighted images" is one of the major conclusions of our paper. We are gratified that Ford et al agree. However, we refer Ford et al to our manuscript in which we make this point in several locations. In the Results section of our paper, on page 893, first column, we state:

> "Figure 3A demonstrates that the T1 relaxation rate for intra- and extracellular DeoxyHb in BSA is virtually independent of the concentration of DeoxyHb. *This confirms the absence of significant PEDD proton relaxation enhancement (PRE), as previously described* (4).
>
> The effects of DeoxyHb on the T2 relaxation rate are much more dramatic (Fig. 3B). As with the T1 relaxation rate, there is little change in the T2 relaxation rate with increasing concentration for extracellular DeoxyHb. *This again demonstrates the small contribution to the T2 relaxation rate from PEDD interaction.*"

Later on page 893, second column, we state:

> "In Figure 3C, the T2 relaxation effects attributable to the inhomogeneity effect alone are compared with the combined T2 relaxation rates due to protein and PEDD-PRE. From these data it is readily apparent that significant contributions to the T2 relaxation rate are produced even at Hct values of 10% or 90% that are *as great or greater than the effects due to the protein and PEDD-PRE effects alone.*"

Similar considerations apply to intracellular methemoglobin. In Figure 5 of our paper we reported the results for intracellular and extracellular methemoglobin diluted in BSA. Concerning these data we stated on page 894, column 1:

> "As seen by the minor rise in T2 relaxation rate for extracellular MetHb as a function of Hct, *the PEDD-PRE contribution to T2 relaxation is small.*"

The limited influence of the PEDD-PRE effect of deoxyhemoglobin upon T2 relaxation rates was reiterated in the Discussion on page 894 where we stated:

> "The T2 shortening effects of the high-spin ferrous heme of DeoxyHb is even smaller, *indicating an absence of PEDD-PRE effects.*"

Finally, on page 896, second column, we summarize our findings and stated:

> "The profound hypointensity of acute and early subacute hemorrhages on long TR/long TE images is a function predominantly of the susceptibility effects of intracellular DeoxyHb or intracellular MetHb."

We believe that the statements quoted above make it abundantly clear that the PEDD-PRE interaction is not adequate to explain the hypointensity of in vivo hemorrhage and that magnetic susceptibility variations play a major role in determining the relaxation rates of acute and subacute hemorrhage.

2. We are puzzled that Ford et al, decided to ignore the other data presented in Figures 3B and 3C. The filled squares labelled "Intracellular" in Figure 3B and "Inhomogeneity" in 3C represent the contribution of inhomogeneous magnetic susceptibility to the 1/T2. Although we shall see that the "correction" proposed by Ford et al is based upon

a misunderstanding of the Materials and Methods section of our paper, let us address the consequence of the "correction" if it were appropriate. The 1/T2 of the intracellular deoxyhemoglobin suspension is the sum of the contributions to 1/T2 of the protein concentration, PEDD-PRE, and inhomogeneity. The filled squares in Figure 3C were obtained by subtracting the "Extracellular" values in Figure 3B from the "Intracellular" values. If there were an artifactual increase in the 90% Hct PEDD-PRE value, this would lead to an *underestimate* of the inhomogeneity contribution to the observed 1/T2 for intracellular deoxyhemoglobin.

3. It is clear that no "correction" of the PEDD-PRE point is indicated. We refer Drs Ford et al to the Materials and Methods section of our paper (p. 892). We indicated, we believed clearly, that all samples were prepared to a total protein concentration of 34 g/dL. We also stated that, at a hematocrit of 90%, the protein concentration is 34 g/dL. Consequently, the 90% hematocrit data point *contains no extracellular BSA*. Therefore, the relaxation rates observed in the 90% sample cannot possibly be influenced by the presence of BSA since no BSA is present in this sample. This should make it clear that the entire discussion of diffusion coefficients in protein solutions and the effect of extracellular protein upon T2 PRE is, with respect to our paper, meaningless. There is no postulated effect of extracellular BSA that may influence relaxation rates in a sample which does not contain any extracellular BSA.

The data presented in Figures 3B and 3C of our paper provide all the information that is needed to prove that it is the total protein concentration, not the presence of extracellular BSA that determines the relaxation rates of the "extracellular" (Figure 3B) and "PEDD-PRE" (Figure 3C) components (1). The 90% Hct sample contains no BSA. If Ford et al were correct in their assertion that BSA causes an increase in the PEDD-PRE contribution to 1/T2, then the 90% point should display a much slower relaxation rate than the samples with lower Hct values, which include BSA. Since the 90% point falls perfectly on the line defined by the lower Hct samples, there is no evidence that the absence of BSA in the 90% sample has resulted in a dramatic change in the relaxation rate (1). Thus, it is the total protein concentration, not the presence of BSA, which determines the relaxation rate.

Ford et al imply that the statement "insufficient to fully account for the observed hypointensity of hemorrhage on clinical T2-weighted images" contradicts our conclusion that "the profound hypointensity of acute and early subacute hemorrhages on long TR/long TE images is a function predominantly of the susceptibility effects of intracellular DeoxyHb or intracellular MetHb". Ford et al offer no clue as to how they have concluded that reducing the *PEDD-PRE* contribution to T2 relaxation would reduce the magnitude of the *susceptibility* effect. None of the considerations they have raised have any bearing whatsoever on the susceptibility effect. They have, for reasons known only to them, decided to debate the mechanisms underlying the observed relaxation rates in samples (extracellular DeoxyHb) in which the susceptibility effect is not present. They argue that the PEDD-PRE effect is even smaller than we have indicated. Although, as we have seen, they are wrong on this point, it is not related to the magnitude of the susceptibility effect and cannot form a basis to challenge our conclusion that the susceptibility effect is predominant in determining relaxation rates of acute and subacute hemorrhage.

To summarize the response to Question 2: 1) The protein concentration and PEDD-PRE alone do not explain the relaxation rates observed for suspensions of RBCs containing deoxyhemoglobin. This is one of the major points of our paper (see the quotes cited above). This conclusion flows from our data and we state it clearly throughout the manuscript. In order to explain the hypointensity of acute hematomas, one must invoke inhomogeneous magnitude susceptibility. 2) Ford et al have ignored the data points on Figures 3B and 3C which indicate the magnitude of the inhomogeneity effect. If we were to *reduce* the PEDD-PRE contribution to 1/T2, this would *increase* the inhomogeneity contribution. Thus, no postulated effect of extracellular BSA on T2 PRE could possibly refute our conclusion that inhomogeneity is critical in determining the T2 of these samples. 3) No "correction" is necessary since there is no BSA in the 90% Hct samples.

We believe we have answered the questions raised by Ford and colleagues. However, for the benefit of those who are interested, we have included expanded discussions of the issues they have raised, below.

Question 1: Ford and colleagues question the precision of T2 measurements made with 30 msec interecho time when the T2 values are as short as 17 msec. This illustrates the difference between the goals of measuring T2 changes in which magnetic susceptibility inhomogeneities are considered annoying artifacts and modeling the behavior of in vivo blood in which magnetic susceptibility inhomogeneities are an important factor. If the goal of our study had been to consider T2 changes that occur independent of magnetic susceptibility inhomogeneities, we would have performed these experiments using a minimal interecho time. This is a standard approach that is used to avoid overestimating spin-spin relaxation rates due to spurious dephasing caused by local inhomogeneities. However, clinical MR imaging is not performed using interecho times on the order of 1 msec. Instead, long interecho times are used and the 30 msec interecho times of our study are on the shorter end of the range employed in standard long TR, long TE spin-echo imaging. Under these circumstances, local magnetic susceptibility inhomogeneities may have a profound effect upon the rate at which the signal intensity decays on successive echoes. It is important to distinguish the spin-spin relaxation time measured under ideal, in vitro conditions (which include extremely short interecho times) and the time constant that characterizes the decay of signal intensity on successive echoes, such as observed in MR imaging. The magnitude of the effect of magnetic field susceptibility variations on T2* determinations are well recognized and, in the case of deoxyhemoglobin, have been reviewed by Gomori et al (2). The extent to which inhomogeneity of magnetic susceptibility contributes to signal decay in spin-echo imaging is heavily dependent

upon the interecho time (2). At short interecho times, the magnitude of this inhomogeneity effect is dramatically suppressed as compared to the strength of this effect observed at interecho times that are used in clinical practice. Therefore, had we employed short interecho times, we would have greatly underestimated the rate at which signal intensity would decay if imaging were to be conducted using clinical parameters. Consequently, modelling in vivo imaging requires using long interecho times. Since it was our goal to model in vivo imaging, we had no alternative but to employ long interecho times. This resulted in low signal intensities on our late echo images and reflected successful modeling of hypointense in vivo hemorrhage.

To summarize this point, if one wishes to model the appearance of in vivo hemorrhage, one must acquire the data using pulse sequences that are similar to those employed for clinical imaging. If we routinely obtained images with 1 msec interecho times, then we would have employed 1 msec interecho times for this study.

When obtaining data to test a hypothesis concerning the relationship between Hb concentration and transverse relaxation rate, it is extremely important that the information be acquired in a manner that permits one to determine the nature of this relationship. We chose to obtain single data points at a large number of values of hematocrit rather than to obtain duplicate samples at a small number of points. Dr Ford and his colleagues amply have illustrated the danger of trying to determine the shape of a curve based upon an inadequate number of points (3). They have asserted that, for suspensions of intact red cells containing deoxyhemoglobin, "A purely linear relationship has been shown to exist between hematocrit and the T2 relaxation time of blood, even at 4.7 T" (3). In support of this statement, they cite their work in which they determined 1/T2 values for intact RBCs with an oxygen saturation of 43% at 4.7 T (3). However, as indicated in Figure 1D of their paper, they concluded the relationship was linear *based upon only two data points* representing Hct values of approximately 20% and 70% (4). Since any two points always can be connected by a straight line, the data they cite provides no information at all concerning the linearity of the relationship between Hct and 1/T2. Clearly, Hayman et al would have been better off if they had obtained enough data points (at least three) to form a meaningful opinion about the shape of this curve. We note that no error bars were included in the 1988 *Radiology* paper (4).

Although Hayman, Ford, and colleagues claimed in 1988 that there was a "purely linear relationship" between Hct and relaxation rates (4), they appear to have retracted this claim by 1991 when they stated that "the maximal effect due to T2 proton relaxation enhancement occurs when there are approximately equal volumes of extracellular fluid and RBCs" (5). As they admit in this later paper, this implies that the effect will be maximal at an Hct of approximately 50% (5). Thus the relationship is by no means linear. Interestingly, the observation that the effect is maximal at an Hct ~ 50% was made by Thulborn in 1982 (6). It took Hayman, Ford, et al 7 years to come to the wrong conclusion that "the T2 shortening effect of increasing hematocrit is due purely to concentrating the RBC's" (3). We do not know whether Hayman, Ford, et al consider their "purely linear relationship" between Hct and relaxation rate to be an "old concept" or a "new theory," but we are glad to see them admit that it was wrong (5).

In spite of the confused claim (since retracted, see above) that transverse relaxation is linearly related to Hct for deoxyhemoglobin within intact RBCs, there is an important point to consider: the relaxation rate is linear with Hct for oxyhemoglobin in intact cells (1, 2). Therefore, when measuring 1/T2 as a function of Hct there are two competing effects: 1) Inhomogeneity of magnetic susceptibility (which is maximal at Hct ~ 50%) and 2) a protein concentration effect (which is linear with Hct). To separate these effects, we prepared solutions in which the Hct and hemoglobin concentration varied while the total protein concentration remained unchanged (1). This made it possible to distinguish these two effects. In Figure 2B of our paper, we demonstrate that extracellular oxyhemoglobin has a nearly identical effect on 1/T2 as does BSA (1). Thus, by suspending RBCs in a BSA solution, rather than in protein-free buffer, we are able to identify the extent to which T2 shortening was caused by magnetic susceptibility inhomogeneity, rather than by total protein concentration.

In Figure 3B of our paper, we demonstrate that, in the presence of a constant protein concentration, there is a profound increase in the transverse relaxation rate caused by intracellular deoxyhemoglobin (1). In Figure 3C, the susceptibility effect is separated from the protein and PEDD-PRE effects (1). From this data, it is clear that susceptibility is a more important factor than protein concentration or PEDD-PRE at all Hct values from 10%–90%. Figure 5 presents similar data for methemoglobin (1).

Question 2: Dr Ford and his colleagues challenge the rationale for preparing solutions in which the extracellular protein concentration was equal to that of the intracellular concentration. As is discussed above, previous studies of the relationship between hemoglobin (Hb) oxidation state and 1/T2 have been conducted under conditions in which the total protein concentration varied linearly with the Hb concentration. Therefore, the relaxation rates observed in these studies were influenced by changes in total protein concentration, as well as by PEDD-PRE and susceptibility effects. Since it has been suggested that the hypointensity of acute hematomas observed in vivo and the T2* shortening measured in vitro were due to increasing protein concentration, rather than to the presence of intracellular deoxyhemoglobin, we believed that it was important to perform a study in which we specifically recognized and controlled for the protein concentration effects (1, 3). Hayman, Ford, et al have previously attributed the hypointensity of clinical hematomas to "dramatic concentration" of "proteinaceous clotting factors" during clot retraction with consequent "concentration of plasma protein and . . . tightly packed RBC proteins" within the clot (3). In fact, Hayman, Ford, et al have previously asserted that, in the presence of high protein concentrations present in clots, magnetic susceptibility inhomogeneities cause no detecta-

ble change in T2 relaxation (3). In their letter, Ford et al now claim that the presence of high ("dramatic"?) concentrations of extracellular proteins augment transverse relaxation. Ford et al should make up their minds: either T2 shortening is due entirely to protein concentration and magnetic susceptibility variations caused by deoxyhemoglobin within intact red cells have no effect—as they claimed in 1989—or the presence of high protein concentrations greatly increases the T2 relaxation rate—as they now assert. We stand by our experimental design, methods, results, and interpretations. We hope that by pointing out the dramatic shifts in strongly stated positions by Ford et al—relaxation is/is not linear with Hct, magnetic susceptibility variations are insignificant/very important in the presence of high protein concentrations—we have made clear the source of confusion on these issues.

Furthermore, the citations included by Ford et al to support their second question are presented in a manner that is at best misleading. The Finch reference, cited by Ford et al, does not support the claims made by Ford et al (7). This reference is an abstract that includes essentially no discussion of experimental methods. In this abstract, it is reported that pure water at 0°C has a far higher self-diffusion coefficient than does water ice at 0°C. It is also reported that self-diffusion coefficients were measured in red blood cells and in frog muscles. Again, there are no details describing experimental methods. It is reported that the self-diffusion coefficient is 50%–80% (not 70% as Ford et al have stated) lower under these conditions than in pure water (7). The authors do not indicate whether these self-diffusion coefficient values apply to red cells, muscle, or both (7). The Finch abstract makes no statement whatsoever concerning the influence of protein concentration upon self-diffusion coefficients. It certainly does not compare the diffusion coefficients of water measured at a protein concentration of 6 g/dL to the diffusion coefficient measured at a concentration of 37 g/dL, as Ford et al have suggested. In fact, the word "protein" does not appear in reference 2.

The Abetsekarskaya reference, cited by Ford et al, does not contain the statements the authors have attributed to it (8). This paper reports experiments and citations from the literature indicating that an addition of protein to water reduces the self-diffusion coefficient of water. However, the protein concentration range reported in this paper is far narrower than the 6–37 g/dL range to which Ford et al refer. The report contains a table (Table 1) in which the self-diffusion coefficient of water is related to the concentration of protein in solution. These authors report that they measured the diffusion coefficients of water in a 9% (weight %) solution of egg albumin and in a 20% solution BSA. By more than doubling the protein concentration, the authors measured a change in self-diffusion coefficient which was considerably less than their 12% standard deviation (8). In another table (Table 2) the authors cite work, published elsewhere, which suggested that an increase in the BSA concentration from 10.6 to 19 g/dL caused a 21% decline in the self-diffusion coefficient (8). Again, this paper does not support the contention of Ford et al that a change in protein concentration from 6–8 to 37 g/dL will produce a decrease in the self-diffusion coefficient of 50%–70%.

We point out that the references discussed above do not contain the statements attributed to them since this is the only meaningful statement one can make about these references that pertains to Ford et al's contentions. Since their purpose in discussing the self-diffusion coefficient is to assert that reductions in the self-diffusion coefficient of water augment T2 PRE, and invalidate our results, the fact that the references cited by Ford et al do not contain the statements attributed to them acquires considerable significance. This pattern of erroneous citations continues in the Luz and Meiboom article.

The paper by Luz and Meiboom contains no statements that even vaguely resemble those attributed to it by Ford et al (9). Ford and colleagues contend that this reference reports a threefold increase in T2 PRE associated with a 50%–70% reduction in self-diffusion coefficient. Unfortunately, reference 4 does not discuss T2 PRE or diffusion coefficients at all. Reference 4 concerns the number of water molecules involved in the trimethylamine-trimethylammonium reaction. In this paper, the authors study the residence time of protons on water molecules and on the ammonium ion. In order to do this, the authors prepared solutions of trimethylamine-trimethylammonium ranging in concentration from .03–1.0 M. T2 values were determined using a modified Carr-Purcell sequence and observed T2 values were extrapolated back to a pulse rate of 0. By comparing these changes in T2 associated with trimethylammonium concentration using natural abundance O^{17} water to the T2 values of obtained O^{17}-enriched water, the authors were able to measure the proton water-water exchange rate and to calculate the number of water molecules involved in the trimethylamine-trimethylammonium reaction. The analysis employed in this paper has been extended to other situations in which T2 relaxation rates and diffusion coefficients must be considered and we assume that this is the reason that Ford et al have cited it. However, in order to calculate the magnitude of T2 change associated with a postulated change in water diffusion coefficient in a protein solution surrounding intact RBCs containing deoxyhemoglobin or methemoglobin, one must make many other assumptions which Ford et al do not describe. Therefore, although it would be possible to arrive at the values reported by Ford et al through judicious choices of initial conditions, this reference hardly provides a specific indication of the extent to which a reduction in the self-diffusion coefficient of water would be expected to increase the T2 relaxation rate in our samples, or in vivo.

In short, Ford et al have made a number of claims that are wholly unsupported by the references they cite. As we have indicated above, the exercise of "correcting" the T2 value for the 90% Hct sample for the presence of extracellular BSA is not called for since there is no BSA in this sample. If Ford et al were correct in their assertion that the T2 PEDD-PRE values in this study would be considerably lower in the absence of extracellular BSA, then the 90% Hct sample should display a dramatically lower 1/T2 contribution by Protein+ PEDD-PRE than would be predicted

by our model. However, inspection of our Figures 3B and 3C and 5B and 5C reveals an excellent agreement between the model and the data. There is no evidence of a dramatic change in conditions between the 90% Hct and the other data points. This supports our contention that it is the total protein concentration, not the presence of extracellular BSA, that, in combination with PEDD-PRE and heterogeneous magnetic susceptibility, determines the relaxation rate in samples containing intracellular DeoxyHb or intracellular MetHb.

David B. Hackney
Peter A. Janick
Robert I. Grossman
Department of Radiology
Hospital of the University of Pennsylvania
Philadelphia, PA 19104

References

1. Janick P, Hackney D, Grossman R, Asakura T. MR imaging of various oxidation states of intracellular and extracellular hemoglobin. *AJNR* 1991;12:891–897
2. Gomori J, Grossman R, Yu-Ip C, Asakura T. NMR relaxation times of blood: dependence of field strength, oxidation state and cell integrity. *J Comput Assist Tomogr* 1987;11:684–690
3. Hayman L,. Taber K, Ford J, et al. Effect of clot formation and retraction on spin-echo MR images of blood: an in vivo study *AJNR* 1989;10:1155–1158
4. Hayman L, Ford J, Taber K, Saleem A, Round ME, Bryan R. T2 effect of hemoglobin concentration: assessment with in vitro MR spectroscopy. *Radiology* 1988;168:489–491
5. Hayman L, Taber K, Ford J, Bryan R. Mechanisms of MR signal alterations by acute intracerebral blood: old concepts and new theories. *AJNR* 1991;12:899–907
6. Thulborn K, Waterton J, Matthews P, Radda G. Oxygenation dependence of the transverse relaxation time of water protons in whole blood at high field. *Biochim Biophys Acta* 1982;714:265–270
7. Finch E, Harmon J. Diffusion of water in muscle and blood as measured with pulsed nuclear magnetic resonance. *Cryobiology* 1971;8:379
8. Abetsedarskaya L, Miftakhutdinova F, Fedotov V. State of water in live tissues (results of investigations by the NMF-Spin echo method). *Biophysics* 1968;13:750–758
9. Luz Z, Meiboom S. Nuclear magnetic resonance study of the protolysis of trimethylammonium ion in aqueous solution: order of the reaction with respect to solvent. *J Chem Phys* 1963;39:366–370