

Are your **MRI contrast agents** cost-effective?

Learn more about generic **Gadolinium-Based Contrast Agents**.



FRESENIUS
KABI

caring for life

AJNR

Internal carotid artery occlusion due to idiopathic cranial pachymeningitis.

S J Willing and W Broghamer

AJNR Am J Neuroradiol 1992, 13 (6) 1594-1596

<http://www.ajnr.org/content/13/6/1594>

This information is current as
of April 17, 2024.

Internal Carotid Artery Occlusion Due to Idiopathic Cranial Pachymeningitis

Steven J. Willing^{1,2} and Walter Broghamer³

Summary: A 35-year-old black woman had a 6-month history of headaches and a 1-month history of abducens nerve palsy. MR showed a mass in the sella and cavernous sinuses with encasement of the carotid artery. The mass enhanced intensely and homogeneously with Gd-DTPA. Arteriography revealed complete occlusion of the left internal carotid artery and severe stenosis of the C5 and C6 segments of the right internal carotid artery. Transsphenoidal biopsy of the mass led to the diagnosis of idiopathic cranial pachymeningitis.

Index terms: Arteries, carotid (internal); Arteries, stenosis and occlusion; Pachymeningitis

Idiopathic cranial pachymeningitis is a rare disease characterized by thickening of the dura and cranial neuropathies. Its computed tomographic (CT) and unenhanced magnetic resonance (MR) findings have been recently described (1). We report the contrast-enhanced MR and angiographic findings in a case of complete internal carotid artery (ICA) occlusion caused by idiopathic cranial pachymeningitis.

Case Report

A 35-year-old black woman presented with a 6-month history of unremitting headache and a 1-month history of a right abducens nerve palsy. Cranial CT showed an enhancing parasellar mass. Laboratory studies revealed an elevated sedimentation rate of 45 and a mildly elevated antinuclear antibody titer (1:40, speckled). Rheumatoid factor was negative. Serum thyroxine, thyrotropin, follicle-stimulating hormone, and luteinizing hormone all were within normal limits. MR (short TR/short TE) demonstrated a hypointense enhancing mass of the sella with probable invasion of both cavernous sinuses. The internal carotid signal void was undetectable on the left and incompletely seen on the right (Fig. 1). On long TR/long TE images the mass was slightly hypointense relative to brain and there

were small hyperintensities in the left deep white matter consistent with chronic ischemic change. Angiography confirmed complete occlusion of the left ICA and severe stenosis of the cavernous and supraclinoid segments of the right ICA (Fig. 2). No tumor vascularity or blush was present.

Transsphenoidal exploration of the pituitary fossa revealed only a mass of fibrous tissue. Biopsies showed dense, hypercellular collagen with focal fibroplasia and scattered inflammatory cells, consistent with a diagnosis of idiopathic cranial pachymeningitis.

Postoperatively, her sixth nerve palsy abated following steroid therapy. The patient was subsequently lost to follow-up.

Discussion

Pachymeningitis has been associated with a wide range of etiologies which are summarized in Table 1. Considering all possible causes, it is not a rare occurrence. A review of the world literature for the period 1985–90 identified 24 cases. The commoner etiologies include dural carcinomatosis and rheumatoid disease. Earlier reports emphasized an association with syphilis, now rarely seen in its later stages. Idiopathic or primary cranial pachymeningitis appears to be both a rare entity and a diagnosis of exclusion. Martin et al in 1989 reported the imaging findings in three patients and cited only four previously reported cases (1). Another report from the same year describes the CT findings in what appears to be the same three patients (2). Idiopathic spinal pachymeningitis is a separate and distinct entity with a more fulminant course and generally does not involve the dura above the foramen magnum (3).

Cranial pachymeningitis, regardless of etiology,

Received September 4, 1991; revision requested October 22; revision received February 4, 1992 and accepted February 10.

Presented at the 29th Annual Meeting of American Society of Neuroradiology, Washington, DC, June 1991.

¹ Department of Diagnostic Radiology, University of Louisville, Louisville, KY 40292.

² Address reprint requests to Steven J. Willing, MD, at present address: Department of Diagnostic Radiology, University of Alabama at Birmingham, 619 S. 19th St., Birmingham, AL 34233.

³ Department of Pathology, University of Louisville, Louisville, KY 40292.

AJNR 13:1594–1596, Nov/Dec 1992 0195-6108/92/1306-1594 © American Society of Neuroradiology

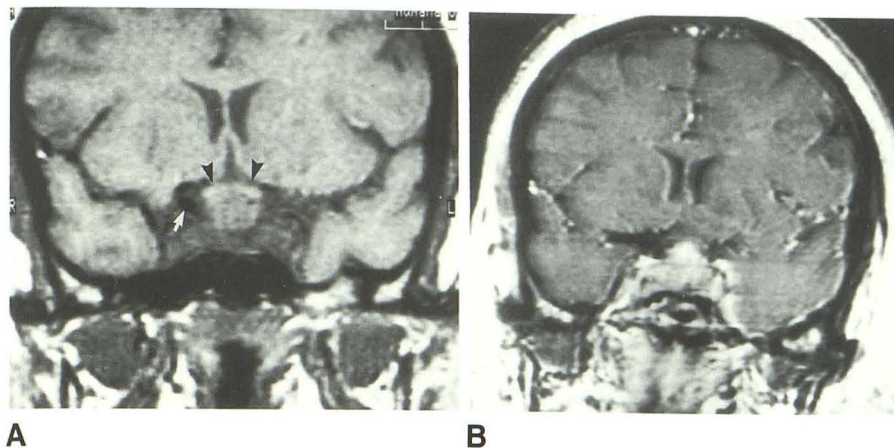


Fig. 1. A, Coronal spin-echo MR 676/20/4 (TR/TE/excitations). The left internal carotid flow void cannot be seen and only the supraclinoid segment of the right ICA is visible (arrow). The normal sellar and cavernous sinus anatomy is replaced by a heterogeneously hypointense mass causing upward displacement of the optic chiasm (arrowheads).

B, Spin-echo MR 990/30/4 following intravenous Gd-DTPA. There is intense enhancement of a mass involving the sella, cavernous sinuses, and suprasellar cistern.

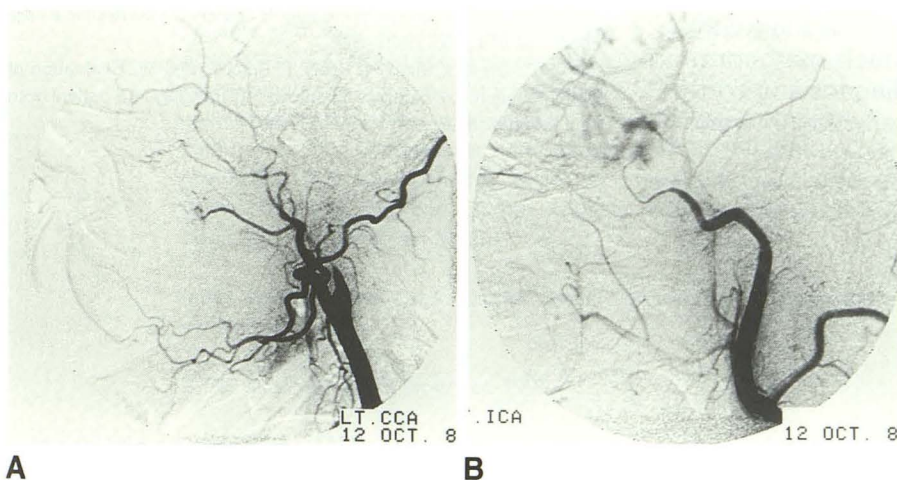


Fig. 2. A, Left common carotid angiogram shows total occlusion of the left ICA.

B, Right common carotid angiogram shows severe stenosis of the cavernous and supraclinoid segments of the right internal carotid. The M1 and A1 segments of the respective vessels were of normal caliber.

TABLE 1: Etiology of pachymeningitis

| |
|---|
| Rheumatoid arthritis |
| Idiopathic spinal pachymeningitis |
| <i>Mycobacterium tuberculosis</i> |
| <i>Pseudallescheria boydii</i> |
| Multifocal fibrosclerosis |
| Idiopathic cranial pachymeningitis |
| Otorhinisinitis |
| Wegener granulomatosis |
| Syphilis |
| Dural carcinomatosis (pachymeningitis hemorrhagica) |
| Fungal infections |
| Sarcoid |
| Cysticercosis |

usually presents with headaches, nausea, and cranial nerve deficits, particularly of the optic nerve. The neural deficits may result from compression of the nerves or impairment of their blood supply. Vascular compromise has been suggested as the cause of cord dysfunction in the spinal form (4). In the idiopathic cranial form, reported cases have ranged from 20 to 60 years old. The erythrocyte sedimentation rate was ele-

vated in all seven reported cases as well as our own (1).

In all three cases reported by Martin, the disease involved the tentorium and, at angiography, they found dural sinus narrowing or occlusion. CT revealed a thickened and enhancing dura, especially at the tentorium. T2-weighted MR in one patient showed a thickened hypointense tentorium with a hyperintense rim. On T1-weighted images, the dura was slightly hypointense relative to gray matter (1). Intense enhancement after gadolinium was seen in our case, and has been described in other forms of pachymeningitis (3-5).

Pachymeningitis is a cause of carotid occlusion. In our patient, proliferative fibrosis of the dura forming the cavernous sinuses and diaphragma sella produced severe narrowing of one internal carotid and occlusion of the other. Due to the intense enhancement, the preoperative diagnosis was meningioma. Meningiomas are the intracranial neoplasm most often associated with carotid narrowing or occlusion, and a small mi-

nority are hypovascular. However, it would be unusual for a meningioma to affect both cavernous sinuses. Pituitary adenomas often invade both cavernous sinuses and have been shown to cause carotid occlusion. However, the latter is a rare occurrence and our patient had normal pituitary function. Sarcoidosis was seriously considered since a few reported cases have manifested predominantly dural involvement, but serum angiotensin converting enzyme was negative and there were no granulomas in the biopsy specimen.

Idiopathic cranial pachymeningitis is a rare disorder characterized by headaches, nausea, cranial nerve deficits, and an elevated sedimentation rate. On imaging studies one sees a markedly thickened and enhancing dura which may compromise the dural sinuses. The diagnosis is confirmed by biopsy and exclusion of other menin-

geal processes. Our case illustrates that the carotid artery may be compromised where it is in close proximity to the dura. Pachymeningitis should be considered when a dural mass and major arterial narrowing coexist.

References

1. Martin N, Masson C, Henin D, Mompoin D, Marsault C, Nahum H. Hypertrophic cranial pachymeningitis: assessment with CT and MR imaging. *AJNR* 1989;10:477-484
2. Masson C, Henin D, Decroix J, Martin N, Cambier J, Masson M. Pachymeningitis craniennes des cause indeterminee: etude de 3 cas. *Rev Neurol* 1989;145:16-23
3. Digman K, Partington C, Graves V. MR imaging of spinal pachymeningitis. *J Comput Assist Tomogr* 1990;14:988-990.
4. Callebaut J, Dormont D, Chiras J, Bories J. Contrast-enhanced MR imaging of tuberculous pachymeningitis cranialis hypertrophica: case report. *AJNR* 1990;11:821-822
5. Yuh WTC, Drew J, Rizzo M, Ryals T, Sato Y, Bell W. Evaluation of pachymeningitis by contrast-enhanced MR imaging in a patient with rheumatoid disease. *AJNR* 1990;11:1247-1248